

# Do Effective Canal Diameter and Atlantodental Interval have a Role in the Assessment of Postoperative Early Clinical and Radiological Status in Craniovertebral Junction Disorders?

Satyajit Rabha<sup>1</sup>, Andi S Ramesh<sup>2</sup>, Vadivel RR Kumar<sup>3</sup>, Rajalakshmi Rajasegaran<sup>4</sup>

## ABSTRACT

**Introduction:** Surgery at the level of the craniovertebral junction (CVJ) is complex and technically challenging due to the presence of vital anatomical structures and complex congenital anomalies. The type of surgical procedure depends on the primary pathology. However, the aim of these surgical procedures is to relieve the compression at the level of the medulla and achieve anatomical stabilization.

**Objective:** The objective of this study was to assess the early postoperative clinical and radiological outcome following stabilization of the CVJ in patients with atlantoaxial dislocation (AAD).

**Materials and methods:** It is a retrospective descriptive study. All consecutively operated patients of AAD having complete clinical and radiological medical records in the institute were included in this study. Patients who had undergone transoral odontoidectomy were excluded. Atlantodental interval more than 3 mm in adults and 5 mm in children was considered as AAD. Three parameters were studied: Nurick grade, atlantodental interval (ADI), and effective canal diameter (ECD) at the level of C1. Clinical and radiological improvement was assessed by the Wilcoxon signed-rank sum test and the paired *t* test, respectively. A correlation among the duration of symptoms, Nurick grade, and changes in ECD and ADI was assessed by the Pearson correlation coefficient test.

**Results:** Twenty-five patients who had complete clinical and radiological records were included in this study. There was no significant neurological improvement in the immediate (within 7 days) postoperative period. However, statistically significant improvement was observed in ECD and ADI. There was no significant correlation among the duration of symptoms, Nurick grade, and changes in ECD and ADI.

**Conclusion:** ECD and ADI may serve as useful parameters to assess the radiological improvement in the early postoperative period of patients with AAD.

**Keywords:** Atlantoaxial dislocation, Compressive myelopathy, Neck pain, Nurick grade.

*The Journal of Spinal Surgery* (2019): 10.5005/jp-journals-10039-1209

## INTRODUCTION

A neurosurgeon who encounters a patient with atlantoaxial joint instability faces many dilemmas. One of them is for the most appropriate surgical technique to be employed for a particular patient. Due to the anatomical complexity, surgical methods used in the cases of atlantoaxial joint dislocations are not uniform.<sup>1-4</sup> The primary goal in all these surgical procedures is to relieve the compression at the level of the medulla and to achieve the normal anatomical alignment at C1 and C2.<sup>4</sup> Even with modern advancement in surgical techniques, surgery around atlantoaxial joint remains challenging due to the adjacent medulla and vertebral arteries.<sup>4,5</sup>

Previous studies on the craniovertebral junction (CVJ) disorders have reported the long-term neurological outcome of individual surgical stabilization techniques.<sup>6-11</sup> In this study, we aimed to assess the early (within 7 days) neurological and radiological improvements following the stabilization of the CVJ in the patients with atlantoaxial dislocation (AAD).

## MATERIALS AND METHODS

In this retrospective descriptive study, data of patients operated between January 2010 and September 2015 in the Department of Neurosurgery, Jawaharlal Institute of Postgraduate Medical Education and Research (JIPMER), Puducherry, were included. The study was earlier reviewed and approved by the Institute Research and Ethical Committee (Project No. JIP/IEC/2015/19/702).

<sup>1</sup>Department of Neurosurgery, Jorhat Medical College, Jorhat, Assam, India

<sup>2</sup>Department of Neurosurgery, Jawaharlal Institute of Postgraduate Medical Education and Research, Puducherry, India

<sup>3</sup>Department of Neurosurgery, Apollo Proton Cancer Centre, Tharamani, Chennai, Tamil Nadu, India

<sup>4</sup>Department of Physiology, Jawaharlal Institute of Postgraduate Medical Education and Research, Puducherry, India

**Corresponding Author:** Andi S Ramesh, Department of Neurosurgery, Jawaharlal Institute of Postgraduate Medical Education and Research, Puducherry, India, Phone: +91 9677601426, e-mail: asrameshms@gmail.com

**How to cite this article:** Rabha S, Ramesh AS, *et al.* Do Effective Canal Diameter and Atlantodental Interval have a Role in the Assessment of Postoperative Early Clinical and Radiological Status in Craniovertebral Junction Disorders? *J Spinal Surg* 2019;6(2):35-39.

**Source of support:** Nil

**Conflict of interest:** None

## Inclusion Criteria

Atlantodental interval (ADI) exceeding 3 mm in adults and 5 mm in children was considered as AAD.<sup>5</sup> All consecutively operated patients of AAD with an upper age limit of 65 years having complete clinical and radiological medical records were included.

**Exclusion Criteria**

Patients who had undergone transoral odontoidectomy were excluded from the study.

**Brief Procedure**

Clinical and radiological data were collected from the department medical records. The parameters that were included in the study were the Nurick grade, ADI, and effective canal diameter (ECD) at the level of C1.<sup>12,13</sup> Nurick grading was recorded from the preoperative clinical notes. Postoperative Nurick grading was recorded from the discharge summary or clinical notes just before the discharge.

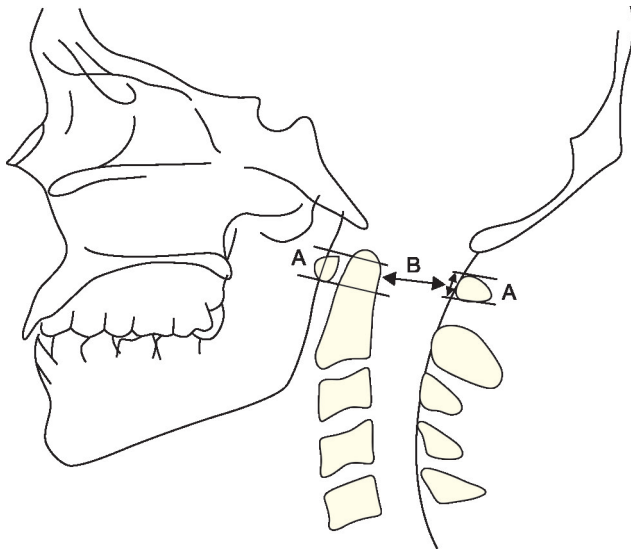
The cervical spine spiral computerized tomography (CT) scan was routinely done with 1 mm thick sections. Reconstructed images in sagittal and coronal planes were obtained from 1 mm axial sections. ADI and ECD were measured at the level of the atlas from pre and postoperative images of cervical spine CT in the midsagittal plane.

ADI was measured by drawing a line from the posterior aspect of the anterior arch of atlas (C1) to the most anterior aspect of the dens at the midpoint of the thickness of the arch in the craniocaudal dimension. ECD was measured by drawing a line from the posterior aspect of dens to the anterior border of the posterior arch of the atlas (C1) at the midpoint of the thickness of the arch in the craniocaudal dimension. In case the posterior arch was removed, a line drawn along the spinolaminar line was taken to measure the posterior border (Fig. 1). AAD was considered reducible with the alignment of C1–C2 on extension or traction.

Data on the following variables were also collected: age, sex, occupation, principal neurological signs and symptoms, duration of symptoms, radiological findings, type of surgical technique employed, postoperative complications, and postoperative neurological status. No follow-up data were recorded after the discharge from the hospital.

**Statistical Analysis**

Descriptive and inferential statistics were used for the data analysis. All the statistical analyses were carried out at a 5%



**Fig. 1:** Schematic representation of ECD. A line (B) drawn from the posterior aspect of dens to the anterior border of posterior arch of atlas will represent the ECD at the level of C1. In case the posterior arch was removed, a line drawn along spinolaminar line was taken to measure the posterior border

level of significance. The paired *t* test was used for assessing the statistical significance of the improvement in ECD and ADI, and the Wilcoxon signed-rank sum test was used for assessing the clinical improvement. The Pearson correlation coefficient test was used to assess the extent of the correlation among the duration of symptoms and changes in the Nurick grade, ECD, and ADI. The statistical software namely Statistical Analysis System (SAS) 9.2, Statistical Package for Social Sciences (SPSS) 15.0, Stata 10.1, MedCalc 9.0.1, Systat 12.0, and R environment ver.2.11.1 were used for the analysis of the data.

**RESULTS**

A total of 46 patients who were operated for AAD between 2010 and 2015 were identified from the records. Out of these 46 patients, 21 patients were excluded due to incomplete records, age older than 65 years, or who had undergone transoral odontoidectomy. Twenty-five patients who had complete clinical and radiological records were included in this study.

The average age of the patients was 30.2 years with a range from 4 to 57 years. Males outnumbered females (21 vs 4) (Table 1).

Trauma (odontoid fractures and C1–C2 subluxation) was the predominant (68%) cause of AAD followed by congenital malformations—24% (basilar invagination, Os odontoides, and Down syndrome), 4% rheumatoid arthritis, and 4% tuberculosis (Table 1).

Twenty-two patients (88%) were presented with myelopathy, whereas three patients (12%) were presented with chronic neck pain. The mean duration of symptoms before surgery was 284.2 days. Most of the patients had a slowly progressive disease course while one patient exhibited acute deterioration and respiratory compromise. This patient was treated with ventilator support and respiratory physiotherapy and was operated later after an improvement in his general condition.

Out of the total number of 25 cases, 18 patients (72%) had reducible AAD and 7 patients (28%) had irreducible AAD in dynamic CVJ X-rays. Among the seven patients who had irreducible AAD, the application of Gardner–Wells traction up to 10% of body weight helped to reduce the AAD only in three patients (Table 1).

**Surgical Procedure**

Eleven patients underwent C1 lateral mass—C2 pars/pedicle/laminar screw fusion, seven underwent occipitocervical fusion, four underwent unilateral C1–C2 transarticular screw fixation with the wiring of C1–C2, and three underwent bilateral C1–C2 transarticular screw fixation (Table 2).

**Table 1:** Distribution of cases with AAD based on gender, etiology, and reducibility

Variables	Category	Frequency	Percentage
Gender	Male	21	84
	Female	4	16
Etiology	Traumatic	17	68
	Congenital	6	24
	Rheumatoid	1	4
	Tuberculosis (TB) spine	1	4
Reducibility	Reducible	18	72
	Irreducible	7	28

**Table 2:** Types of surgical procedures

S. no.	Procedure	No. of cases
1	C1 lateral mass–C2 pars/pedicle/laminar screw fusion	11
2	C1–C2 bilateral transarticular screw fixation	3
3	C1–C2 unilateral transarticular screw fixation with wiring of C1–C2	4
4	Occipitocervical fusion	7
	Total	25

**Neurological Status**

Although there was no change in the postoperative Nurick grade for 19 patients (76%), a statistically nonsignificant improvement was noted in the neurological status of 4 patients (16%). Two patients expired in the postoperative period and hence their postoperative neurological status could not be assessed (Table 3).

**ECD**

The mean preoperative ECD was 10.65 mm and the postoperative ECD was 13.12 mm. Statistically significant improvement in terms of an increase in the postoperative ECD was observed in 21 patients (84%) (Table 4). Among these 21 patients, 3 patients showed neurological improvement in the early postoperative period and the rest of the 18 patients had stable neurological status.

Among the 19 patients who showed no change in their Nurick grade in the early postoperative period, their ECD was seen to have significantly improved on an average from 10.80 to 13.18 mm after the surgery (Table 5).

**Table 3:** Clinical improvement—change in the Nurick grade

Preoperative Nurick grade n = 25	Postoperative Nurick grade n = 25	Change in Nurick grade* n = 25
2 (1–4)	2 (1–4)	p value = 0.059

Values are median (range); \*Wilcoxon signed-rank sum test

**Table 4:** Radiological change in ECD

Preoperative ECD (mm) n = 25	Postoperative ECD (mm) n = 25	Improvement in ECD (mm) n = 25	p value
10.65 ± 4.28	13.12 ± 2.93	2.46 ± 3.23 <sup>†</sup>	<0.001

ECD, effective canal diameter; values are mean ± SD; <sup>†</sup>paired t-test—p value < 0.001

**Table 5:** ECD changes in patients with no improvement in neurological status

Preoperative ECD (mm) n = 19	Postoperative ECD (mm) n = 19	Improvement in ECD (mm) n = 19
10.80 ± 4.56	13.18 ± 3.26	2.38 ± 2.95 <sup>‡</sup>

ECD, effective canal diameter; values are mean ± SD; <sup>‡</sup>paired t test—p value < 0.001

**Table 6:** Radiological change in ADI

Preoperative ADI (mm) n = 25	Postoperative ADI (mm) n = 25	Improvement in ADI (mm) n = 25
5.31 ± 3.21	3.7 ± 2.46	p < 0.001 <sup>§</sup>

ADI, atlantodental interval; values are mean ± SD; <sup>§</sup>paired t test—p value < 0.001

**ADI**

The mean preoperative ADI was 5.31 mm and the postoperative ADI was 3.7 mm. Statistically significant improvement in terms of a decrease in the postoperative ADI was observed in 17 patients (68%) (Table 6). Among these 17 patients, 2 patients showed neurological improvement in the early postoperative period and 14 patients had stable neurological status. One patient expired due to postoperative infection.

Among the 19 patients who showed no change in their Nurick grade in the early postoperative period (within 7 days), their ADI was seen to have significantly reduced on an average from 5.84 to 3.95 mm after the surgery (Table 7).

There was no significant correlation among the duration of symptoms, preoperative Nurick grade, and ECD. Similarly, there was no significant correlation among postoperative Nurick grade, ECD, and ADI. However, a significant positive correlation was observed between the duration of symptoms and preoperative ADI (Table 8).

**DISCUSSION**

Treatment for symptomatic or asymptomatic AAD is surgical fixation.<sup>14</sup> There are numerous surgical techniques to achieve anatomical reduction and proper surgical alignment in CVJ disorders. The technique may depend on the type of pathology, the treating physician, and the resources available in the respective treating institution.<sup>15</sup> The most important aspect of the surgical treatment for patients with AAD complicated with the neurological deficit is to secure a sufficient sagittal spinal canal diameter and stability.<sup>5,16</sup>

The final clinical outcome in AAD fixation depends on various radiological parameters like clivus canal angle, Chamberlain’s line, Mac Rae’s line, ADI, effective sagittal diameter, and space available for the spinal cord in pre and postoperative spinal imaging.<sup>17,18</sup>

With respect to spine pathologies, spinal CT helps assess the bony anatomy, type of surgical procedure and immediate postoperative implant position, and surgical alignment.<sup>19,20</sup> In

**Table 7:** ADI changes in patients with no improvement in neurological status

Preoperative ADI (mm) n = 19	Postoperative ADI (mm) n = 19	Improvement in ADI (mm) n = 19
5.84 ± 3.29	3.95 ± 2.67	1.89 ± 2.21*

ADI, atlantodental interval; values are mean ± SD; \*paired t test—p value < 0.05

**Table 8:** Pearson correlation among the duration of symptoms, preoperative Nurick grade, preoperative ECD, preoperative ADI, postoperative Nurick grade, postoperative ECD, and postoperative ADI (p value)

Parameters	Pearson correlation coefficient (p value)
Duration of symptoms and preoperative Nurick grade	0.097 (0.644)
Duration of symptoms and preoperative ECD	–0.125 (0.550)
Duration of symptoms and preoperative ADI	0.424 (0.035) <sup>#</sup>
Duration of symptoms and postoperative Nurick grade	–0.141 (0.522)
Nurick grade changes and postoperative ECD	–0.163 (0.458)
Nurick grade changes and postoperative ADI	–0.203 (0.352)

<sup>#</sup>p value < 0.05. ECD, effective canal diameter; ADI, atlantodental interval

**Table 9:** Previous studies on canal diameter at the CVJ

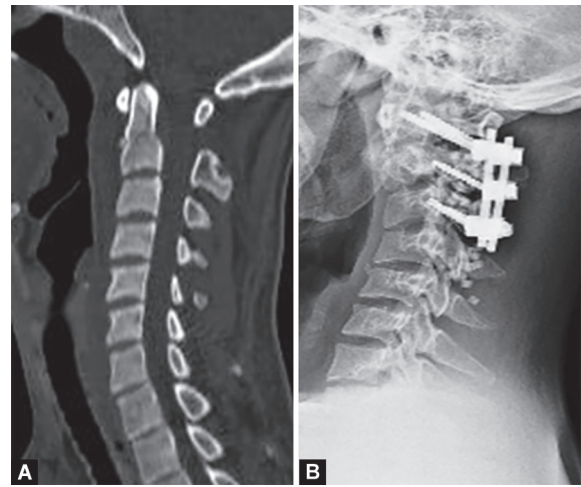
S. no.	Study	Parameter	No. of cases
1	Oda et al. <sup>18</sup>	Space available for the spinal cord (SAC) at C1 in rheumatoid arthritis with and without myelopathy	239
2	Matveeva et al. <sup>20</sup>	Morphometric analysis of the cervical spinal canal on MRI	50
3	Sardhara et al. <sup>21</sup>	Effective canal diameter in syndromic vs nonsyndromic atlantoaxial dislocation	46
4	Mehrotra et al. <sup>22</sup>	Effective canal diameter in bony craniovertebral anomalies	67
5	Present study	Effective canal diameter (ECD), atlantodental interval (ADI) in atlantoaxial dislocation	25

this study, ECD and ADI were chosen to assess the immediate postoperative radiological parameters from spinal CT images. Among the two parameters, ECD is more important as it provides indirect evidence of the space available for the spinal cord.<sup>21,22</sup>

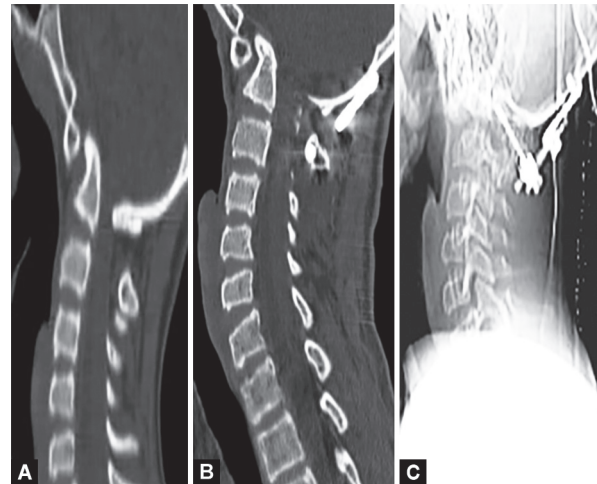
There is relative paucity of the literature for ECD at the level of C1 in AAD (Table 9). We found a mention of ECD in a study done by Sardhara et al. on congenital AAD<sup>21</sup> and another study by Mehrotra et al. on bony CVJ anomalies.<sup>22</sup>

In this study, majority of the patients with AAD were between 28 years and 44 years with male predominance. Trauma was the leading antecedent history before the onset of symptoms. Most of the patients were presented with slowly progressive disease and myelopathy. Patients who had an irreducible AAD on preoperative dynamic CVJ lateral view X-rays were put on cervical traction before declaring it as irreducible. All cases were operated using a posterior approach using C1 lateral mass–C2 pars/pedicle/laminar screw fusion, C1–C2 transarticular screw fixation with or without wiring of C1–C2, and occipitocervical fusion (Figs 2 to 4).

Among the 25 patients included in the study, statistically nonsignificant improvement in the postoperative neurological status in terms of the Nurick grade was noted only in four patients. This could be attributed to their young age, short duration of symptoms, early



**Figs 3A and B:** Pre- (A) and postoperative (B) radiological images of cases with AAD of traumatic origin



**Figs 4A to C:** Pre- (A) and postoperative (B and C) radiological images of a case with AAD of congenital origin

referral to neurosurgical care following trauma, and the type of surgical procedure performed (C1–C2 transarticular screw with sublaminar wiring—three patients and occipitocervical fusion—one patient). The mean duration of symptoms in the patients with neurological improvement was much shorter (139 days) when compared with the patients with no neurological improvement in the early postoperative period (300 days). Among the four patients with neurological improvement, three patients showed an increase in the postoperative ECD and one showed reduction in ADI in spine CT scan.

There was no change in the postoperative Nurick grade for 19 patients. However, a significant increase in the postoperative ECD and a decrease in ADI were observed in these patients. The patients with chronic compressive myelopathy generally require a relatively longer time for neurological improvement after surgical stabilization.<sup>23</sup> The non-improvement in the neurological grade of 19 patients in this study could be due to the assessment of their Nurick grade in the early postoperative period. Hence, a long-term follow-up of the patients with CVJ disorders is recommended to comment on the Nurick grade changes.

The non-improvement in postoperative ECD in four patients could be due to the type of pathology like rheumatoid arthritis, Down syndrome, and complex C2 fractures.

**Figs 2A to C:** Pre- (A) and postoperative (B and C) radiological images of cases with AAD of traumatic origin

In this study, a significant positive correlation was observed between the duration of symptoms and preoperative ADI. Hence, it may be inferred that if the treatment for CVJ disorders is delayed, it would result in a progressive increase in ADI which, in turn, would worsen the neurological prognosis of the patient.

In this study, three (12%) patients had complications related to surgery. Two patients expired postoperatively. The first case was a child with Down syndrome who suffered dural injury and postoperative cerebrospinal fluid (CSF) leak leading to meningitis. The second patient was an adult who had dominant right vertebral artery injury and thrombosis with a bilateral cerebellar infarct. The effort taken for endovascular thrombolysis was unsuccessful. Similar findings have also been reported in a study by Wang et al.<sup>4</sup>

Another patient had postoperative surgical wound necrosis and dehiscence. It was resolved with wound reexploration and debridement of the operative site with islanded right sided trapezius musculocutaneous flap reconstruction. No incidence of instrumentation failures or revisions was required for the same.

Small sample size and short-term postoperative follow-up of patients are the limitations of this study. Future studies with a larger sample size and long-term follow-up may be helpful to substantiate the results of the study.

## CONCLUSION

ECD and ADI may serve as useful parameters to assess the radiological improvement in the early postoperative period of the patients with AAD. Patients with CVJ disorders may not show significant improvement in early postoperative Nurick grade, but significant postoperative improvements in ECD and ADI in these patients may indicate stable neurological status. However, a study with a larger sample size and long-term follow-up is required to substantiate the results of the study.

## REFERENCES

- Klimo Jr P, Rao G, et al. Congenital anomalies of the cervical spine. *Neurosurg Clin N Am* 2007;18(3):463–478. DOI: 10.1016/j.nec.2007.04.005.
- Wasserman BR, Moskovich R, et al. Rheumatoid arthritis of the cervical spine—clinical considerations. *Bull NYU Hosp Jt Dis* 2011;69(2):136–148.
- Dvorak J, Schneider E, et al. Biomechanics of the craniocervical region: the alar and transverse ligaments. *J Orthop Res* 1988;6(3):452–461. DOI: 10.1002/jor.1100060317.
- Wang S, Wang C, et al. Novel surgical classification and treatment strategy for atlantoaxial dislocations. *Spine (Phila Pa 1976)* 2013;38(21):E1348–1356. DOI: 10.1097/BRS.0b013e3182a1e5e4.
- Yang SY, Boniello AJ, et al. A review of the diagnosis and treatment of atlantoaxial dislocations. *Global Spine J* 2014;4(3):197–210. DOI: 10.1055/s-0034-1376371.
- Di Lorenzo N, Fortuna A, et al. Craniovertebral junction malformations. Clinicoradiological findings, long-term results, and surgical indications in 63 cases. *J Neurosurg* 1982;57(5):603–608. DOI: 10.3171/jns.1982.57.5.0603.
- Sumi M, Kataoka O, et al. Atlantoaxial dislocation. A follow-up study of surgical results. *Spine (Phila Pa 1976)* 1997;22(7):759–763.
- Arunkumar MJ, Rajshekhar V. Outcome in neurologically impaired patients with craniovertebral junction tuberculosis: results of combined anteroposterior surgery. *J Neurosurg* 2002;97(2):166–171.
- Goel A, Kulkarni AG, et al. Reduction of fixed atlantoaxial dislocation in 24 cases: technical note. *J Neurosurg Spine* 2005;2(4):505–509. DOI: 10.3171/spi.2005.2.4.0505.
- Bahadur R, Goyal T, et al. Transarticular screw fixation for atlantoaxial instability – modified Magerl's technique in 38 patients. *J Orthop Surg Res* 2010;5:87. DOI: 10.1186/1749-799x-5-87.
- Dunn RN, Stander H. Atlantoaxial fusion: Magerl transarticular vs Harms instrumentation techniques. *SA Orthopaedic J* 2014;13(2):31–34.
- Nurick S. The pathogenesis of the spinal cord disorder associated with cervical spondylosis. *Brain*. 1972;95:87–100.
- De la Garza-Ramos R, Ramhmdani S, et al. Prognostic value of preoperative Nurick grade and time with symptoms in patients with cervical myelopathy and gait impairment. *World Neurosurg* 2017;105:314–320. DOI: 10.1016/j.wneu.2017.05.166.
- Jain VK. Atlantoaxial dislocation. *Neurol India* 2012;60(1):9–17. DOI: 10.4103/0028-3886.93582.
- Mummaneni PV, Haid RW. Atlantoaxial fixation: overview of all techniques. *Neurol India* 2005;53(4):408–415.
- Tan M, Jiang X, et al. Revision surgery of irreducible atlantoaxial dislocation: a retrospective study of 16 cases. *Eur Spine J* 2011;20(12):2187–2194. DOI: 10.1007/s00586-011-1865-8.
- Jain N, Verma R, et al. CT and MR imaging of odontoid abnormalities: a pictorial review. *Indian J Radiol Imaging* 2016;26(1):108–119. DOI: 10.4103/0971-3026.178358.
- Oda T, Yonenobu K, et al. Diagnostic validity of space available for the spinal cord at C1 level for cervical myelopathy in patients with rheumatoid arthritis. *Spine (Phila Pa 1976)* 2009;34(13):1395–1398. DOI: 10.1097/BRS.0b013e3181a2b486.
- Berquist TH. Imaging of the postoperative spine. *Radiol Clin North Am* 2006;44:407–418. DOI: 10.1016/j.rcl.2006.01.002.
- Matveeva N, Janevski P, et al. Morphometric analysis of the cervical spinal canal on MRI. *Prilozi* 2013;34(2):97–103.
- Sardhara J, Behari S, et al. Syndromic vs nonsyndromic atlantoaxial dislocation: do clinico-radiological differences have a bearing on management? *Acta Neurochir (Wien)* 2013;155(7):1157–1167. DOI: 10.1007/s00701-013-1717-x.
- Mehrotra A, Srivastava A, et al. Role of effective canal diameter in assessing the pre-operative and the post-operative status of patients with bony cranio-vertebral anomalies. *Asian J Neurosurg* 2016;11(4):396–401. DOI: 10.4103/1793-5482.144149.
- Song G-C, Cho K-S, et al. Surgical treatment of craniovertebral junction instability: clinical outcomes and effectiveness in personal experience. *J Korean Neurosurg Soc* 2010;48(1):37–45. DOI: 10.3340/jkns.2010.48.1.37.