

Management of a Case of Spinal Cord Injury Sustained During Pregnancy

Amit Agrawal

ABSTRACT

Spinal cord injuries during pregnancy are not frequently reported in the literature. In the present article, we report a case of a 20 year pregnant female who sustained a spinal fracture in a road traffic accident. On examination, there were no neurological deficits. Imaging findings were suggestive of an unstable spine fracture which was managed surgically. The patient made a good recovery.

Key words: Pregnancy, Spinal cord injury, Spinal fracture

How to cite this article: Agrawal A. Management of a Case of Spinal Cord Injury Sustained During Pregnancy. *J Spinal Surg* 2018;5(3):132-134.

Source of support: Nil

Conflict of interest: None

INTRODUCTION

Spinal cord injuries during pregnancy are not common and in literature there is a limited number of publications which deals with this controversial issue.¹⁻⁵ The most common location of spinal fractures during pregnancy is at the thoracolumbar junction and it has been shown to associated with systemic osteoporosis during pregnancy.⁶⁻⁸ In present article we report a case of pregnant female who sustained unstable spinal fracture without neurological deficits and discuss the controversies in the management.

CASE REPORT

A 20 year female presented to the hospital six hours after the road traffic accident. She was hit by a lorry while she was crossing the road. Since the time of accident she was complaining of back pain localized over the lower dorsal region. The pain was increased by body movements. There was a history of loss of consciousness for ten minutes. She was complaining of pain and paresthesia in lower limbs. There was no history of limb weakness

or bowel, bladder disturbances. There was no history of vomiting, seizures or ear, nose, throat (ENT) bleed. There was history of 12 weeks of amenorrhea. She underwent a lower segment cesarian section two years back and had one healthy male child. Her general and systemic examination was unremarkable. She was conscious, alert and oriented to time place and person. Motor and sensory examination were normal. Deep and superficial reflexes were normally present. Local examination revealed tenderness over dorso-lumbar spinal region. Ultrasound of the abdomen showed was normal and showed a live fetus with good cardiac activity. Magnetic resonance imaging (MRI) was performed, and it showed anterior wedging of D11 and D12 vertebrae, with heterogeneous signal intensity. Wedging is more pronounced in D12 vertebrae with convex posterior bulge causing severe anterior thecal sac narrowing and cord indentation, terminal spinal cord at this level is showing T2 hyperintensities suggestive of cord edema (Fig. 1). In view of the spinal instability the patient was planned for spinal stabilization and counseled accordingly. She underwent a posterior approach and D11-L1 pedicle screws and rod fixation (Fig. 2). She was exposed to minimum possible radiation, and a lead shield cover was provided to protect the fetus. The patient recovered well without any residual neurological deficits

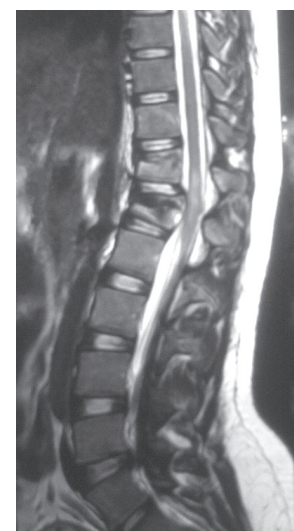

Fig. 1: Sagittal T2 weighted MRI image showing anterior wedging of D11 and D12 vertebrae, with heterogeneous signal intensity. Wedging is more pronounced in D12 vertebrae with convex posterior bulge causing severe anterior thecal sac narrowing and cord indentation, terminal spinal cord at this level is showing T2 hyperintensities suggestive of cord edema.

Professor

Department of Neurosurgery, Narayana Medical College and Hospital, Nellore, India

Corresponding Author: Amit Agrawal, Professor, Department of Neurosurgery, Narayana Medical College and Hospital, Nellore, India, e-mail: dramitagrawal@gmail.com

and doing well at follow up. She was started on iron and folic supplementation. Followed-up ultrasound of the fetus was normal as per of the age of the fetus.

DISCUSSION

It has been estimated that the incidence of accidental injuries range from 6 to 7% of all pregnant patients⁹ and vehicular motor accidents are the being the leading cause of this serious blunt trauma in pregnancy.^{9, 10} These injuries can be the cause of increased trauma-related fetal mortality.¹¹ In a pregnant female who present with the suspected history of trauma, the investigations are directed to assess the injuries sustained by mother and to assess the fetal well-being. Focused assessment with sonography for trauma (FAST) can easily be performed as the initial investigation in the emergency room¹² which can be followed by details ultrasonography to as certain gestational age and fetal well-being, fetal cardiac activity, the volume of amniotic fluid and integrity of placenta and amniotic membranes.^{13,14} Where there is suspicion of spinal cord injury MRI is the investigation of choice as it is useful for obtaining detailed information on soft tissue structures and the spinal cord.¹⁵

The management of female patients who sustain spinal trauma during pregnancy is comprised of a multidisciplinary approach and follows the standard protocol, i.e., initial assessment, resuscitation, and management prioritizing towards mother and the fetus as well.¹⁶ The interdisciplinary team include neurosurgeon, emergency medicine physicians, trauma surgeons, obstetricians, neonatologists, and the well-trained nursing staff.¹⁶ Apart from the addressing the obstetrical issues (assessment of the gestational age, monitoring the fetal activity, maintenance of uterine blood circulation, risk of radiation exposure, medication use, and decisions to continue pregnancy or if it is near term to perform caesarean delivery)¹⁶ the team should be able take care of the spinal cord injuries.

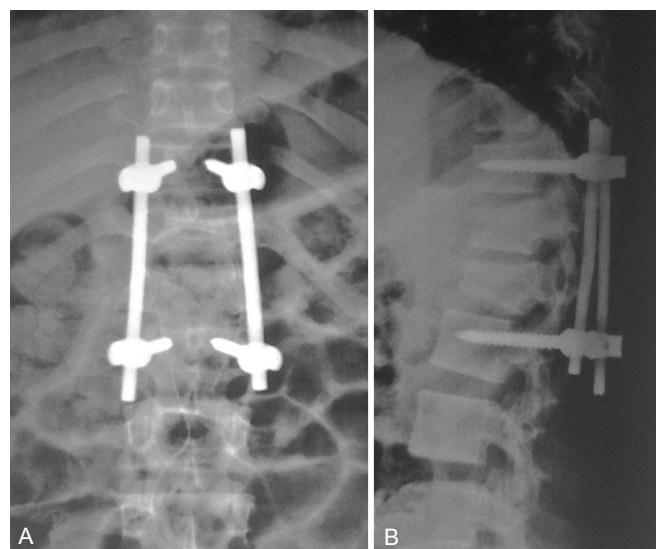
While it comes to the management of spinal injuries, if there are no neurological deficits or spinal instability these patients can be managed conservatively.⁶ However, if there is neurological involvement, an early surgery is recommended as it will enhance the chances of neurological recovery and help to prevent further injury due to spinal instability.^{17,18} There are case reports which supports that the spinal cord injuries can be managed surgically (spinal decompression and instrumentation) with relatively good maternal and fetal outcome.^{1,19} Radiation

exposure to the fetus is a major concern during as the patient will need support of image intensifier to place screws and rods, thus great care is required to reduce the radiation exposure to the minimum.¹ Radiation exposure during the first trimester of pregnancy can result in teratogenic effects.²⁰ Although the fetus is sensitive to the effects of radiation during eighth to the fifteenth week of gestation on the central nervous system, however, the exposure needs to high.²⁰

Patients who sustain spinal injuries (whether managed conservatively or undergo neurosurgical intervention) and wish to continue with pregnancy are at a greater risk to develop complications and needs regular follow up and close monitoring.^{1,21} However these patients are at greater risk to develop pregnancy-related complications (spontaneous abortion, fetal malformation, premature delivery and premature detachment of the placenta).²¹ In addition these patients (particularly with neurological deficits) are prone to develop repeated urinary tract infections, anemia, and unattended delivery, bed sores and lower limb deep vein thrombosis (with increased risk of pulmonary thromboembolism).^{21, 22}

CONCLUSION

In patients with complete spinal cord injury, uneventfully progression of the pregnancy with normal vaginal delivery and a healthy term newborn has been reported.¹ However for a favorable maternal and fetal outcome, a close co-operation between multidisciplinary team and mothers education all important for a good pregnancy outcome.^{1,23}



Figs 2A and B: Postoperative radiographs showing screws and rods in position

REFERENCES

1. Gotfryd AO, Franzin FJ, Poletto PR, et al. Fracturedislocation of the thoracic spine during second trimester of pregnancy: case report and literature review. *Revista Brasileira de Ortopedia* 2012 Jul;47(4):521-525.
2. Schnake KJ, Scholz M, Marx A, Hoffmann R, Kandziora F. Anterior, thoracoscopic-assisted reduction and stabilization of a thoracic burst fracture (T8) in a pregnant woman. *European Spine Journal* 2011;20(8):1217-1221.
3. Martínez-Padilla LA, Santana-Reyna MA, Díaz-Ruiz OS, et al. [Fracture dislocation of the thoracolumbar spine in pregnant patient: diagnostic by image and treatment]. *Acta ortopedica mexicana* 2010 Mar;24:100-107.
4. Vakil TDDS. Anesthetic Management of Paraplegic Patient with Pregnancy for Spine Surgery. *Indian Journal of Anaesthesia* 2003 Mar 1;47(2):145.
5. Reddy S, Gunakala K, Shaik N. Trauma during pregnancy. *Journal of Obstetric Anaesthesia and Critical Care* 2012 Jan 1;2(1):3.
6. Sarikaya S, Ozdolap S, Açıköz G, Erdem CZ. Pregnancy-associated osteoporosis with vertebral fractures and scoliosis. *Joint, bone, spine : revue du rhumatisme* 2004 Jan;71(1):84-85.
7. Bayram S, Ozturk C, Sivrioglu K, Aydinli U, Kucukoglu S. Kyphoplasty for pregnancy-associated osteoporotic vertebral fractures. *Joint, bone, spine : revue du rhumatisme* 2006 Oct;73(5):564-566.
8. Smith R, Phillips AJ. Osteoporosis during pregnancy and its management. *Scand J Rheumatol Suppl.* 1998;107:66-7.
9. Rosenfeld JA. Abdominal trauma in pregnancy. When is fetal monitoring necessary? *Postgraduate medicine* 1990 Nov 1;88(6):89-94.
10. Connolly AM, Katz VL, Bash KL, McMahon MJ, Hansen WF. Trauma and pregnancy. *American journal of perinatology* 1997 Jul;14(06):331-336.
11. Lane PL. Traumatic fetal deaths. *The Journal of emergency medicine* 1989 Sep 1;7(5):433-435.
12. Natarajan B, Gupta PK, Cemaj S, Sorensen M, Hatzoudis GI, Forse RA. FAST scan: is it worth doing in hemodynamically stable blunt trauma patients? *Surgery* 2010;148:695-700; discussion 700. 2010 Oct;148(4):695-701
13. Pearlman MD, Tintinalli JE, Lorenz RP. A prospective controlled study of outcome after trauma during pregnancy. *American journal of obstetrics and gynecology* 1990 Jun 1;162(6):1502-1510.
14. Goodwin TM, Breen MT. Pregnancy outcome and fetomaternal hemorrhage after noncatastrophic trauma. *American journal of obstetrics and gynecology* 1990 Mar 1;162(3): 665-671.
15. Looby S, Flanders A. Spine trauma. *Radiol Clin North Am* 2011 Jan;49(1):129-163.
16. Mattox KL, Goetzl L. Trauma in pregnancy. *Critical care medicine* 2005 Oct;33:3385-389.
17. Papadopoulos SM, Selden NR, Quint DJ, Patel N, Gillespie B, Grube S. Immediate spinal cord decompression for cervical spinal cord injury: feasibility and outcome. *The Journal of Trauma* 2002;52(2):323-332.
18. Fehlings MG, Sekhon LH, Tator C. The role and timing of decompression in acute spinal cord injury: what do we know? What should we do? *Spine (Phila Pa 1976)*. 2001;26(24 Suppl):S101-S110.
19. Lenarz CJ, Wittgen CM, Place HM. Management of a pregnant patient with a burst fracture causing neurologic injury. A case report. *The Journal of bone and joint surgery American volume* 2009;91(7):1747-1749.
20. Brent R. Pregnancy and radiation exposure. *Health Physics Society.* 2008. Accessed 2015/06/20 Available at: <http://hps.org/hpspublications/articles/pregnancyandradiationexposureinfosheet.html>
21. Kuczkowski KM. Labor analgesia for the parturient with spinal cord injury: what does an obstetrician need to know? *Archives of gynecology and obstetrics* 2006;274:108-112.
22. ACOG committee opinion. Obstetric management of patients with spinal cord injuries. Number 275, September 2002. Committee on Obstetric Practice. American College of Obstetrics and Gynecology. *Int J Gynaecol Obstet* 2002;79:189-191.
23. Sterling L, Keunen J, Wigdor E, Sermer M, Maxwell C. Pregnancy outcomes in women with spinal cord lesions. *J Obstet Gynaecol Can.* 2013;35(1):39-43.