

Lumbar Microendoscopic Discectomy: Clinical Results of 920 Patients

¹Amitesh Dubey, ²Nishtha Yadav, ³Shailendra Ratre, ⁴Vijay S Parihar, ⁵Yad R Yadav

ABSTRACT

Introduction: Surgery in properly selected lumbar disk prolapse provides better early results than conservative management. Lumbar microendoscopic discectomy (MED) has been found to be associated with good results. We are reporting our experience of 920 consecutive patients using MED technique.

Materials and methods: Visual analog scale (VAS) scores for back pain and leg pain were recorded preoperatively and at 3, 6, and 12 months postoperatively. MacNab criteria were used to measure postoperative outcome. Indication for surgery was persistent leg pain despite 12 weeks of conservative management. The progressive neurologic deficit was also an indication for surgery. Disk prolapses associated with spinal instability and infections were excluded.

Results: The mean VAS score for leg and back pain before surgery was 7.6 and 2.4 respectively, which improved to 1.5 and 0.6 three months after surgery. There was a significant improvement in VAS scores for backache and radicular pain in 819 patients (89%) compared with preoperative values. About 91% patients had good-to-excellent results according to MacNab criteria. The average operative time and blood loss were 70 minutes and 20 mL respectively. Unilateral or bilateral symptoms were observed in 673 and 247 patients respectively. There were 14 recurrent disk surgeries. Accidental intraoperative single-facet injury, minor dural injuries, postoperative discitis, and root injury occurred in 5, 12, 5, and 2 patients respectively. The mean follow-up was 38 months.

Conclusion: Microendoscopic discectomy is an effective and safe alternate technique for lumbar disk disease.

Keywords: Endoscopes, Endoscopic surgical procedure, Intervertebral disk, Intervertebral disk degeneration, Lumbar vertebrae, Minimally invasive surgical procedures, Spine.

How to cite this article: Dubey A, Yadav N, Ratre S, Parihar VS, Yadav YR. Lumbar Microendoscopic Discectomy: Clinical Results of 920 Patients. *J Spinal Surg* 2018;5(1):23-28.

Source of support: Nil

Conflict of interest: None

^{1,2}Senior Resident, ^{3,4}Assistant Professor, ⁵Professor and Head

^{1,3-5}Department of Neurosurgery, Netaji Subhash Chandra Bose Medical College, Jabalpur, Madhya Pradesh, India

²Department of Radiodiagnosis and Imaging, National Institute of Mental Health and Neurosciences, Bengaluru, Karnataka, India

Corresponding Author: Yad R Yadav, Professor and Head Department of Neurosurgery, Netaji Subhash Chandra Bose Medical College, Jabalpur, Madhya Pradesh, India, Phone: +919893711193, e-mail: yadavyr@yahoo.co.in

INTRODUCTION

Lumbar disk prolapses account for 5% of low back disorders, yet it is one of the most common reasons for surgery. Surgical management for carefully selected patients with lumbar disk prolapse provides faster relief from the acute attack than conservative management. Surgical treatment of the disk disease has evolved from traditional open spine surgery to micro-discectomy to endoscopic spine surgery. The development of endoscopic discectomy has allowed surgeons to relieve nerve root compression using minimally invasive surgical approach. It was possible due to improvements in the optics, high-resolution camera, high-speed burr, and better instruments. There has been increased interest in endoscopic technique due to less tissue injury, reduced blood loss, better cosmesis, less epidural fibrosis and scarring, reduced hospital stay, and early recovery. This technique, on the contrary, is associated with steep learning curve. After gaining sufficient experience in endoscopic surgery, MED has been found to be associated with good results.¹⁻¹⁷ We are reporting our experience of 920 patients of MED.

MATERIALS AND METHODS

Nine hundred twenty consecutive patients with lumbar disk herniation underwent endoscopic interlaminar discectomy from January 2006 to July 2017. Indication for surgery was a persistent bothersome pain in the leg despite conservative management for 12 weeks. The progressive neurologic deficit was also an indication for surgery. All patients with severe pain were given a trial of medical therapy for at least 12 weeks except 18 patients who had a large disk herniation and underwent surgery 3 to 5 days after the start of acute pain. Epidural or root block injection treatment and ozone treatment were also performed in other institutions in 35 and 80 patients respectively, along with conservative management before surgery. There were no additional difficulties during surgery after nerve block cases or ozone treatment patients. Conservative management included anti-inflammatory agents (steroidal and/or nonsteroidal) with analgesics, and muscle relaxants along with bed rest. Patients with a single nerve root involvement underwent surgery in the initial part of the study. After the initial 50 patients, single- as well as

double-level disk with unilateral or bilateral symptoms including central, sequestered, or migrated disk were also included. Disk prolapses associated with spinal instability and infections were excluded. Visual analog scale scores for back and leg pain were recorded preoperatively and at 3, 6, and 12 months postoperatively, which was rated from 0 (no pain) to 10 (unbearable severe pain). MacNab criteria were used to measure postoperative outcome. Excellent outcome was defined when there was no pain and no restriction of movement. These patients were able to work normally. It was classified as good when there was occasional pain but patients were able to work normally. Fair outcome was used when there was slight improvement from preoperative condition, whereas poor result was leveled when there was no improvement. All patients had preoperative magnetic resonance imaging (MRI) of lumbar spine. Magnetic resonance imaging was important to find out if there was sequestered or contained disk prolapse. It also helped to find out ventral or dorsal, lateral, or medial disk prolapse in relation to nerve root.¹⁸ Postoperative MRI was performed when a patient continued to have symptoms.

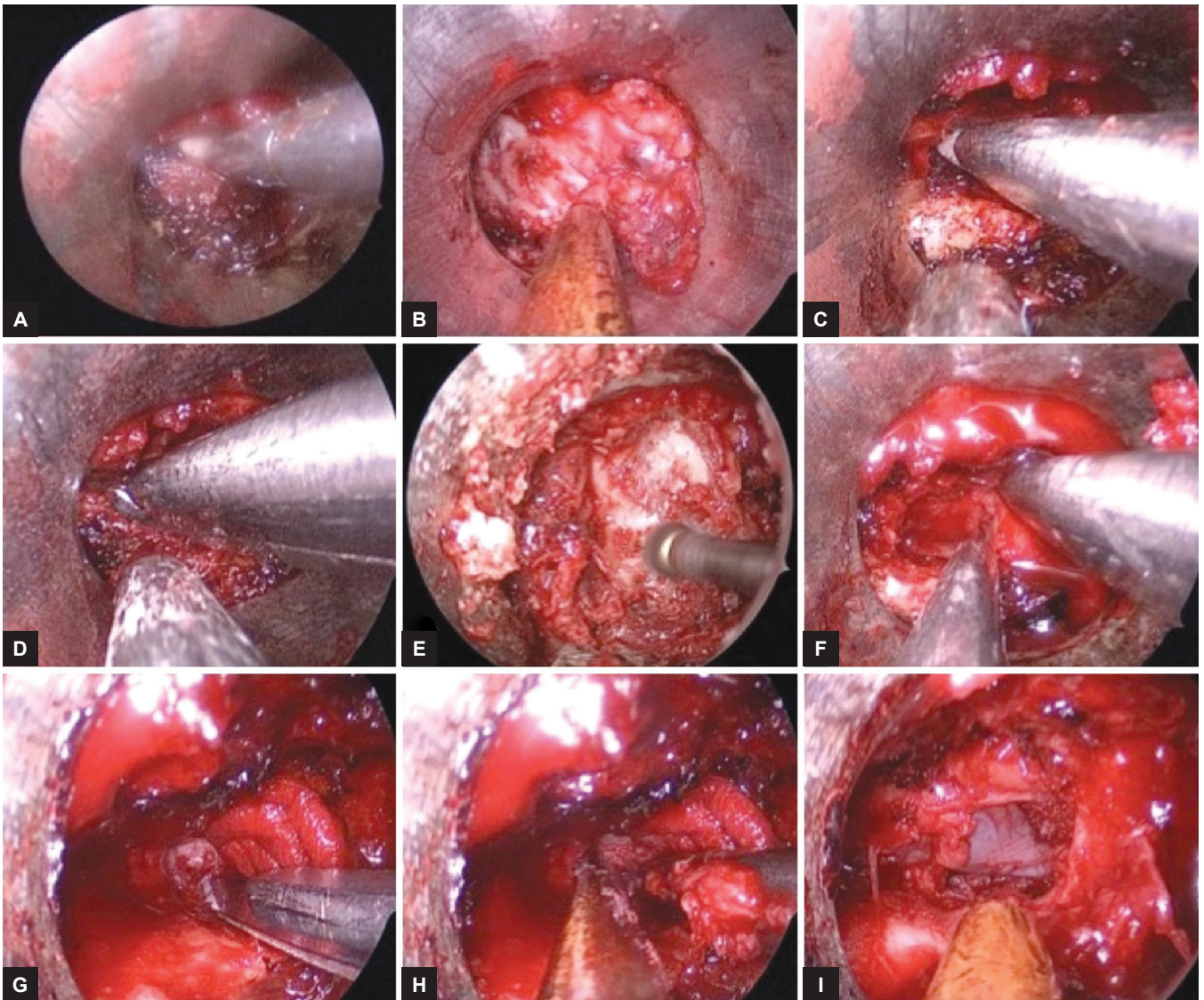
The majority of the patients were operated by a single surgeon using the Destandau system (Karl Storz, Germany) or EasyGO system (Karl Storz GmbH and Co KG Tuttlingen, Germany). Postoperatively, all patients were mobilized as soon as the pain subsided and were discharged 24 to 72 hours after surgery. Clinical outcome (MacNab criteria and VAS score) including complications was evaluated from the record. Patients were followed up at 2 and 6 weeks and 3, 6, and 12 months. Follow-up ranged from 6 to 72 months (average 38 months).

Surgical Technique

All the surgeries were performed in prone position on either bolsters or a spinal frame, with the abdomen free on a radiolucent table under general anesthesia using a full endoscopic technique. Microscope was not used in any case. The skin incision was marked after precise localization of the level under image guidance using a C arm. About 2 cm skin incision was made nearly 1 cm away from the midline. The fascia was cut just lateral to midline. Surgical access was created by dilatation technology using stout scissors and an operating sheath. The operating sheath was docked at the desired level. Soft tissue on the lamina, facet joint, and ligamentum flavum was removed. The part of superior and inferior lamina along with the medial facet was removed using burrs and Kerrison rongeurs (Fig. 1). Ligamentum flavum was removed in most of the cases (partially preserved in 27 patients). The dural margin and nerve root were identified after the removal of ligamentum flavum. The

sequestered pieces were removed or nerve root was decompressed after annulotomy. Two-level pathologies could be addressed through the same incision by moving and angulating the sheath if it was possible. Two incisions were used when skin markings corresponding to disk level were placed more than 2.5 cm away. It is better to give two incisions rather than angulating scope too much. Too much angulation allows protrusion of soft tissue or gauze piece inside the tube, making endoscopic procedure very difficult. Removal of opposite-side ligamentum flavum and osteophytes of the opposite facet could be done. Closure was done after a thorough wash and the dura was covered with a gelfoam. The scope was removed and the lumbodorsal fascia was sutured. Subcuticular skin sutures were taken and dressing was applied.

There is an increased risk of dural tear when dealing with opposite-side pathology, in spinal canal stenosis, central disk, and multiple levels. Minor dural punctures were managed by the application of a medical absorbable gelatin sponge (AbGel, Shri Gopal Krishna Labs Pvt. Ltd., Mumbai, India) on the dura while significant dural tears were treated using fat and fibrin glue. Although endoscopic techniques have many advantages, it has some limitations. There is a steep learning curve in endoscopic surgeries. The surgeon needs to develop skills for microscopic and unique endoscopic surgery to properly perform endoscopic surgeries.¹⁹ Cadaveric dissection, attending live workshops, watching operative videos, practicing in training labs, working with the expert endoscopic surgeon, and use of simulators can help reduce the learning curve.²⁰ Slender, single limb, straight, and round shape instruments are preferred in endoscopic surgeries.¹⁹ On the contrary, bayonet-shaped instruments are preferred in microscopic technique. Slightly angled instrument tip is an advantage in endoscopic surgery. Side rod of the table (where telescope holder is attached) should not be loose to avoid jerky movements when telescope holder is used.¹⁹ There should be a proper orientation of the camera. It should be checked periodically during surgery as it may rotate during surgery, making surgery difficult due to disorientation. The platform should be used especially for short stature surgeon. Use of platform prevents shoulder abduction and fatigue. It allows observation of operative area and permits introduction of the instrument in the blind area when telescope holder is used. Proper hand support prevents fatigue and improves precision. The unsupported hand may increase physiological tremors. Precision grip, with quiet hand technique, should be used to improve precision.²⁰ If power grip has to be used because of poor instrument design, the precision grip should be added by the other hand. All body parts should be in a relaxed position with minimal muscle contractions. Fogging of



Figs 1A to I: Steps of endoscopic interlaminar technique showing removal of soft tissue from lamina (A), lamina in view after soft tissue removal (B). Part of lamina being removed by Kerrison punch (C, D) and burr (E). Ligamentum flavum being removed (F), annulotomy being done (G), and the disk material being removed (H). Well-decompressed thecal sac after surgery (I)

the lens by the increased humidity of air can result in poor visualization; simple removal of the humid air by suction can improve visualization. Avoid sword effect; telescope and instruments should be directed in the same direction.

RESULTS

A retrospective study of 920 cases of endoscopic interlaminar discectomy was performed. Age of the patients ranged from 19 to 65 years (average 38 years). The mean VAS score for leg pain immediately before surgery was 7.6. The mean VAS score for back pain before surgery was 2.4. Motor weakness was found in 42 patients before surgery. The mean VAS score for leg and back pain improved to 1.5 and 0.6 three months after surgery. There was a significant improvement in VAS scores for backache and radicular pain in 819 patients (89%) when compared with preoperative values. Overall, 837 (91%) of patients

had good-to-excellent results according to MacNab criteria in the postoperative period. Fair and poor outcome was observed in 64 and 19 patients respectively. All 42 patients with motor weakness had some recovery after surgery.

The average operative time was 70 minutes (40–180 minutes). The operating time reduced progressively, which improved to an average of 60 minutes in last 500 cases. Average blood loss was 20 mL. There were 764 and 156 patients with single- and two-level surgeries respectively. Unilateral or bilateral symptoms were observed in 673 and 247 patients respectively. There were 14 recurrent disks, whereas 906 were primary disk surgeries. There were five recurrences after our endoscopic surgeries, whereas three and six were after microscopic or open surgeries. All of them underwent successful endoscopic surgeries by interlaminar technique. Migrated,

calcified, and far lateral disk was observed in 91, 8, and 6 patients respectively, which were successfully removed. We could successfully remove far lateral disk without any injury to the facet joint using intertransverse approach.

The accidental intraoperative single-facet injury occurred in five patients, majority of them were in the initial learning period. Minor dural punctures occurred in 12 cases. Five patients had postoperative discitis and all of them were managed conservatively. Root injury occurred in two patients. Three patients had some persistent paresthesia at follow-up. Most of the complications (dural tear = 7 cases, facet injury = 3 cases, root injury = 1 case, conversion into open surgery = 1 case) were seen in the initial learning curve. Conversion to open surgery was required in one patient who had root protrusion after a dural tear in the initial learning curve. The mean follow-up was 38 months (6–72 months).

DISCUSSION

Endoscopic techniques are performed in various cranial and spinal conditions, such as brain abscesses, hydrocephalus, intraventricular hemorrhage, arachnoid cyst, intracerebral hematoma, trigeminal neuralgia, pituitary tumor, craniovertebral junction lesions, colloid cyst, cervical spine, craniopharyngiomas, deep-seated brain tumors, cerebrospinal fluid rhinorrhea, spine tumors, and Arnold–Chiari malformations. There was a good clinical outcome after the surgery in our study with 91% excellent to good overall results. Similar observations were made in other series.¹⁻¹⁷ Good decompression of thecal sac can be achieved using endoscopic techniques.^{6,21,22} Good clinical outcome of MED at long-term follow-up is also available.³

Operative time (the average 60 minutes for the last 500 patients) and average blood loss are comparable to other surgical techniques for lumbar disk. Bilateral decompression could be achieved in 247 patients by the unilateral approach in our study very effectively; similar observations were made in other studies.²³⁻²⁵ Results of 14 recurrent disks were good in our study; similar observations were made by other groups.²⁶⁻³¹ Migrated, calcified, and far lateral disk could be operated with good results in our study; similar results were observed in other studies for migrated disk,³²⁻³⁶ including in dorsally migrated.³⁷ The calcified disk and far lateral disk (without any injury to the facet joint) could be removed successfully by intertransverse process approach in our study. Similar observations about the calcified disk³⁸ and far lateral disk^{39,40} were made in other studies.

Facet injury, minor dural punctures, postoperative discitis, and persistent paresthesias were observed in our study, which was more common in the initial learning curve.

Dural tears remain a concern during the learning stage in endoscopic lumbar discectomy.^{41,42} Dural closure using multilayer technique with an autologous muscle graft and fibrin sealant is a fast, safe, and alternative technique for the management of dural tear in microendoscopic surgery.^{43,44} This technique is safe and effective once sufficient learning curve has been achieved.⁵ Obtaining microsurgical experience, attending workshops, and selecting suitable patients can help shorten the learning curve and decrease complications.^{5,45}

Comparison with Microdiscectomy and Transforaminal Approach

There is growing evidence that MED is a valid and safe alternative to standard microdiscectomy.^{9,46} There are also reports that microdiscectomy using tubular retractor is effective as compared with endoscopic technique.¹⁰ The choice depends on the surgeon and their level of comfort with either endoscopic or microscopic technique. The endoscopical assistance allows enhanced visualization of the anatomy that is hidden from view in microscopic procedures.^{12,47} We also agree that almost similar results can be obtained with the microscopic technique by an experienced microscopic surgeon. In our study, we found that the viewing angle and the total area of the exposure, especially of the opposite side, were better in endoscopic surgery as compared with microscopic technique.

Transforaminal endoscopy is another effective approach for lumbar disk. It is preferred for shoulder type, centrally located, and recurrent disk herniation, while MED is preferred for axillary type and migrated disks, especially those of a high-grade migration. Although an expert endoscopic surgeon can manage most of the disk prolapses, such as migrated, calcified disk, uncontained sequestered disk by transforaminal approach, L5-S1 disk with high iliac crest, dorsally migrated, lateral stenosis, short pedicle, facet hypertrophy, associated ligamentum hypertrophy, and axillary-type prolapses are difficult to manage by transforaminal approach.⁴⁸

ADVANTAGES AND LIMITATIONS OF THE STUDY

Microendoscopic discectomy was found to be less traumatic than open surgery. There is less change of interleukin, C-reactive protein, and creatinine kinase after MED proves that the procedure is less traumatic to patients than open discectomy.⁴⁹ This technique is very effective for bilateral decompression,²³⁻²⁵ in recurrent disk,²⁶⁻³¹ migrated disk³²⁻³⁶ including in dorsally migrated,³⁷ the calcified disk,³⁸ far lateral disk,^{39,40} and in lumbar canal stenosis with lateral recess stenosis.^{22,50,51} Disk at L5-S1 level can be approached by MED. Most spine surgeons

are more familiar with MED. It can be done under general anesthesia in uncooperative and anxious patients. There is better illumination, magnification, visualization, minimal bone resection, minimal epidural fibrosis, less postoperative pain, better cosmetic results, shorter hospital stay, early mobilization, and shorter recovery. The two-dimensional vision of endoscopic technique may cause loss of depth perception. The retrospective study, steep learning curve for the technique, single-center experience of surgeries that were mostly performed by the single surgeon are limitations of this study.

CONCLUSION

Microendoscopic discectomy was a safe and effective alternative procedure to microdiscectomy for lumbar disc disease. Although there are some complications and difficulties especially in the initial learning curve, it is safe and effective when the surgeon is experienced in endoscopic procedure.

REFERENCES

- Li SH, Li HZ, Zhao JR. Clinical comparison between microendoscopic discectomy (MED) and open discectomy for treatment of lumbar disc herniation. *Zhongguo Gu Shang* 2008 May;21(5):349-351.
- Righesso O, Falavigna A, Avanzi O. Comparison of open discectomy with microendoscopic discectomy in lumbar disc herniations: results of a randomized controlled trial. *Neurosurgery* 2007 Sep;61(3):545-549, discussion 549.
- Wang M, Zhou Y, Wang J, Zhang Z, Li C. A 10-year follow-up study on long-term clinical outcomes of lumbar microendoscopic discectomy. *J Neurol Surg A Cent Eur Neurosurg* 2012 Aug;73(4):195-198.
- Yadav YR, Parihar V, Namdev H, Agarwal M, Bhatele PR. Endoscopic inter laminar management of lumbar disc disease. *J Neurol Surg A Cent Eur Neurosurg* 2013 Mar;74(2):77-81.
- Yadav YR, Parihar V, Kher Y, Bhatele PR. Endoscopic inter laminar management of lumbar disease. *Asian J Neurosurg* 2016 Jan-Mar;11(1):1-7
- Dewanngan NK, Yadav YR, Parihar VS, Ratre S, Kher Y, Bhatele P. Extent of decompression of lumbar spinal canal after endoscopic surgery. *J Neurol Surg A Cent Eur Neurosurg* 2017 Nov;78(6):541-547.
- Phan K, Xu J, Schultz K, Alvi MA, Lu VM, Kerezoudis P, Maloney PR, Murphy ME, Mobbs RJ, Bydon M. Full-endoscopic versus micro-endoscopic and open discectomy: a systematic review and meta-analysis of outcomes and complications. *Clin Neurol Neurosurg* 2017 Mar;154:1-12.
- Liu X, Yuan S, Tian Y, Wang L, Gong L, Zheng Y, Li J. Comparison of percutaneous endoscopic transforaminal discectomy, microendoscopic discectomy, and microdiscectomy for symptomatic lumbar disc herniation: minimum 2-year follow-up results. *J Neurosurg Spine* 2018 Mar;28(3):317-325.
- Casimiro M. Short-term outcome comparison between full-endoscopic interlaminar approach and open minimally invasive microsurgical technique for treatment of lumbar disc herniation. *World Neurosurg* 2017 Dec;108:894.e1-900.e1.
- Akinduro OO, Kerezoudis P, Alvi MA, Yoon JW, Eluchie J, Murad MH, Wang Z, Chen SG, Bydon M. Open versus minimally invasive surgery for extraforaminal lumbar disk herniation: a systematic review and meta-analysis. *World Neurosurg* 2017 Dec;108:924.e3-938.e3.
- Yao Y, Zhang H, Wu J, Liu H, Zhang Z, Tang Y, Zhou Y. Comparison of three minimally invasive spine surgery methods for revision surgery for recurrent herniation after percutaneous endoscopic lumbar discectomy. *World Neurosurg* 2017 Apr;100:641.e1-647.e1.
- Belykh E, Giers MB, Preul MC, Theodore N, Byvaltsev V. Prospective comparison of microsurgical, tubular-based endoscopic, and endoscopically assisted discectomies: clinical effectiveness and complications in railway workers. *World Neurosurg* 2016 Jun;90:273-280.
- He J, Xiao S, Wu Z, Yuan Z. Microendoscopic discectomy versus open discectomy for lumbar disc herniation: a meta-analysis. *Eur Spine J* 2016 May;25(5):1373-1381.
- Ruan W, Feng F, Liu Z, Xie J, Cai L, Ping A. Comparison of percutaneous endoscopic lumbar discectomy versus open lumbar microdiscectomy for lumbar disc herniation: a meta-analysis. *Int J Surg* 2016 Jul;31:86-92.
- Tu Z, Li YW, Wang B, Lu G, Li L, Kuang L, Dai Y. Clinical outcome of full-endoscopic interlaminar discectomy for single-level lumbar disc herniation: a minimum of 5-year follow-up. *Pain Physician* 2017 Mar;20(3):E425-E430.
- Bhaisare R, Kamble B, Patond K. Long-term results of endoscopic lumbar discectomy by "Destandau's Technique". *Asian Spine J* 2016 Apr;10(2):289-297.
- Sencer A, Yorukoglu AG, Akcakaya MO, Aras Y, Aydoseli A, Boyali O, Sencan F, Sabanci PA, Gomleksiz C, Imer M, et al. Fully endoscopic interlaminar and transforaminal lumbar discectomy: short-term clinical results of 163 surgically treated patients. *World Neurosurg* 2014 Nov;82(5):884-890.
- Xu BS, Xia Q, Ma XL, Yang Q, Ji N, Shah S, He J, Liu Y. The usefulness of magnetic resonance imaging for sequestered lumbar disc herniation treated with endoscopic surgery. *J Xray Sci Technol* 2012;20(3):373-381.
- Yadav YR, Parihar V, Kher Y. Complication avoidance and its management in endoscopic neurosurgery. *Neurol India* 2013 May-Jun;61(3):217-225.
- Yadav YR, Parihar V, Ratre S, Iqbal M. Microneurosurgical skills training. *J Neurol Surg A Cent Eur Neurosurg* 2016 Mar;77(2):146-154.
- Zhou X, Zhang L, Zhang HL, He SS, Gu X, Gu GF, Fu QS. Clinical outcome and postoperative CT measurements of microendoscopic decompression for lumbar spinal stenosis. *Clin Spine Surg* 2017 Jul;30(6):243-250.
- Wada K, Sairyo K, Sakai T, Yasui N. Minimally invasive endoscopic bilateral decompression with a unilateral approach (endo-BiDUA) for elderly patients with lumbar spinal canal stenosis. *Minim Invasive Neurosurg* 2010 Apr;53(2):65-68.
- Xu BS, Tan QS, Xia Q, Ji N, Hu YC. Bilateral decompression via unilateral fenestration using mobile microendoscopic discectomy technique for lumbar spinal stenosis. *Orthop Surg* 2010 May;2(2):106-110.
- Xu B, Xu H, Ma X, Liu Y, Yang Q, Jiang H, Li N, Ji N. Bilateral decompression and intervertebral fusion via unilateral fenestration for complex lumbar spinal stenosis with a mobile microendoscopic technique. *Medicine (Baltimore)* 2018 Jan;97(4):e9715.

25. Komp M, Hahn P, Merk H, Godolias G, Ruetten S. Bilateral operation of lumbar degenerative central spinal stenosis in full-endoscopic interlaminar technique with unilateral approach: prospective 2-year results of 74 patients. *J Spinal Disord Tech* 2011 Jul;24(5):281-287.
26. Smith JS, Ogden AT, Shafizadeh S, Fessler RG. Clinical outcomes after microendoscopic discectomy for recurrent lumbar disc herniation. *J Spinal Disord Tech* 2010 Feb;23(1):30-34.
27. Ruetten S, Komp M, Merk H, Godolias G. Recurrent lumbar disc herniation after conventional discectomy: a prospective, randomized study comparing full-endoscopic interlaminar and transforaminal versus microsurgical revision. *J Spinal Disord Tech* 2009 Apr;22(2):122-129.
28. Wu J, Zhang C, Lu K, Li C, Zhou Y. Percutaneous endoscopic lumbar reoperation for recurrent sciatica symptoms: a retrospective analysis of outcomes and prognostic factors in 94 patients. *World Neurosurg* 2018 Jan;109:e761-e769.
29. Kim CH, Chung CK, Sohn S, Lee S, Park SB. The surgical outcome and the surgical strategy of percutaneous endoscopic discectomy for recurrent disk herniation. *J Spinal Disord Tech* 2014 Dec;27(8):415-422.
30. Nomura K, Yoshida M, Kawai M, Okada M, Nakao S. A novel microendoscopically assisted approach for the treatment of recurrent lumbar disc herniation: transosseous discectomy surgery. *J Neurol Surg A Cent Eur Neurosurg* 2014 May;75(3):183-188.
31. Koga S, Sairyo K, Shibuya I, Kanamori Y, Kosugi T, Matsu-moto H, Kitagawa Y, Sumita T, Dezawa A. Minimally invasive removal of a recurrent lumbar herniated nucleus pulposus by the small incised microendoscopic discectomy interlaminar approach. *Asian J Endosc Surg* 2012 Feb;5(1):34-37.
32. Ruetten S, Komp M, Godolias G. A new full-endoscopic technique for the interlaminar operation of lumbar disc herniations using 6-mm endoscopes: prospective 2-year results of 331 patients. *Minim Invasive Neurosurg* 2006 Apr;49(2):80-87.
33. Choi G, Prada N, Modi HN, Vasavada NB, Kim JS, Lee SH. Percutaneous endoscopic lumbar herniectomy for high-grade down migrated L4-L5 disc through an L5-S1 interlaminar approach: a technical note. *Minim Invasive Neurosurg* 2010 Jun;53(3):147-152.
34. Liu C, Chu L, Yong HC, Chen L, Deng ZL. Percutaneous endoscopic lumbar discectomy for highly migrated lumbar disc herniation. *Pain Physician* 2017 Jan-Feb;20(1):E75-E84.
35. Hussein M. Minimal incision, multifidus-sparing microendoscopic discectomy versus conventional microdiscectomy for highly migrated intracanal lumbar disk herniations. *J Am Acad Orthop Surg* 2016 Nov;24(11):805-813.
36. Du J, Tang X, Jing X, Li N, Wang Y, Zhang X. Outcomes of percutaneous endoscopic lumbar discectomy via a translaminar approach, especially for soft, highly down-migrated lumbar disc herniation. *Int Orthop* 2016 Jun;40(6):1247-1252.
37. Koga S, Sairyo K, Kon T, Shibuya I, Kanamori Y, Kosugi T, Konno R, Arai T, Dezawa A. Endoscopic removal of herniated nucleus pulposus migrated dorsally to the dural sac. *Asian J Endosc Surg* 2011 Feb;4(1):36-39.
38. Dabo X, Ziqiang C, Yinchuan Z, Haijian N, Kai C, Yanbin L, Qiang F, Chuanfeng W. The clinical results of percutaneous endoscopic interlaminar discectomy (PEID) in the treatment of calcified lumbar disc herniation: a case-control study. *Pain Physician* 2016 Feb;19(2):69-76.
39. Li SW, Yin HP, Cao ZH, Bai M, Du ZC, Wang YP. Inter-transverse approach microendoscopic discectomy for far lateral lumbar disc herniation. *Zhongguo Gu Shang* 2014 Sep;27(9):752-755.
40. Yoshimoto M, Iwase T, Takebayashi T, Ida K, Yamashita T. Microendoscopic discectomy for far lateral lumbar disk herniation: less surgical invasiveness and minimum 2-year follow-up results. *J Spinal Disord Tech* 2014 Feb;27(1):E1-E7.
41. Li SW, Yin HP, Wu YM, Bai M, Du ZC, Wu HJ, Meng GD. Analysis of intraoperative complications of microendoscopic discectomy and corresponding preventive measures. *Zhongguo Gu Shang* 2013 Mar;26(3):218-221.
42. Ebata S, Sato H, Orii H, Sasaki S, Ohba T, Haro H. Risk management in posterior spinal endoscopic surgery in lumbar diseases. *J Orthop Sci* 2013 May;18(3):369-373.
43. Oertel JM, Burkhardt BW. Full endoscopic treatment of dural tears in lumbar spine surgery. *Eur Spine J* 2017 Oct;26(10):2496-2503.
44. Huliappa HA, Singh RK, Singh SK, Jaiswal M, Jaiswal S, Srivastava C, Ojha B, Chandra A, Chhabra S. Transdural herniated lumbar disc disease with muscle patch for closure of durotomy—a brief review of literature. *Neurol Neurochir Pol* 2017 Mar-Apr;51(2):149-155.
45. Wang B, Lü G, Patel AA, Ren P, Cheng I. An evaluation of the learning curve for a complex surgical technique: the full endoscopic interlaminar approach for lumbar disc herniations. *Spine J* 2011 Feb;11(2):122-130.
46. Anichini G, Landi A, Caporlingua F, Beer-Furlan A, Brogna C, Delfini R, Passacantilli E. Lumbar endoscopic microdiscectomy: where are we now? An updated literature review focused on clinical outcome, complications, and rate of recurrence. *Biomed Res Int* 2015 Nov;2015:417801.
47. Song H, Hu W, Liu Z, Hao Y, Zhang X. Percutaneous endoscopic interlaminar discectomy of L5-S1 disc herniation: a comparison between intermittent endoscopy technique and full endoscopy technique. *J Orthop Surg Res* 2017 Oct;12(1):162.
48. Choi KC, Kim JS, Ryu KS, Kang BU, Ahn Y, Lee SH. Percutaneous endoscopic lumbar discectomy for L5-S1 disc herniation: transforaminal versus interlaminar approach. *Pain Physician* 2013 Nov-Dec;16(6):547-556.
49. Akçakaya MO, Yörükoğlu AG, Aydoseli A, Aras Y, Sabancı PA, Altunrende ME, Dolgun M, Göker B, Şencan F, Ali A, et al. Serum creatine phosphokinase levels as an indicator of muscle injury following lumbar disc surgery: comparison of fully endoscopic discectomy and microdiscectomy. *Clin Neurol Neurosurg* 2016 Jun;145:74-78.
50. Ikuta K, Tono O, Tanaka T, Arima J, Nakano S, Sasaki K, Oga M. Surgical complications of microendoscopic procedures for lumbar spinal stenosis. *Minim Invasive Neurosurg* 2007 Jun;50(3):145-149.
51. Zhai XJ, Bi DW, Fu H, Zu G. Treatment of lumbar disc herniation with lateral recess stenosis by microendoscopic discectomy. *Zhongguo Gu Shang* 2008 Feb;21(2):120-121.