

Diaphragm Pacing (Phrenic Nerve Stimulation) in a High Cervical Spinal Cord Injury in Quadriplegic Patient

¹JKBC Parthiban, ²S Balasundaram, ³K Rajendran, ⁴V Arulselvan, ⁵MN Sivakumar

ABSTRACT

The aim of this editorial is to share and discuss our experience of using diaphragm pacing (phrenic nerve stimulation) in a quadriplegic patient who was ventilator dependent following odontoid fracture and high-level spinal cord contusion. Performing diaphragm pacing is possible in India. However, case selection and involvement of team of specialists is essential. Awareness is lacking among medical professionals and in our society about rehabilitation of quadriplegics.

Keywords: Diaphragm pacing, Phrenic nerve, Spinal cord injury.

How to cite this article: Parthiban JKBC, Balasundaram S, Rajendran K, Arulselvan V, Sivakumar MN. Diaphragm Pacing (Phrenic Nerve Stimulation) in a High Cervical Spinal Cord Injury in Quadriplegic Patient. *J Spinal Surg* 2017;4(1):1-3.

Source of support: Nil

Conflict of interest: None

INTRODUCTION

Diaphragm pacing is still in infancy state in India and is not as popular as cardiac pacing. It is probably due to the mindset of many patients and clinicians that quadriplegic patients are at the end stage of life and ventilatory support is a great burden to all. Developed countries have taken much strides in applying this technology to the patients who needed to have better quality of life away from ventilator. It is not only used in traumatic spinal cord injury patients but also in other neuro medical conditions where the patients end up in respiratory paralysis. We

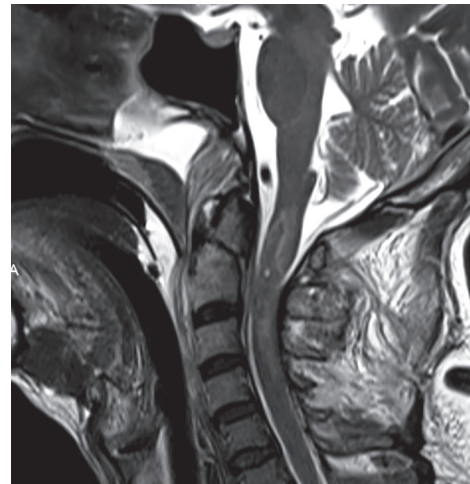


Fig. 1: Magnetic resonance imaging sagittal view showing type II odontoid fracture and cervical cord contusion at that level

present our experience in a case of odontoid fracture and high cervical cord injury probably the first of its kind performed in India in a trauma victim in 2013.

CASE

In 2013, an elderly man sustained a severe cervical spine injury following a fall of iron bar while downloading it from a vehicle and became a quadriplegic instantaneously. The gentleman was intubated, ventilated at a small regional setup, and referred for further management. Patient had type II odontoid and severe spinal cord contusion at the level C1 to C3 with grade 0/5 quadriplegia and no respiratory effort (Fig. 1). Ventral screw fixation of odontoid fracture was done and followed by tracheostomy and support management with ventilatory support. Attempts to wean the patient from ventilator failed and after 2 months it was decided to plan for ventilator-free management using phrenic nerve stimulation using a pacemaker.

Diaphragm electromyography and phrenic nerve conduction potential were assessed for their integrity, and bilateral phrenic nerve electrodes were secured at neck, and the battery connected and placed subcutaneously on the right side chest wall below the clavicle (Figs 2 and 3). Diaphragm muscle contraction was confirmed following battery stimulation with appropriate settings. Subsequently, the pacemaker was activated in the intensive care unit in the following days.

¹Neurosurgeon, ²Thoracic Surgeon, ³Anesthesiologist
⁴Neurologist, ⁵Critical Care Specialist

¹Department of Neurosurgery, Kovai Medical Center and Hospital, Coimbatore, Tamil Nadu India

²Department of Thoracic Surgery, Kovai Medical Center and Hospital, Coimbatore, Tamil Nadu India

³Department of Anesthesiology, Kovai Medical Center and Hospital, Coimbatore, Tamil Nadu India

⁴Department of Neurology, Kovai Medical Center and Hospital, Coimbatore, Tamil Nadu India

⁵Department of Critical care medicine, Kovai Medical Center and Hospital, Coimbatore, Tamil Nadu India

Corresponding Author: JKBC Parthiban, Neurosurgeon, Kovai Medical Center and Hospital, Coimbatore, Tamil Nadu India
e-mail: juttyparthiban@gmail.com

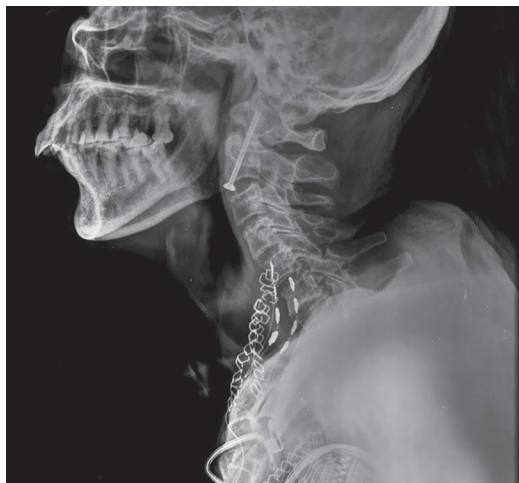

Fig. 2: X-ray cervical spine lateral view showing ventral screw fixation of odontoid fracture and the electrodes placed over cervical part of phrenic nerve



Fig. 3: X-ray cervical spine anteroposterior view showing the electrodes placed bilaterally over the phrenic nerves through a supraclavicular approach and the battery (pacemaker) on the right side below the clavicle

RESULTS

The diaphragm contraction was satisfactory and the patient was placed on noninvasive ventilation with intermittent ventilatory support. Total dependency on mechanical ventilation came down, and later few respiratory efforts made out. We were able to achieve ventilator-free period that varied between 4 and 12 hours on and off. However, patient suffered bowel perforation and underwent abdominal surgery once. 5 months following placement of pacemaker, patient developed a collection around the battery and also had urosepsis. Fluid aspiration did not reveal any obvious infection and the collection never subsided. Since the patient did not improve in sepsis, the battery was removed. Patient succumbed later. The comorbid status literally disturbed our aim to keep the patient on pacing in the hospital. Patient lived with pacemaker support for around 5 months between April and September 2013 with intermittent support from mechanical ventilation.

DISCUSSION

Indian spinal surgery has grown leaps and bounds and is now equal to any advanced spinal centers in the world. However, there is a large hiatus in overall management of spinal cord injury patients, especially in rehabilitation of these poor patients. Though various centers for rehabilitation are emerging, still we are not sufficient. Many surgeons and organizations are working hard and dedicating their time to develop state-of-the-art rehab centers for spinal cord injury patients. Gone are the days when we were contemplating on the medical and surgical treatment of cervical spine fractures and spinal cord injuries. We now know the art of fracture management and the value of medicines

used in preventing the secondary cascade of events that follow cord injury that include methyl prednisolone. Though there are skeptical views on its validity in clinical improvement, research works prove its benefit in spinal cords in lab. I have never seen a single area in medicine without a controversy. Once we discussed if should we operate on quadriplegic patients at all! On another day we debated on early decompression or late decompression! Then there were proanterior surgeons and proposterior surgeons! Ultimately many felt decompression may help in recovery. Leaving all these aside, we now are stuck with quadriplegics in ventilators and many are dependent without getting weaned out. Patients weaned out of ventilators have better quality of live in comparison and have less chance of getting ventilator-induced pulmonary infections and physical and social restrictions. The only way to wean them out is make the diaphragms contract and relax using some mode by stimulating the phrenic nerve or by directly stimulating the diaphragm at the neuromuscular junction site.

Phrenic nerve stimulation is not new and dates back to 1777. It was initially proposed by Cavallo¹ and later many worked on this to make the patients ventilator nondependence. Van Heekran and Glenn first introduced electrophrenic stimulation in 1966 in patients with Ondyne's curse.² Phrenic nerve stimulation can be done at the neck through a suprascapular approach either on single side or on both sides (as in our patient). The long distance between the electrode and muscle and technical challenges in anchoring the electrodes made this more difficult to maintain for long periods. There are so many literature reviews on this. Subsequently, further advancements were introduced to improve the results. The electrodes were then placed close to diaphragm through minimal access (thoracotomy) in

the thoracic region and recently further refinement has been done to place the electrodes directly over the muscle where phrenic nerve insertion is through a laparoscopic approach from abdominal side by motor mapping. These electrodes are better placed and are close to the muscle, which practically assure better discharge of electrical potentials for its contraction. The laparoscopic approach thus definitely alleviates the shortcomings faced in neck approach and in thoracotomy.

The incursion and excursion of diaphragm can be better monitored by fluoroscopy and sonography. The aim of diaphragm pacing in quadriplegic patients is to make them ventilator-free forever, though it may not be possible in all patients. Few may need intermittent support in terms of number of hours free of ventilator and also either in night or day depending on the need. The period of ventilator independence was classified as full time, part time, conditioning, and failure. Full time if the patient can tolerate pacing for 24 hours, part time if the patient can tolerate between 12 and 24 hours, conditioning if the patient can tolerate for 4 hours and improve subsequently, and failure if the patient cannot pace and cannot wean out of ventilator.³ Our patient was probably in conditioning period until the comorbidities prevented further improvement.

Phrenic nerve pacing needs an intact phrenic nerve and a healthy diaphragm for a good result.⁴ High cervical spine injury above C2 is ideal since diaphragm is supplied by C3, C4, C5 anterior horn cells, C4 in particular through phrenic nerve. Injury at C4 may lead to denervation of the nerve and hence, a poor conduction of electrical stimulus. Hence, a nerve conduction study of the phrenic nerve from neck to diaphragm must be done before implantation of the system. Electromyography of diaphragm is preferred and should confirm a good muscle. Paper thin muscles are not good ones for pacing. A well-trained neurophysiologist, specialist neurologist, intensivists, neurosurgeon, thoracic and endoscopic surgeon, and rehab therapists should be in the team in a well-equipped hospital.

Managing patients in a ventilator for a long period is a big challenge for physicians and involves significant socioeconomic limitations at least in India due to varied status of living condition. Christopher Reeve lived for nearly 9 years with best medical care in a developed country with lots of support. Many research activities were initiated in the management of spinal cord injury patients. Diaphragm pacing is one more step in providing a better quality of life to those quadriplegic patients dependent on ventilators. Very few centers in India have attempted in pacing the phrenic nerve and the diaphragm for various indications, including sleep apnea and amyotrophic lateral sclerosis.^{5,6} The high cost factor, availability of systems, and the long-term care of the patients in and out of the medical setup will be the real challenge in India apart from the acceptability factor of this scientific technique. Indian medical system is ready for diaphragm pacing and can provide quality care. However, awareness has to be created among medical professionals and the society as a whole.

REFERENCES

1. Taslim Uddin M, Saiful Islam M, Quamrul Islam M, Shariful Islam M. Breathing pacemaker in poliomyelitis – a case report. *IJPMR* 2003 Apr;14:1-4.
2. Elefteriades JA, Hogan JF, Handler A, Loke JS. Long-term follow-up of bilateral pacing of the diaphragm in quadriplegia. *N Engl J Med* 1992 May;326(221):1433-1434.
3. Alsheklee A, Onders RP, Syed TU, Elmo MJ, Katirji B. Phrenic nerve conduction studies in spinal cord injury: applications for diaphragm pacing. *Muscle Nerve* 2008 Dec;38(6):1546-1552.
4. Romero FJ, Gambarrutta C, Mazaria J, Marín MA, Diaz de la Lastra E, Paz F, Fernandez-Dorado MT, Mazaira J. Long term evaluation of phrenic nerve pacing for respiratory failure due to high cervical spinal cord injury. *Spinal Cord* 2012 Dec;50(12):895-898.
5. Garg N. Unilateral phrenic nerve stimulation for neurogenic hypoventilation in Arnold Chiari malformation. *IJNS* 2013 Sep-Dec;2(3):284-287.
6. Trivedi S, Tibrewala N, Balsara KP. Anaesthetic management of a patient with amyotrophic lateral sclerosis undergoing laparoscopic diaphragmatic pacing. *Indian J Anaesth* 2015 Oct;59(10):683-685.