

Intramedullary Spinal Ganglioglioma involving the Conus with Unusual Magnetic Resonance Imaging Features

¹BV Sandeep, ²Kaushik Roy, ³Suniti K Saha, ⁴Manpreet S Banga

ABSTRACT

Gangliogliomas are relatively rare primary tumors of the central nervous system (CNS). It may occur throughout the CNS, predominantly the supratentorial area. Spinal cord ganglioglioma is a very rare entity. Majority of spinal gangliogliomas occur in the cervical region followed by the thoracic region. The involvement of conus is the least common site of affection. Here we present a case of intramedullary ganglioglioma involving D10 to conus in a middle-aged female with uncommon magnetic resonance imaging findings.

Keywords: Conus lesions, Ganglioglioma, Spinal tumor.

How to cite this article: Sandeep BV, Roy K, Saha SK, Banga MS. Intramedullary Spinal Ganglioglioma involving the Conus with Unusual Magnetic Resonance Imaging Features. *J Spinal Surg* 2016;3(3):114-116.

Source of support: Nil

Conflict of interest: None

INTRODUCTION

Gangliogliomas are relatively rare primary tumors of the central nervous system (CNS) and are composed of a mixture of neoplastic mature neuronal elements (ganglion cells) and neoplastic glial elements, primarily astrocytic. It may occur throughout CNS, predominantly the supratentorial area. Spinal cord ganglioglioma is a very rare entity (1% of all intramedullary tumors),¹ and some authors have stated that the spinal cord is the least-affected site in the CNS, with only 1.1% of all spinal neoplasms being gangliogliomas.²⁻⁴ Children are more affected than adults.¹

A majority of spinal gangliogliomas occur in the cervical region followed by the thoracic region. The involvement of conus is the least common site of affection as per reported cases of literatures.⁵⁻⁷

Here we present a case of intramedullary ganglioglioma involving D10 to conus in a middle-aged female with uncommon magnetic resonance imaging (MRI) findings.

CASE REPORT

A 41-year-old diabetic housewife presented with back pain in the left lower limb for 2 years and developed sudden-onset weakness and numbness of both lower limbs including lower trunk followed by incontinence of stool with increased urinary urgency in the last 3 weeks. She was completely bed ridden since then and admitted in general medical ward at our hospital. Her bladder was catheterized. An MRI revealed an intramedullary lesion extending from the D10 to D12 level along with involvement of conus medullaris. The lesion was of mixed intensity in T1-weighted images (Fig. 1) and hyperintense on T2-weighted images except in the upper part (Fig. 2). Homogenous contrast enhancement was evident (Fig. 3). The patient was transferred to the neurosurgical ward. On examination, she had sensory level at D10 (all modalities including perianal region) with positive Beevor's sign and had asymmetrical spastic paraparesis (left lower limb was weaker than the right one). Proximal weakness was more than distal weakness.

D10 to D12 laminectomy with preservation of facets was performed. The dura was opened in the midline. The cord appeared dilated with overlying engorged tortuous pial vessels. The lower pole of the lesion was appearing at the cauda conus junction. During dissection under microscope, accidentally the tumor was punctured and the hemorrhagic fluid drained. After midline myelotomy at the D10 level, a dark red soft mass was detected. Despite a well-defined border, the tumor was adhesive

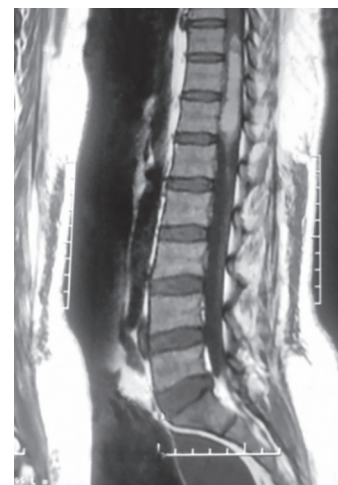

Fig. 1: T1-weighted MRI sagittal image

^{1,4}Resident, ²Associate Professor, ³Professor

¹⁻⁴Department of Neurosurgery, Nil Ratan Sircar Medical College and Hospital, Kolkata, West Bengal, India

Corresponding Author: Kaushik Roy, Associate Professor Department of Neurosurgery, Nil Ratan Sircar Medical College and Hospital, Kolkata, West Bengal, India, Phone: +919830317242 e-mail: dr.kaushik@rediffmail.com

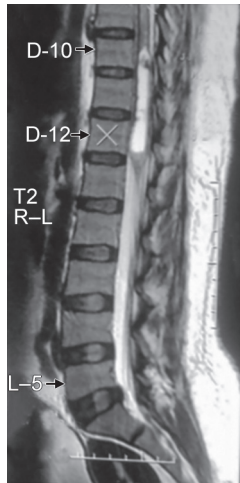


Fig. 2: T2-weighted MRI sagittal image

Fig. 3: T1 + contrast MRI sagittal image

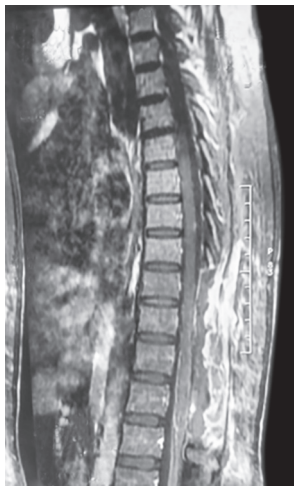

Fig. 4: Postoperative T1 + contrast MRI sagittal image

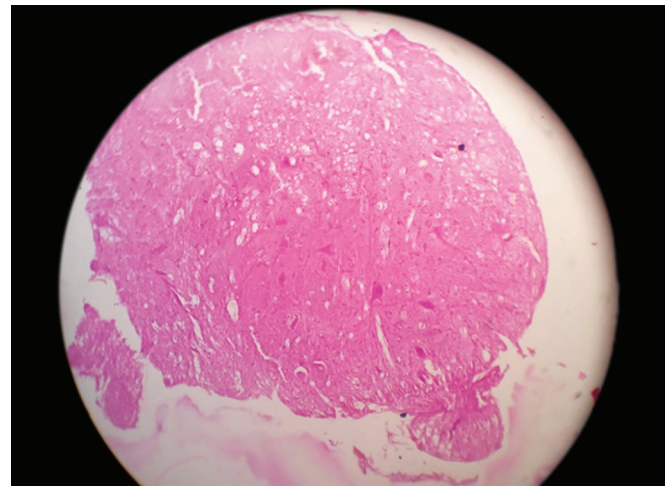


Fig. 5: Histopathological slide suggestive of ganglion cells and glial tissue

to the normal cord structure. Resection of grossly abnormal tissue was performed while taking care not to disrupt what appeared to be between hemorrhagic tumor tissue and more normal-appearing cord, specially at the level of the conus. The dura was closed without myeloplasty.

Postoperatively, the lower limb weakness became more severe specially at the left side (grade 2 and 3, respectively). The sphincteric problems were improved remarkably. A postoperative period was otherwise stable.

Postoperative MRI (plain + contrast) showed no residual tumor (Fig. 4). The histopathology report was in favor of ganglioglioma (Fig. 5). The patient did not tolerate steroids due to acute gastritis symptoms, and thus, steroid could not be given in the postoperative period.

DISCUSSION

Pick and Bielshowsky first introduced the term "ganglioglioma" in 1911. The term "ganglioglioma" was

proposed by Perkins in 1926 and adopted by Courville in 1930. Gangliogliomas are relatively benign, slowly growing tumors composed of mature ganglionic cells and nonganglionic glial elements. Lesions with non-neoplastic stroma, especially those composed of astrocytic cells, are termed "ganglioneuroma" or "gangliocytoma," whereas tumors comprising neoplastic astrocytes are designated "ganglioglioma." However, it is difficult to differentiate between gangliocytoma and ganglioglioma because the neoplastic evolution of the glial components varies from case to case and even in different areas of the same lesion.⁷

Ganglioglioma of the spinal cord are extremely rare. Zimmerman reported an incidence of 1.1% of all spinal cord tumors. The first successful removal of such a tumor was achieved by Kernohan et al in 1932.³

The most common site of ganglioglioma in the spinal cord is the cervical spinal cord, followed by the thoracic cord. The involvement of conus is the least.⁵ On reviewing the current available literature, out of

132 reported cases of gangliogliomas in the spinal cord, only 15 cases involved the conus. The most commonly occurring cases were in children, with a 1.7:1 male sex predilection.⁵ Our patient was a 41-year-old female.

Radiological characteristics are not pathogenomic.¹ Magnetic resonance imaging is the diagnostic modality of choice. A total of 84% are mixed intensities on T1-weighted images and 60% are homogenous in T2-weighted images. Contrast enhancement is usually patchy, and diffuse enhancement is only 4%.⁶ In our case, the lesion was of mixed intensity in T1-weighted images and hyperintense on T2-weighted images except in the upper part. Homogenous contrast enhancement was also evident.

Total surgical resection remains the standard treatment. Early surgical intervention has two main advantages: First, surgery with better functional status; second, easier resection due to the smaller size of tumor. Some argue that complete resection of tumor might not be feasible because no well-defined plane of cleavage could be identified. Hamburger et al believe that it carries a high morbidity rate even with microsurgical techniques.^{1,6} In our case, resection of grossly abnormal tissue was performed while taking care not to disrupt what appeared to be between hemorrhagic tumor tissue and more normal-appearing cord.

The extent of resection is the main factor to determine the outcome. Surgical outcome reports include recovery, no change in neurological deficit, and progression of neurological deficits. The recurrence is more in spinal ganglioglioma than the cerebral counterparts. A close follow-up is necessary. It is suggested that patients be seen every 6 months for 2 years postoperatively and annually thereafter.⁶

Routine radiotherapy is not suggested; however, no clinical trial exists.^{1,6} In our case, thus, radiotherapy was not advised.

The role of chemotherapy remains indefinite.^{5,6}

In recurrence, resurgery should be considered. However, radiotherapy might be another option. After the second surgery, adjuvant therapy should be considered.^{5,6}

CONCLUSION

Intramedullary spinal ganglioglioma is a rare entity, and its appearance in conus is very rare. Magnetic resonance imaging findings might be inconclusive. Some characteristics may help in differentiation and are useful in surgery. Complete resection is the standard treatment. The role of adjuvant therapy is controversial.

REFERENCES

1. Hamburger C, Buttner A, Weiss S. Ganglioglioma of the spinal cord: report of two rare and review of literature. *Neurosurgery* 1997 Dec;41(6):1410-1416.
2. Park SH, Chi JG, Cho BK, Wang KC. Spinal cord ganglioma in childhood. *Pathol Res Pract* 1993 Mar;189(2):189-196.
3. Kernohan JW, Woltman HW, Adson AW. Intramedullary tumours of the spinal cord. A review of fifty-one cases, with an attempt at histologic classification. *Arch Neurol Psychiat* 1931;25:679-699.
4. Kalyan-Raman UP, Olivero WC. Ganglioglioma: a correlative clinicopathological and radiological study of ten surgically treated cases with follow up. *Neurosurgery* 1987 Mar;20(3):428-433.
5. Jallo GI, Freed D, Epstein FJ. Spinal cord gangliogliomas: a review of 56 patients. *J Neurooncol* 2004 May;68(1):71-77.
6. Lotfinia I, Vahedi P. Intramedullary cervical spinal cord ganglioglioma, review of the literature and therapeutic controversies. *Spinal cord* 2009 Jan;47(1):87-90.
7. Kamikaseda K, Takaki T, Hikita T. Intramedullary ganglioglioma of spinal cord. *Neurol Med Chir (Tokyo)* 1989 Sep;29(9):838-841.