

Adjacent Corticocancellous Bone Graft in Anterior Cervical Interbody Fusion: A Technical Note

JKBC Parthiban

ABSTRACT

Autologous bone graft is the gold standard in cervical fusion. Obtaining autologous cancellous bone from adjacent vertebral body is unique and beneficial in anterior cervical interbody fusion. Sufficient amount of cancellous bone graft is curetted from adjacent cervical vertebral bodies and packed in the titanium cages placed in the intervertebral space. Cortical bone obtained from corticectomy and anterior osteophytes add to the volume along with cancellous bone. Fusion achieved is satisfactory and the technique obviates harvesting corticocancellous graft from iliac crest.

Keywords: Adjacent vertebral body, Cancellous bone, Cervical spine, Interbody fusion.

How to cite this article: Parthiban JKBC. Adjacent Corticocancellous Bone Graft in Anterior Cervical Interbody Fusion: A Technical Note. *J Spinal Surg* 2016;3(3):75-78.

Source of support: Nil

Conflict of interest: None

SURGICAL TECHNIQUE

After discectomy and cage (polyetheretherketone – PEEK or titanium) placement in the interbody space, adjacent corticocancellous bone grafting is performed. Anterior surface of adjacent vertebral bodies is inspected (Fig. 1), and using a sharp 5 mm osteotome the cortical bone is cut in a square fashion (Figs 2A and B). Usually, this corticectomy is done at the middle of the anterior vertebral surface and extended away from the fusion site. Cortical bones are collected and packed inside the cage (Fig. 3). Cancellous bone in the vertebral body is then curetted using small- and medium-sized forward angulated curettes (Fig. 4A). Good amount of rich cancellous bone with oozing blood is then transferred to the fusion site and packed in the cage (Figs 4B to D). Cancellous bone is harvested away from the fusion site in the vertebral

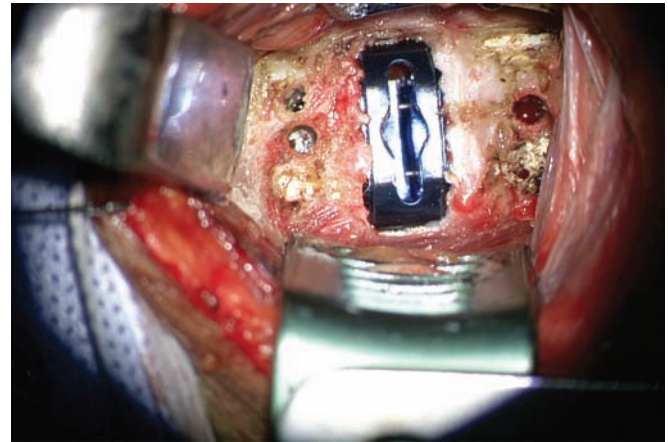
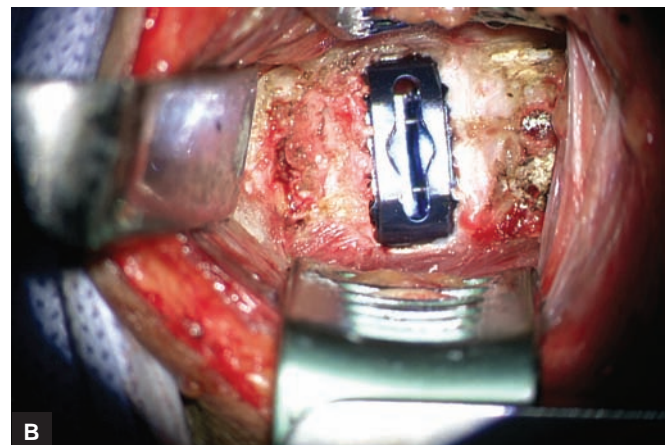
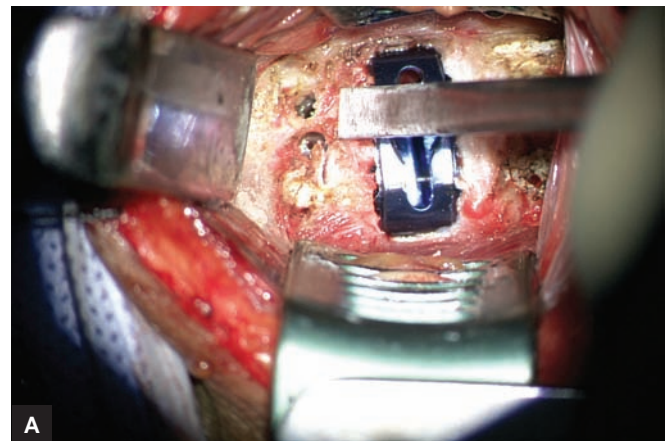


Fig. 1: Inspection of anterior surface of adjacent cervical vertebral bodies



Figs 2A and B: (A) Corticectomy with sharp osteotome; and (B) rectangular corticectomy

Senior Consultant Neurosurgeon

Department of Neurosurgery, Kovai Medical Center and Hospital, Coimbatore, Tamil Nadu, India

Corresponding Author: JKBC Parthiban, Senior Consultant Neurosurgeon, Department of Neurosurgery, Kovai Medical Center and Hospital, Coimbatore, Tamil Nadu, India, Phone: +919842223500, e-mail: juttyparthiban@gmail.com

field has led to the introduction of cages made up of PEEK and titanium that act as scaffolds in which osteogenic cancellous and cortical bones can be packed to achieve good fusion. Though bone substitutes are available, nothing can replace autologous bones. Anterior osteophytes and ossified endplates can provide sufficient cortical bones.

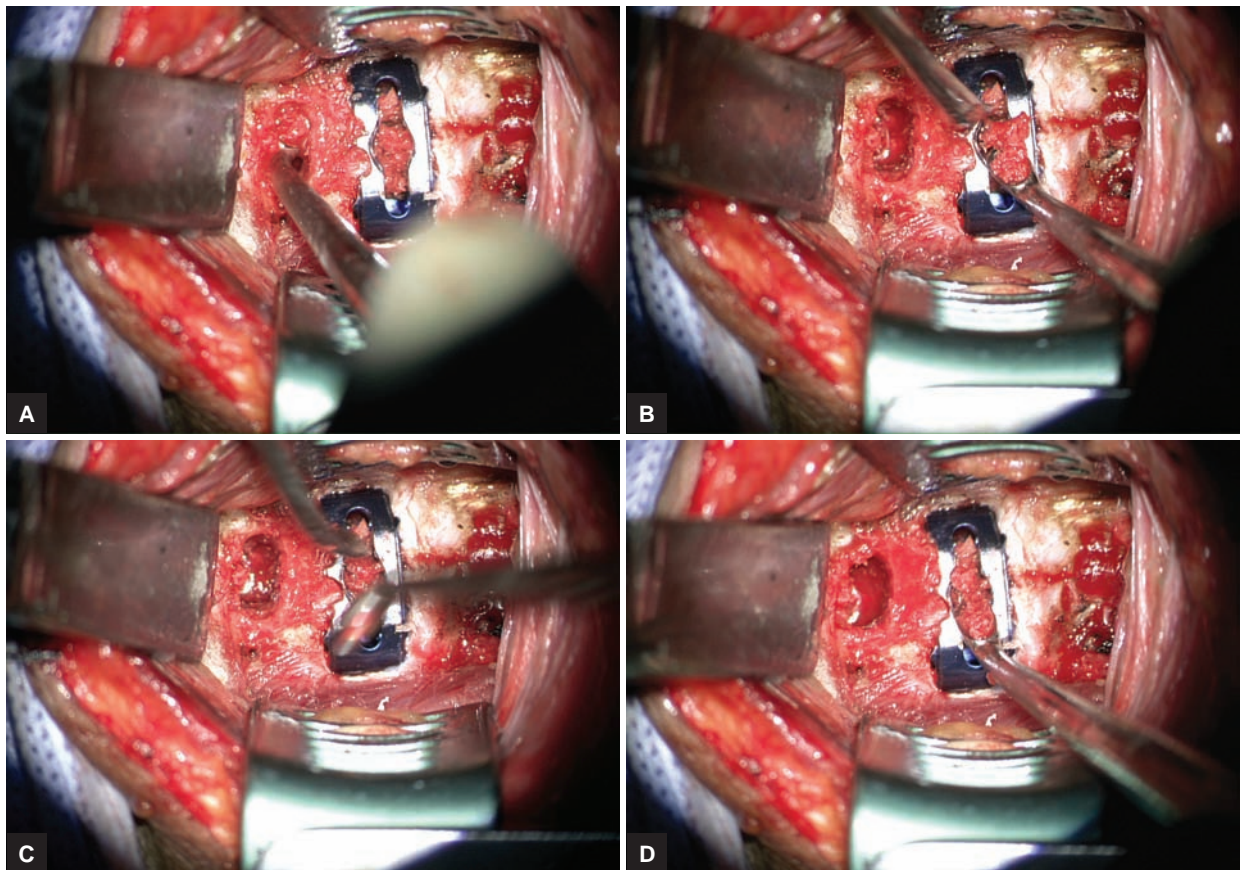
Cervical vertebral body has abundant cancellous bone, which has high osteogenic potential. This rich bone is not used regularly in anterior cervical discectomy and fusion. We emphasize its utility in such cases wherein the cages can be packed with rich cancellous bones harvested from adjacent vertebral bodies. This obviates the need for iliac crest harvesting and its complications. In our limited experience, we were satisfied with the technique and result. The cancellous bone curettage is avoided close to the disk space since fusion process starts at these ends. Removal of cancellous bone leaves an empty space in the vertebral body. Preoperative radiological assessment and peroperative inspection guide the surgeon in harvesting sufficient volume. Though this technique may not be possible in all cases, it can be useful in a majority of cases wherein the vertebral body contour is well intact.

Fig. 3: Cortical bone transferred to the cage

body, viz., toward cranial direction in upper vertebra and caudal direction in lower vertebra (Fig. 5). In this way, cancellous bones are harvested from both adjacent vertebral bodies in a single-level surgery (Figs 6A to D). Pieces of osteophytes and cortical end plates if available can be added for grafting (Figs 7A to D).

DISCUSSION

Tricortical iliac crest is the gold standard in anterior cervical interbody fusion.¹ However, evolution in this



Figs 4A to D: (A) Cancellous bone curettage; (B) cancellous bone transferred to the cage; (C) cancellous bone packing inside the cage; and (D) further packing of graft

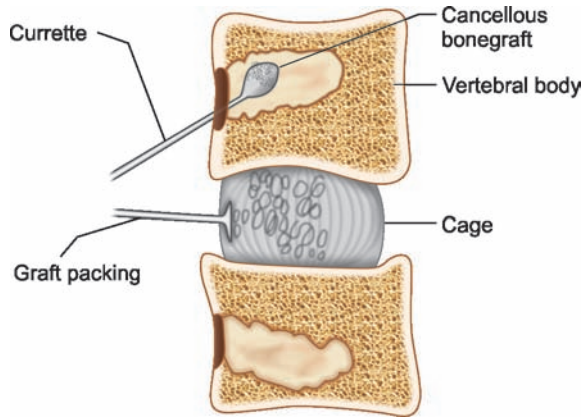


Fig. 5: Line diagram depicting the technique

In cases where the vertebral body height is very small as in severe degeneration and in osteoporotic spine, this technique is contraindicated. In one of our patients, we observed anterior vertebral collapse with no clinical significance. In this case, the anterior corticectomy was wide and the vertebral height was relatively small. This technique was also tried in two-level fusions.

There are a few questions that need to be answered in future, and we have our views on a few of them:

Q: Can a vertebral body with less cancellous bone maintain its height while fusion in this technique?

A: Yes, it does maintain its height and fusion is well appreciated. Since we preserve the endplates, we hardly encounter collapse at the fusion site. When anterior corticectomy is minimum, anterior wall collapse does not occur.

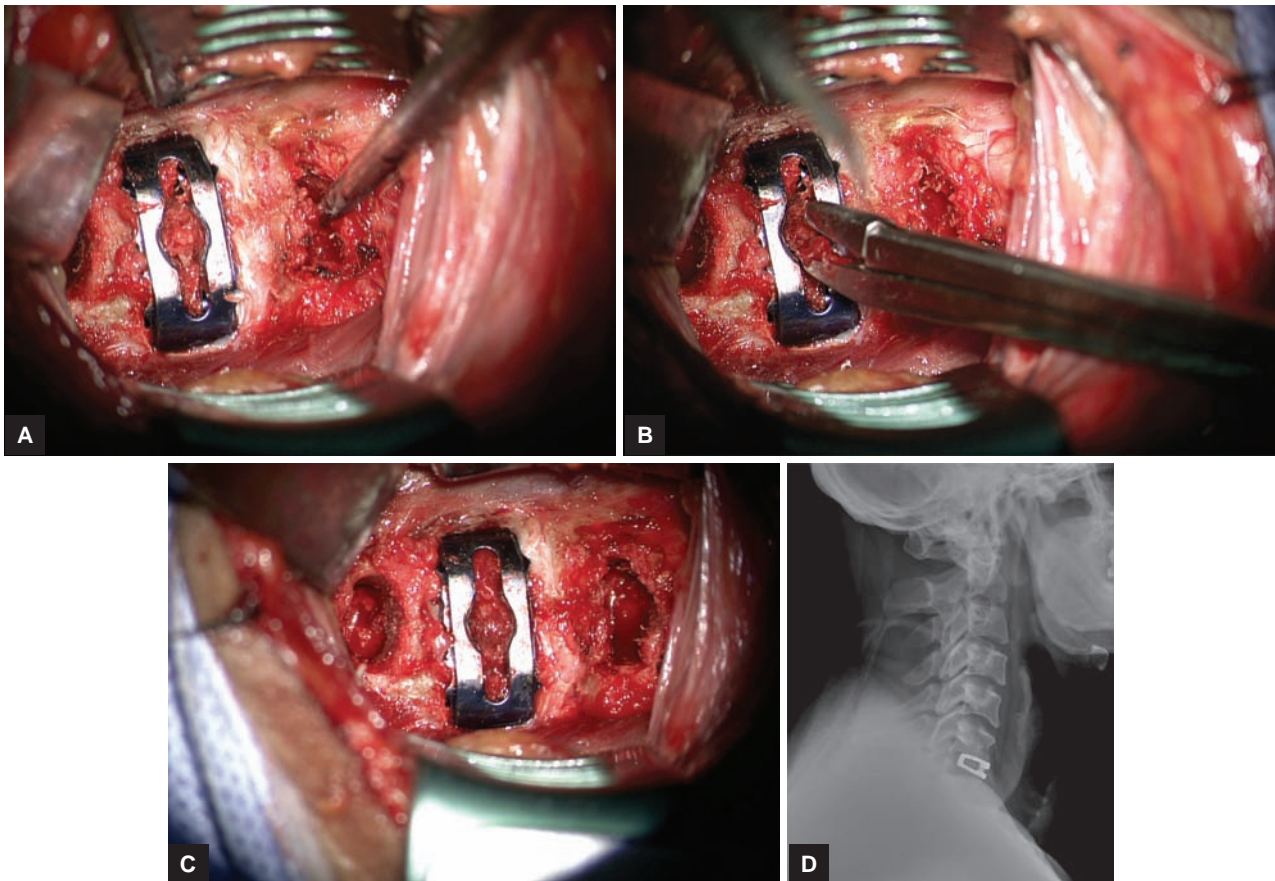
Q: What will happen if cancellous bone is completely removed leaving the shell of cortical bone?

A: This needs to be studied, and we have no answer since we never scooped out entire cancellous bone so far. However, there are few reports of oblique corpectomies without interbody fusions in the literature.²

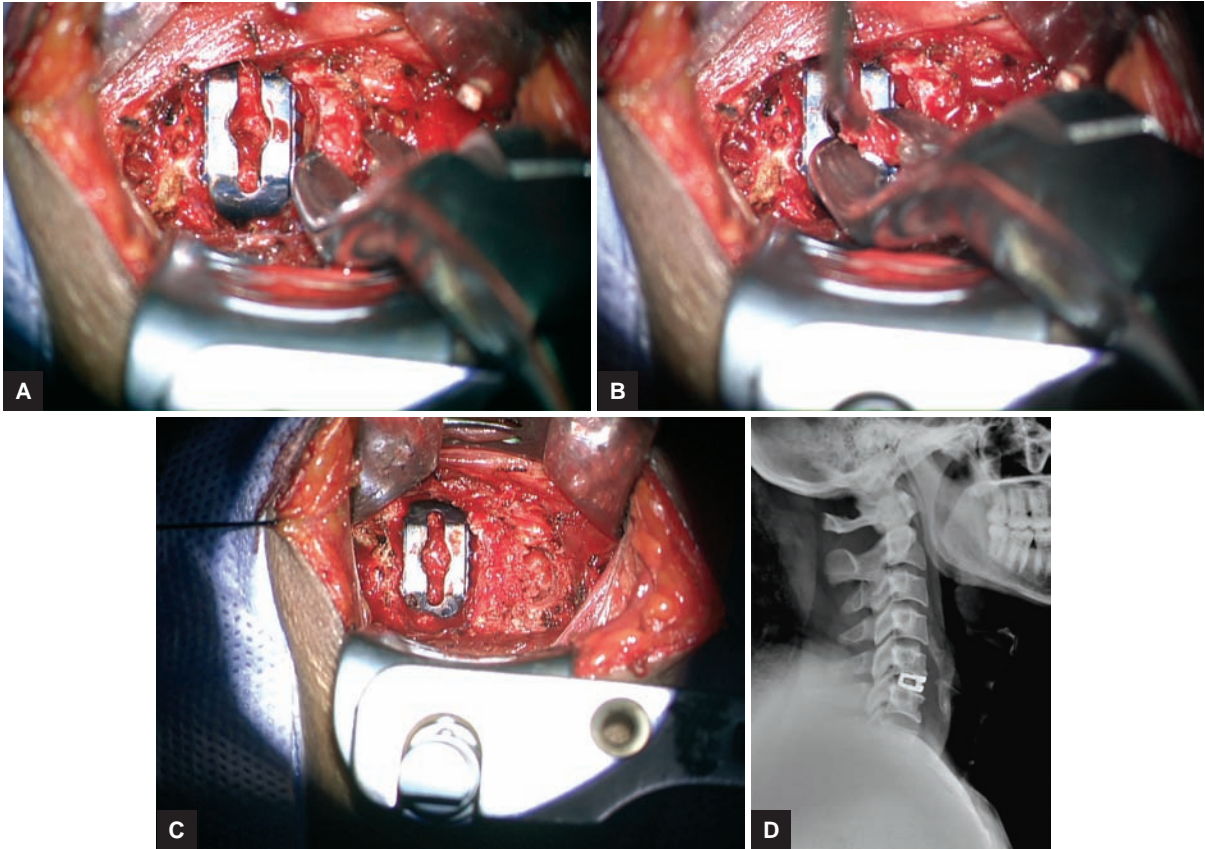
Q: In case of collapse, does all these cases end up in kyphosis? Is radiological collapse a real concern in practice?

A: Not sure of kyphosis. Need long-term follow-up with large series of cases studied. Too early to comment on this. However, in our observations in two-level cases, no such incidence has been observed so far.

Radiological collapse without clinical symptoms is not a concern in practice.



Figs 6A to D: (A) Cancellous bone curettage from inferior vertebral body; (B) cancellous bone from inferior vertebral body is transferred to cage; (C) completion of interbody fusion. Notice the site of harvest; and (D) postoperative X-ray lateral view showing the cage, cancellous bone within the cage, and the site of harvest



Figs 7A to D: (A) Anterior osteophyte nibbled; (B) anterior osteophyte bone transferred to cage; (C) completion of interbody fusion along with osteophyte; and (D) postoperative X-ray lateral view showing the cage, cancellous bone within the cage, the site of harvest, and excised anterior osteophyte

REFERENCES

1. Parthiban JKBC. Use of autograft for interbody fusion following anterior cervical discectomy. In: Ramani, PS.; Shoda M.; Zileli M.; Dohrmann GJ., editors. Surgical management of cervical disc herniation. New Delhi: Jaypee Brothers Medical Publishers (P) Ltd; 2012. p. 84-90.
2. Roochi G, Caroli E, Salvati M, Delfini R. Multilevel oblique corpectomy without fusion: our experience in 48 patients. Spine 2005 Sep 1;30(17):1963-1969.