

Spontaneous Spinal Epidural Hemorrhage causing Paraplegia

¹Maneet Gill, ²Vikas Maheshwari, ³Chinmaya Srivastava, ⁴Amit Narang

Spontaneous spinal epidural hemorrhage (SSEH) is a rare entity and mostly the etiology remains unidentified. Its prevalence is 0.1 per 100,000.¹ Trauma is the most common cause. The nontraumatic causes include anticoagulation therapy, vascular arteriovenous (AV) malformations, or history of previous spinal surgeries. The first case was reported by Jackson in 1869.² The presentation of SSEH can vary from a simple backache to myeloradiculopathy to acute paraplegia.

We report a 29-year-old male who presented with insidious onset dull aching interscapular pain followed by sudden onset of paraplegia with urinary retention of 1-day duration. The pain was nonradiating and worsened on coughing. There was no history of trauma, fever, weight loss, or any other chronic illness. The patient was not on any anticoagulants. Examination showed complete paraplegia with decreased sensation of all modalities below D4 dermatome. An urgent magnetic resonance imaging (MRI) of DL Spine showed isointens on T1, hypointense on T2, and noncontrast-enhancing extradural lesion at D3-D4 with cord compression suggestive of hematoma (Figs 1A to D and 2A). His coagulation, biochemical, and hematological parameters were within normal limit.

The patient was taken up for emergency surgery. He underwent laminectomy of D3-D4 vertebra and hematoma was completely evacuated. There was no active bleeder, AV malformation, or any intradural extension of hematoma (Fig. 2B). Postoperatively, patient showed steady recovery with power 3/5 in both lower limbs at 2 weeks, which further improved to 4/5 at 3 months. Postoperative MRI showed complete evacuation with no residual lesion or cord compression (Fig. 2C). Postoperative spinal digital subtraction angiography showed no evidence of AV malformation. His coagulation profile was within normal limits.

A spontaneous spinal epidural hematoma is a rare but severely disabling disease. Its incidence is about 0.3 to 0.9% of all spinal epidural space-occupying lesions.³ The factors incriminated are anticoagulant therapy, thrombolysis in acute myocardial infarction, hemophilia B, factor XI deficiency, long-term use of aspirin, vascular malformation, hemodialysis, and pregnancy. The most frequent age of onset for SSEH is after the fourth or fifth decade.³ The male:female ratio is 1.4:1.² Our case was a young adult male.

The clinical presentation in most of the cases is the same as in our case, i.e., sudden-onset back pain followed by signs of nerve root or spinal cord compression. The clinical features of spinal cord compression may include ascending numbness, progressive paraplegia and/or loss of sensory function in lower limbs, and cauda equina syndrome. The later symptoms were present in our case too.

The accepted hypothesis is that SSEH is of venous origin. The epidural veins are valveless and are situated in the low-pressure epidural space. These veins are relatively unprotected from sudden increases in intrathoracic or intra-abdominal pressure as occurs in coughing, sneezing, and Valsalva maneuver leading to rupture and hemorrhage. This epidural venous plexus is most prominent in the thoracic spine. This SSEH may spread over a few vertebral bodies and is most often located in the thoracic and cervicothoracic region followed by the thoracolumbar region. The SSEH is usually located in the posterior or posterolateral epidural space.⁴ Several authors have however, incriminated spinal epidural arteries as the source of hemorrhage. It is difficult to identify the cause accurately because, in most cases, the preoperative or postoperative angiographic analysis is not available. Even intraoperative findings also do not help in confirming the cause of SSEH.

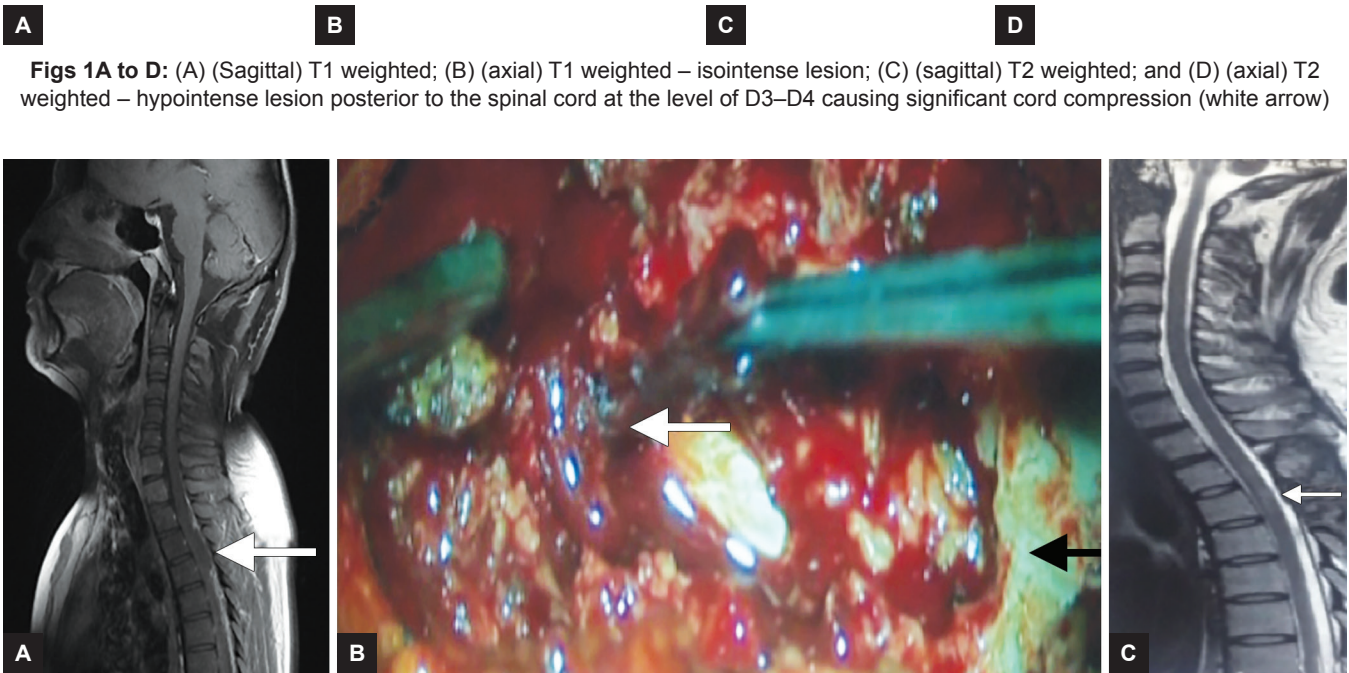
Magnetic resonance imaging spine is the initial diagnostic modality for SSEH. Magnetic resonance imaging is noninvasive, can localize the lesion, and shows compression and effects on the spinal cord.²

An SSEH is a surgical emergency, the aim of treatment is quick decompression and evacuation of hematoma. Conservative treatment is an option in some patients who

^{1,2}Professor, ^{3,4}Resident

¹⁻⁴Department of Neurosurgery, Armed Forces Medical College Pune, Maharashtra, India

Corresponding Author: Maneet Gill, Professor, Department of Neurosurgery, Armed Forces Medical College, Pune Maharashtra, India, Phone: +917028050776, e-mail: maneet5@yahoo.com



Figs 1A to D: (A) (Sagittal) T1 weighted; (B) (axial) T1 weighted – isointense lesion; (C) (sagittal) T2 weighted; and (D) (axial) T2 weighted – hypointense lesion posterior to the spinal cord at the level of D3–D4 causing significant cord compression (white arrow)

Figs 2A to C: (A) Contrast MRI – (sagittal) nonenhancing lesion at the level of DV3-DV4 causing significant cord compression; (B) intraoperative interface between cord and clot appreciated at the level of DV3-DV4 (white arrow), Lamina of DV5 (black arrow); and (C) postoperative MRI T2 (sagittal) after six weeks no lesion seen at DV3-DV4 level

have mild compression and show spontaneous recovery while on strict monitoring. It could also be considered in high-risk patients with bleeding tendency, associated with severe systemic disease, advanced cardiovascular disease, and advanced or irreversible spinal cord injury. Literature reviews suggest that prognosis depends on the preoperative neurological deficit, the time between the onset of symptoms and surgical decompression. The most relevant aspect of this case report is an early surgical management. This factor may have been the key determinant of the good neurologic outcome in our case. The proposed best therapeutic window is less than 12 hours from the initial ictus.² Groen et al⁴ concluded that patients with complete preoperative sensorimotor loss have high chances of persistent neurological deficits even after surgical decompression. Other authors described similar results in smaller case series.² However, in our case, the preoperative power was MRC 0/5, improved to 3/5 2 weeks postoperative and 4/5 at the end of 3 months. Now the patient is ambulant with the support of elbow crutch.

A spontaneous spinal epidural hematoma is an uncommon disease presenting with either back pain or radicular pain. An early diagnosis and surgical decompression are imperative, especially in cases with impending neurological deficit. In our case, despite a thorough investigation, there was no obvious underlying cause for his extradural hematoma.

REFERENCES

1. Mohammed N, Shahid M, Haque M, Qureshi M, Hoey ET. Spontaneous spinal epidural haematoma mimicking acute coronary syndrome. *Quant Imaging Med Surg* 2015 Dec;5(6): 925-927.
2. Tiryaki M, Basaran R, Aydin SO, Efendioglu M, Balkuv E, Balak N. Spontaneous cervical epidural hematoma with hemiparesis mimicking cerebral stroke. *Case Rep Emerg Med* 2014;2014:1-3.
3. Coulibaly O, Habibou L, Régis OT, El Fatemi N, Gana R, Maaqili R, Jiddane M, Bellakhdar F. Spontaneous spinal epidural hematoma causing paraplegia: a case report. *World J Neurosci* 2015;5(4):270-274.
4. Groen RJ, van Alphen HA. Operative treatment of spontaneous spinal epidural hematomas: a study of the factors determining postoperative outcome. *Neurosurgery* 1996 Sep;39(3):494-508.