

Ongoing Efficacy of Platelet-rich Plasma vs Corticosteroid Injection in Patients with Adhesive Capsulitis: A Prospective Randomized Assessor-blind Comparative Analysis

Sachin Upadhyay¹, Kailash Jorule², Hashmukh S Varma³, Mayank Chansoria⁴

ABSTRACT

Introduction: The primary objective of the present study was to assess the safety and efficacy of platelet-rich plasma (PRP) injections for management of adhesive capsulitis and compare the clinical outcome with injection of corticosteroid.

Materials and methods: A total of 120 patients were randomized into PRP (group I) or steroid (group II) group. Patients were assigned to receive a single injection of 1% lidocaine with either methylprednisolone (steroid) or PRP. All patients were assessed at 1, 3, and 6 months after the index procedure. The shoulder pain and disability index (SPADI) was used to evaluate the clinical results. Data were analyzed with a paired *t* test. The level of significance was considered as *p* < 0.05.

Results: The efficiency of PRP injection was better and sustained than steroid. In PRP group, mean pain scale, mean disability, and total SPADI scores were almost linearly improved, while the scores increased to a higher level at the final follow-up visit compared with that post 1 and 3 months in the steroid group (*p* < 0.05). No major adverse complications were noted.

Conclusion: In the current randomized, single-center, prospective preliminary study, results indicate that treating adhesive capsulitis with PRP injections is safe and has the potential to reduce pain and improve the functional outcome. The PRP injection had a more prolonged efficiency than steroid injections.

Clinical significance: The PRP injections are safe and valuable therapeutic modality to alleviate the symptoms in subjects with adhesive capsulitis of shoulder.

Keywords: Adhesive capsulitis, Corticosteroid, Platelet-rich plasma, Shoulder pain and disability index.

Journal on Recent Advances in Pain (2020): 10.5005/jp-journals-10046-0160

INTRODUCTION

Adhesive capsulitis or arthrofibrosis is a poorly understood self-limiting musculoskeletal disorder in which the body forms excessive scar tissue or adhesions across the shoulder joint, leading to pain, progressive stiffness, and dysfunction that can cause significant morbidity.¹ In 1934, to emphasize this debilitating significant restriction in active and passive range of motion (ROM) of shoulder joint, Earnest Codman coined the term "frozen shoulder."¹ In view of histological findings in 1945, Neviaser redefined "frozen shoulder" as adhesive capsulitis owing to inflammatory as well as fibrotic process.² Though contracture of the joint capsule is the pathognomonic of adhesive capsulitis, there is still no consensus in the available literature as to whether inflammatory changes are part of the pathophysiology or underlying fibrosis forms the basis of the histology of adhesive capsulitis. Despite the available literature on adhesive capsulitis, there is no universal treatment algorithm on management of frozen shoulder. Treatment varies greatly from pharmacology, physical therapy, to less invasive intralesional injections to more invasive open capsulotomy.¹ The majority of patients will respond to conservative management such as nonsteroidal anti-inflammatory drugs (NSAIDs) and physical therapy; however, failure to respond to these will require invasive modalities including corticosteroid injections and at times surgery may be necessary. Nonsteroidal anti-inflammatory drugs are the first line of treatment but lacks substantial evidence in support of the use of these anti-inflammatories in adhesive capsulitis as they

¹⁻³Department of Orthopaedics, Netaji Subhash Chandra Bose Medical College, Jabalpur, Madhya Pradesh, India

⁴Department of Anaesthesiology, Netaji Subhash Chandra Bose Medical College, Jabalpur, Madhya Pradesh, India

Corresponding Author: Sachin Upadhyay, Department of Orthopaedics, Netaji Subhash Chandra Bose Medical College, Jabalpur, Madhya Pradesh, India, Phone: +91 9329078849, e-mail: drsachinupadhyay@gmail.com

How to cite this article: Upadhyay S, Jorule K, Varma HS, *et al.* Ongoing Efficacy of Platelet-rich Plasma vs Corticosteroid Injection in Patients with Adhesive Capsulitis: A Prospective Randomized Assessor-blind Comparative Analysis. *J Recent Adv Pain* 2020;6(1):10–16.

Source of support: Nil

Conflict of interest: None

cannot change the natural history of the pathology.³ Glenohumeral or subacromial corticosteroid injections are the established second-line modality but associated with short-term benefit.^{4,5} Platelet-rich plasma (PRP) an autologous blood product may be a suitable substitute to corticosteroid in frozen shoulder with sustained and prolonged efficacy; however, there are very limited available published data.⁶⁻⁹ In view of these critical concerns, we have designed this prospective randomized assessor-blind research in order to investigate the clinical efficacy and safety of PRP injection in the treatment of the painful stiff shoulder and to compare its effect with that of corticosteroid.

MATERIALS AND METHODS

The current prospective randomized comparative research was conducted at NSCB Medical College, Jabalpur, in the Department of Orthopaedics, Traumatology and Rehabilitation. The present study was approved by our institutional review board, and all patients have consented to participate in the present research. Between September 2014 and September 2015, a total of 140 patients with diagnosis of idiopathic adhesive capsulitis of the shoulder were screened in the outpatient department of our institution. The subjects included 75 shoulders of women and 65 shoulders of men with a mean age of 47.35 years (range, 35–70 years). The diagnosis was established on the basis of clinical presentation, medical history, and X-ray imaging. Of 140 patients with shoulder pain screened, 9 failed the study selection criteria. The excluded patients consist of five refused to participate, three with history of injection with steroid within 3 months, and one with acute shoulder pain. One hundred thirty-one patients fulfilled the study selection criteria and were recruited for the study (Flowchart 1).

Inclusion and Exclusion Criteria

Adult of either sex with unilateral shoulder pain and limitation of both active and passive movements of the glenohumeral joints in at least two directions (abduction, flexion, external rotation, and internal rotation) for more than a month (but less than a year), i.e., stage I and stage II with normal radiograph were stringent inclusion criteria.

The exclusion criteria were (1) frozen shoulder stage III; (2) any history of previous shoulder surgery; (3) any history of trauma to the shoulder joint (last 6 months) or secondary adhesive

capsulitis; (4) rotator cuff tear or history of recurrent dislocation; (5) cardiovascular disease (history of myocardial infarction or angina pectoris); (6) any history of coagulopathies (platelet counts of $<150,000/\text{mm}^3$); (7) cerebral vascular disease (history of episode of stroke); (8) active infection; (9) active inflammatory or connective tissue disease (i.e., lupus and rheumatoid arthritis); (10) uncontrolled diabetes, hypersensitivity to NSAIDs, abnormal liver or kidney profile, history of peptic ulceration and upper gastrointestinal hemorrhage, cancer, and hyperkalemia; (11) pregnancy; and (12) and/or any other conditions that, in the opinion of authors, would affect the compliance or could potentially limit the protocol-specified functional evaluation.

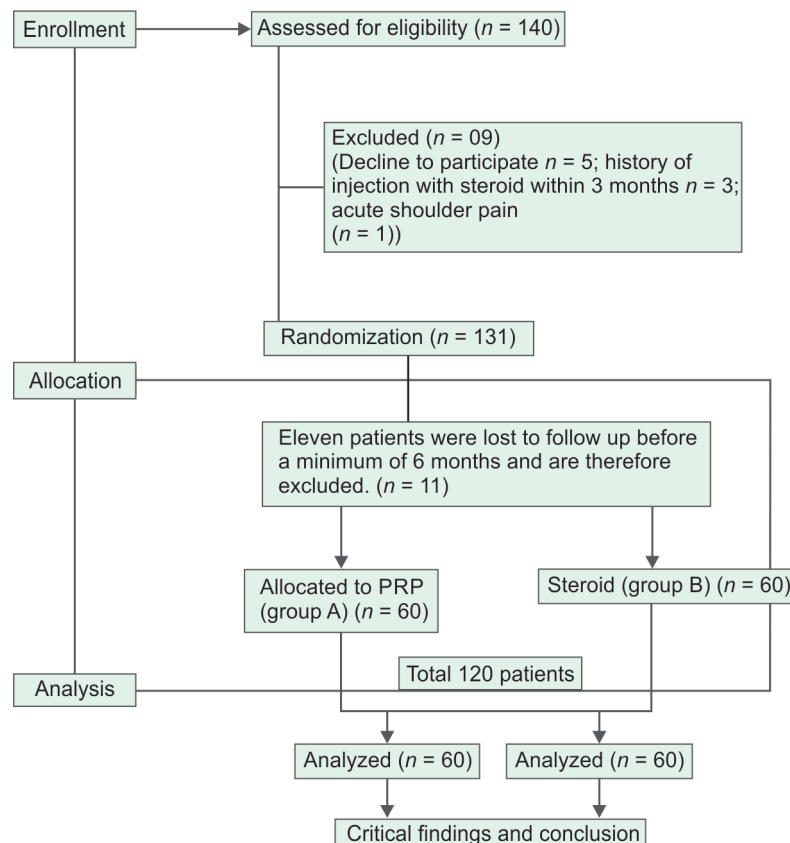
Methodology

The study was designed as prospective, randomized, blinded, single-center clinical comparative research. The consort flowchart for the study is shown in Flowchart 1.

Randomization

Randomization of cohort was done by a computer-generated list of random number prepared by an investigator with no clinical participation in the present analysis. Subjects with odd number were allocated to group I (PRP), and those with even number were enrolled to group II (steroid). Subjects allocated under group I were received single injection of 2 mL of PRP, and those enrolled under group II were received single injection of 40 mg/mL of methylprednisolone. Study was designed 1:1 case-control study. The outcome assessor was kept blind to the group allocation of the participants.

Flowchart 1: Consort flowchart



Device Description

The present research employed a 6 × 15, swing out REMI centrifuge C-854/6 clinical centrifuge (Fig. 1).

Preparation of PRP

A differential centrifugation technique at blood bank was used to prepare PRP. Under aseptic precautions, 15 mL venous blood was collected from mid-cubital vein in a sterile disposable test tube preprepared with anticoagulation ethylenediaminetetraacetic acid (Fig. 2). This sterile disposable tube was centrifuged at 22–24° room temperatures at 1500 rpm/minute for 15 minutes. Following this spin, the whole blood sample was fractionated into (from bottom to top of the tube; Fig. 3) bottom or red cell layer; intermediated or whitish opaque thin layer of buffy coat which contains osteoprogenitor cells, mononuclear cells, some platelets, and high concentration of leukocytes; and the top one is yellowish transparent supernatant plasma layer that contains mostly platelets.¹⁰ This top layer has two zones: upper platelet-poor plasma and lower PRP (Fig. 3).¹¹ Platelet-poor plasma layer was discarded and approximately 2 mL of PRP was collected for injection (Fig. 4). Just before infiltrating into the site, a few drops of 10% calcium chloride were added to PRP.

Intervention

The procedure was executed through anterior approach in sitting posture with the arm resting comfortably at the side, and the shoulder externally rotated. Desired marking was done and site just medial to the head of humerus and 1 cm inferior and lateral to the coracoid process was the portal of entry (Fig. 5). The whole procedure was carried out by a single physician under aseptic precautions and done under fluoroscopy, and 1% lidocaine (Xylocaine) 2–3 mL of local anesthesia was delivered intra-articularly through the entry point, and a gentle thumb massage was applied for 30 seconds over the zone of injection. Gentle passive mobilization was done in all the directions once adequate local anesthesia was confirmed by the patient. Adequate local anesthesia is critical to the success of the procedure. Dry needling, also known as peppering, is used to locally “injure” the soft tissue to excite the inflammatory response.¹¹ Marked entry point was penetrated with a 22-gauge needle until the underlying cartilage/bone was touched. A stringy, crunchy consistency was palpably noted as the needle was advanced. After contacting the hard bony surface, the needle was withdrawn slightly and then advanced in a fan-like pattern, peppering the site 8–10 times, simultaneously injecting 0.2–0.3 mL of either PRP or steroid as this peppering maneuver is continued.



Fig. 1: Centrifugation at room temperature at 1,500 rpm/minute for 15 minutes in a REMI centrifuge C-854/6 System

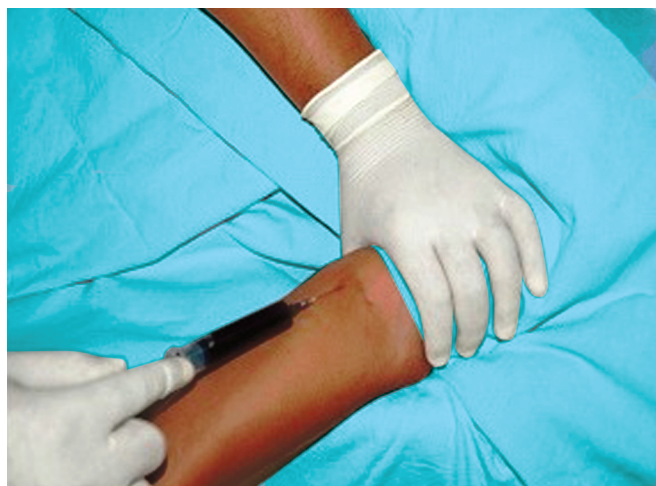

Fig. 2: Collection of patients own blood from mid cubital vein

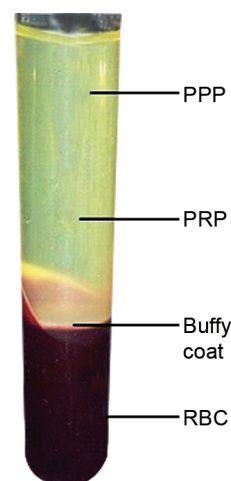


Fig. 3: Centrifuged tube with three layers of blood components: RBS, red blood corpuscles; Buffy coat; PRP, platelet rich plasma; PPP, platelet poor plasma

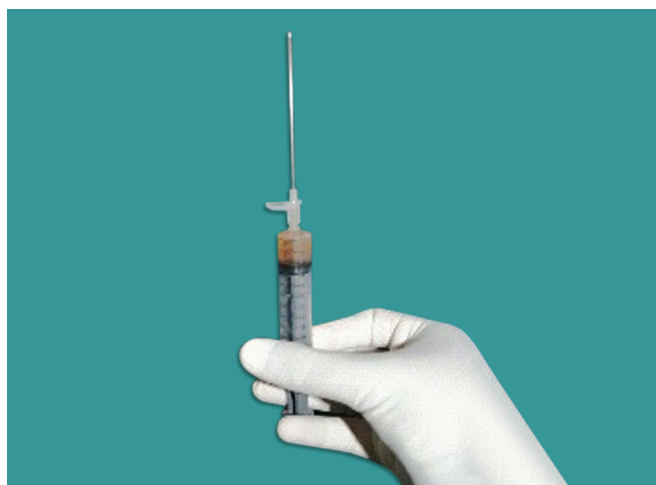


Fig. 4: Platelet-rich plasma approximately 2 mL collected in a syringe

Passive mobilization was done for 5–6 minutes in all possible directions. A total of 0.5 mL of the PRP is injected.

Postinjection Protocol

After injection, subjects were sent home and were instructed to limit exertional activities for at least 1 week postprocedure. The patients were advised broad spectrum oral antibiotics for 3 days postinjection and simple NSAIDs like PCM 500 mg 'Si Opus Sit' (SOS, which means 'if needed') if intolerable pain. Cold compress for initial 1–2 days followed by physical therapy and hot fomentation at least twice a day. All patients (groups I and II) were taught a 15-minute exercise therapy plan comprising of pendulum exercise, stretching, active assisted, and active ROM exercises for shoulder movements.

Criteria for Evaluation of Outcome

Improvement in pain and disability using shoulder pain and disability index (SPADI) were the main outcome measures. All the patients were followed up routinely at 1, 3, and 6 months by the blinded outcome assessor. All participants were instructed not to disclose any details about their injection treatment to the assessor. Patients were encouraged to report any adverse event/reaction to the physician at each follow-up visit.

Statistical Analysis

All the records were rechecked for their completeness and consistencies. Illogical entries were resolved before analysis. Nonnumeric entries were coded numerically into nominal/ordinal distribution before analysis. Categorical variables were summarized in frequency and percent distribution, and Chi-square or Fisher's exact test was performed as appropriate. Continuous variables were analyzed using mean \pm standard deviation (SD) or median with interquartile range as appropriate. Mean difference between two independent groups and two observations on the same subject were analyzed by using independent *t* test and paired *t* test, respectively, after normalized the distribution otherwise nonparametric test was applied. To test the null hypothesis, 0.05 α and 95% confidence limit was applied. The values of *p* less than 0.05 were considered significant.

RESULTS

One hundred thirty-one patients fulfilled the study selection criteria and were recruited for the study. All underwent the process of

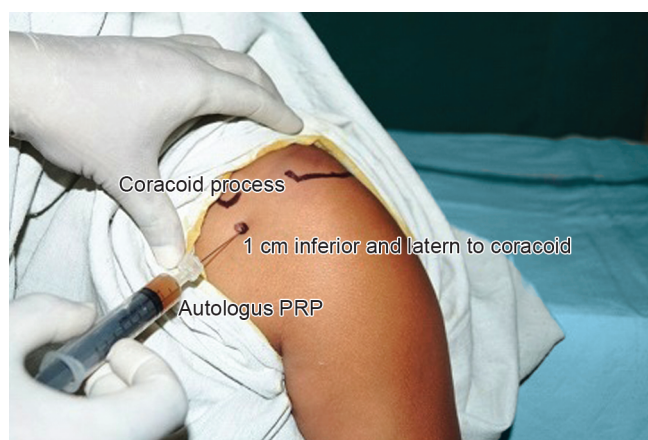

Fig. 5: Injection of platelet-rich plasma through entry point marked in anterior approach to shoulder joint

Table 1: Baseline clinical and demographic characteristics of each group

Characteristic	Group PRP (n = 60)	Group steroid (n = 60)	<i>p</i> value
Age (years)	47.6	46.4	>0.05
Sex (males/females)	25/35	25/35	>0.05
Side (nondominant/dominant)	33/27	34/26	>0.05
Stage (I/II)	30/30	28/32	>0.05
Comorbidity	Nil	Nil	
Occupation (heavy work/light work)	45/15	42/18	>0.05
Preinjection pain (mean pain scale: SPADI)	21.00	20.48	>0.05
Preinjection disability (mean disability scale)	43.20	42.13	>0.05

randomization and intervention. Eleven patients (11 shoulders) were lost to follow-up before a minimum of 6 months and are therefore excluded. The remaining 120 patients [120 shoulders; 70 females (59%); 50 males (41%)] were followed up for 6 months after the procedure. Nondominant shoulder was involved in 67 patients (56%) and dominant shoulder in 53 patients (44%). Fifty-eight patients (48%) were in stage I and 62 patients (52%) were in stage II of frozen shoulder. The two groups were not significantly different with regard to demographic variables ($p < 0.05$). Baseline parameters showed no difference between the groups ($p > 0.05$) (Table 1). Mean pain scale and mean disability scale in group I showed statistically significant improvements at follow-up visits (Table 2). Patients in steroid group showed positive trends in mean pain scale and mean disability scale at 1 and 3 months but increased to a higher level at the final follow-up visit compared with those post 3 months (Table 3). For patients in the PRP group, mean pain scale and mean disability scores almost linearly improved, while the scores increased to a higher level at the final follow-up visit compared with those post 1 and 3 months in the steroid group (Tables 4 and 5). The SPADI score after the injection improved at 1, 3, and 6 months in both groups, but the patient treated with PRP showed statistically significant improvement ($p < 0.05$) at 6 months of follow-up. Group I patients showed statistically significantly greater improvement in the SPADI at 1, 3, and 6 months when compared with the baseline parameters ($p < 0.05$) [Bp: 64.2 + 12.93 (49.38%) reduced to F1: 19.97 + 9.52 (15.36%) to F3: 8.73 + 4.66 (6.72%) to F6: 3.55 + 3.49 (2.73%)] (Table 6). Patients in group II

Table 2: Evaluation of outcome in platelet-rich plasma group I

Group I	Preinjection to 1-month follow-up F1	Preinjection to 3-month follow-up F3	Preinjection to 6-month follow-up F6
Pain scale, mean (SD)	6.77 (3.23)	2.97 (1.83)	1.35 (1.44)
p value	<0.05	<0.05	<0.05
Disability scale, mean (SD)	13.20 (7.32)	5.77 (3.28)	2.20 (2.25)
p value	<0.05	<0.05	<0.05

Table 3: Evaluation of outcome in steroid group II

Group II	Preinjection to 1-month follow-up F1	Preinjection to 3-month follow-up F3	Preinjection to 6-month follow-up F6
Pain scale, mean (SD)	9.82 (5.86)	7.50 (5.63)	14.68 (5.5)
p value	<0.05	<0.05	>0.05
Disability scale, mean (SD)	21.70 (11.19)	14.23 (10.60)	18.02 (14.13)
p value	<0.05	<0.05	>0.05

Table 4: Between-group comparison of mean pain scale at baseline and after 1, 3, and 6 months of treatment

Group	Preinjection	At 1-month follow-up F1	At 3-month follow-up F3	At 6-month follow-up F6
Group I	21.0	6.77	2.97	1.35
Group II	20.48	9.82	7.50	14.68
p value	>0.05 (0.64)	<0.05	<0.05	<0.05

showed significant improvement at 1 and 3 months than at baseline ($p < 0.05$) [Bs: 62.62 + 13.16 (48.17%) to F1: 31.52 + 15.63 (24.25%) to F3: 21.73 + 14.94 (16.72%)] (Table 6). However, they had increased pain and disability score after 3-month to 6-month follow-up [F3: 21.73 + 14.94 (16.72%) to F6: 26.7 + 17.97 (20.54%)] (Table 6). At the final follow-up, there was improvement in SPADI than at baseline but was insignificant ($p > 0.05$) in group II, but significant improvement was seen in the PRP group ($p < 0.05$). Self-limiting postinjection pain [< 3 levels in visual analog scale (VAS)] was observed in almost 50% of subjects in both PRP group and steroid group. During the study, no major adverse effects were observed in participants who received intra-articular injections.

DISCUSSION

Adhesive capsulitis is a common painful and disabling but self-limiting condition of poorly understood etiology, for which multiple treatment modalities exist but optimal management remains a topic of debate.^{12,13} Though steroid injections are the commonest mode of treatment, unfortunately, it has short-term pain relief and improvement in ROM and are associated with complications.^{14,15} Recently, PRP has emerged as a novel technology that has been used as an alternative therapy for adhesive capsulitis especially in situations where use of steroids is contraindicated or refused by the patient. Though there is paucity of data concerning the use of PRP in adhesive capsulitis, there is prima facie evidence that PRP injections were associated with improved functional outcome. The primary objective of the present study was to evaluate and compare the efficacy PRP and steroid injections in adhesive capsulitis. Injection is

Table 5: Between-group comparison of mean disability scale at baseline and after 1, 3, and 6 months of treatment

Group	Preinjection	At 1-month follow-up F1	At 3-month follow-up F3	At 6-month follow-up F6
Group I	43.20	13.20	5.77	2.20
Group II	42.13	21.70	14.27	30.02
p value	>0.05 (0.50)	<0.05	<0.05	<0.05

Table 6: Between-group comparison of total shoulder pain and disability index at baseline and after 1, 3, and 6 months of treatment

Group	Preinjection	At 1-month follow-up F1	At 3-month follow-up F3	At 6-month follow-up F6
Group I	64.20 ± 12.93	19.97 ± 9.52	8.73 ± 4.66	3.55 ± 3.49
Group II	62.62 ± 13.16	31.52 ± 15.63	21.73 ± 14.94	26.70 ± 17.97
p value	>0.05 (0.51)	<0.05	<0.05	<0.05

the preferred method to deliver PRP into the targeted site, and the authors had suggested that peppering allows dispersal of growth factors or corticosteroid to a larger surface area.¹¹ Furthermore, peppering-induced soft tissue injury in turn stimulates bleeding and generates openings in the hypo-vascular degenerative tissue, facilitating an improved healing response.¹¹

Female sex preponderance and involvement of nondominant shoulder for reasons not clearly known was found in the present study data. These results were in agreement with the published literatures which revealed that women are four times more affected than men, while the nondominant shoulder is slightly more prone to be affected.^{16–19} Involvement of nondominant extremity is due to the fact that as it is painful, patient uses it seldom and is easy to protect, and the dominant extremity can do the usual work.³ Hormonal changes in women may explain the female predilection of adhesive capsulitis.

The patients in the steroid groups showed remarkable improvements in pain, disability, and total SPADI score when compared with the baseline parameters. However, these effects did not last in the long-term. In the current study, this effect usually lasts for a maximum of 12 weeks and then the scores increased to a higher level at the final follow-up visit. Our findings agree with meta-analysis conducted by Buchbinder et al. and Wang et al. who concluded that the steroid injection for adhesive capsulitis may be beneficial although their effect may be short-term and not sustained.^{4,5} A possible explanation for these effects could be attributed to its anti-inflammatory effect that may lead to pain relief and mechanical improvement. Furthermore, Yoon et al. showed that there were no significant differences in efficacy of corticosteroids according to different doses, indicating the preferred use of a low dose in the initial stage.²⁰ Also, Dacre et al. in a randomized controlled trial concluded that there was no evidence for any add-on effect when steroid injections were combined with physical therapy. This insinuates that improvement cannot be upgraded above a certain level.²¹ The authors advised to refrain from multiple uses of steroid injections to avoid chondrolysis and detrimental long-term effects.^{14,15}

Platelet-rich plasma injection resulted in statistically significant improvement over steroid injection in SPADI scores at 24 weeks. Pain, disability, and total SPADI score were almost linearly improved in the PRP group. These results were agreed with Kothari et al, Aslani et al, Lin, and Barman who found that PRP injection was more effective

and had a long sustained efficiency.⁶⁻⁹ The authors speculated that it could be attributed to its anti-inflammatory effects and analgesic properties.²² Also, it stimulates revascularization of soft tissue and increases the concentration of growth factors locally to improve and enhance healing.^{23,24} Furthermore, PRP serves as a growth factor agonist and possesses both mitogenic and chemotactic properties. These growth factors in combination with high concentrations of activated platelets and anti-inflammatory components modulate the inflammatory pathway and healing cascade that leads to reversal of degenerative process.^{11,25}

Platelet-rich plasma is as effective as steroid injection in achieving symptom relief initially, for the treatment of adhesive capsulitis, but unlike steroid, it has long-term effects. In the view of reached results, we conclude that PRP injection should now be routinely recommended as the standard first-line therapy for treatment of adhesive capsulitis. The present study clearly demonstrates PRP injection to be an effective and well-tolerated alternative to steroid injection for treatment of adhesive capsulitis. It also offers additional advantages such as better patient compliance and its biological nature. Furthermore, PRP also have strong antimicrobial properties which contribute to prevention of infection.²⁶ The present study had no major adverse complications except exacerbation of pain for first 2 to 4 days which relieved with simple NSAIDs like paracetamol and cold fomentation.

CONCLUSION

Cost-effectiveness, easy availability, and autologous nature make PRP injection as a better alternative than steroid injection for the treatment of adhesive capsulitis. On the one hand, steroid injections were more effective in pain relief and improvements in ROM in the short-term. On the other hand, PRP injections promote healing and demonstrate a more linearly and sustained improvement both in pain score and disability scores while avoiding potential adverse effects associated with the use of steroid injection. Furthermore, fluoroscopic-guided injections may increase the efficacy of the procedure. The preliminary results are promising, but further prospective randomized trials are necessary to validate the efficacy.

LIMITATIONS

The present analysis has some important limitations that limit the generalization of findings of the present study:

- Single-center design, small sample size, and relative short follow-up period.
- In the present study, no attempt has been made to quantify the platelets concentration in the processed samples before the injection.
- The current study is purely subjective (SPADI score) as no attempts have been made to analyze the repair neither through imaging (magnetic resonance imaging) nor through any histopathological assessment.

CLINICAL SIGNIFICANCE

Platelet-rich plasma injections are safe and valuable therapeutic modality to alleviate the symptoms in subjects with adhesive capsulitis of shoulder. Platelet-rich plasma injection had a more prolonged efficiency than steroid injections.

ETHICAL APPROVAL

The study was approved by the Institutional Ethics Committee.

ACKNOWLEDGMENTS

Authors acknowledge all the patients who participated in the study, nursing, and paramedical staff. They also acknowledge the contribution of the entire research team.

REFERENCES

1. Le HV, Lee SJ, Nazarian A, et al. Adhesive capsulitis of the shoulder: Review of pathophysiology and current clinical treatments. *Shoulder Elbow* 2017;9(2):75–84. DOI: 10.1177/1758573216676786.
2. Neviaser JS. Adhesive capsulitis of the shoulder: a study of the pathological findings in periarthritis of the shoulder. *J Bone Joint Surg* 1945;27:211–222.
3. Manske RC, Prohaska D. Diagnosis and management of adhesive capsulitis. *Curr Rev Musculoskelet Med* 2008;1(3-4):180–189. DOI: 10.1007/s12178-008-9031-6.
4. Buchbinder R, Green S, Youd JM. Corticosteroid injections for shoulder pain. *The Cochrane database System Rev* 2003;2003(1):CD004016. DOI: 10.1002/14651858.CD004016.
5. Wang W, Shi M, Zhou C. Effectiveness of corticosteroid injections in adhesive capsulitis of shoulder: a meta-analysis. *Medicine* 2017;96(28):e7529. DOI: 10.1097/MD.00000000000007529.
6. Kothari SY, Srikumar V, Singh N. Comparative efficacy of platelet rich plasma injection, corticosteroid injection and ultrasonic therapy in the treatment of periarthritis shoulder. *J Clin Diagn Res* 2017;11(5):RC15–RC18. DOI: 10.7860/JCDDR/2017/17060.9895.
7. Aslani H, Nourbakhsh ST, Zafarani Z, et al. Platelet-Rich Plasma for Frozen Shoulder: A Case Report. *Arch Bone Jt Surg* 2016;4(1):90–93.
8. Lin J. Platelet-rich plasma injection in the treatment of frozen shoulder: a randomized controlled trial with 6-month follow-up. *Int J Clin Pharmacol Ther* 2018;56(8):366–371. DOI: 10.5414/CP203262.
9. Barman A, Mukherjee S, Sahoo J, et al. Single intra-articular platelet-rich plasma versus corticosteroid injections in the treatment of adhesive capsulitis of the shoulder: a cohort study. *Am J Phys Med Rehabil* 2019;98(7):549–557. DOI: 10.1097/PHM.0000000000001144.
10. Upadhyay S, Varma HS, Yadav S. Potential therapeutic effects of autologous platelet rich plasma on impaired wound healing: a prospective clinical study. *Int J Res Orthop* 2018;4(6):820–825. DOI: 10.18203/issn.2455-4510.IntJResOrthop20184024.
11. Upadhyay S, Damor V. Autologous platelet rich plasma versus corticosteroid injection for chronic plantar fasciitis: a prospective controlled randomized comparative clinical study. *Int J Res Med Sci* 2018;6(5):1594–1599. DOI: 10.18203/2320-6012.ijrms20181430.
12. Dias R, Cutts S, Massoud S. Frozen shoulder. *BMJ* 2005;331(7530):1453–1456. DOI: 10.1136/bmj.331.7530.1453.
13. Chauhan S, Kothari SY, Laisram N. Comparison of ultrasonic therapy, sodium hyaluronate injection and steroid injection in the treatment of periarthritis shoulder. *IJPMR* 2012;23(3):105–110.
14. Bulgen DY, Binder AL, Hazleman BL, et al. Frozen shoulder: Prospective clinical study with an evaluation of three treatment regimens. *Ann Rheum Dis* 1984;43(3):353–360. DOI: 10.1136/ard.43.3.353.
15. MacMahon PJ, Eustace SJ, Kavanagh EC. Injectable corticosteroid and local anesthetic preparations: a review for radiologists. *Radiology* 2009;252(3):647–661. DOI: 10.1148/radiol.2523081929.
16. Hand C, Clipsham K, Rees JL, et al. Long-term outcome of frozen shoulder. *J Shoulder Elbow Surg* 2008;17(2):231–236. DOI: 10.1016/j.jse.2007.05.009.
17. Levine WN, Kashyap CP, Bak SF, et al. Nonoperative management of idiopathic adhesive capsulitis. *J Shoulder Elbow Surg* 2007;16(5):569–573. DOI: 10.1016/j.jse.2006.12.007.
18. Murakami AM, Kempel AJ, Engebretsen L, et al. The epidemiology of MRI detected shoulder injuries in athletes participating in the

- Rio de Janeiro 2016 summer olympics. *BMC Musculoskelet Disord* 2018;19(1):296. DOI: 10.1186/s12891-018-2224-2.
19. Kingston K, Curry EJ, Galvin JW, et al. Shoulder adhesive capsulitis: epidemiology and predictors of surgery. *J Shoulder Elbow Surg* 2018;27(8):1437–1443. DOI: 10.1016/j.jse.2018.04.004.
20. Yoon SH, Lee HY, Lee HJ, et al. Optimal dose of intra-articular corticosteroids for adhesive capsulitis: a randomized, triple-blind, placebo-controlled trial. *Am J Sports Med* 2013;41(5):1133–1139. DOI: 10.1177/0363546513480475.
21. Dacre JE, Beeney N, Scott DL. Injections and physiotherapy for the painful stiff shoulder. *Ann Rheum Dis* 1989;48(4):322–325. DOI: 10.1136/ard.48.4.322.
22. Zhang J, Wang JH. PRP treatment effects on degenerative tendinopathy – an in vitro model study. *Muscles Ligaments Tendons J* 2014;4(1):10–17. DOI: 10.32098/mltj.01.2014.03.
23. Sheth U, Dwyer T, Smith I, et al. Does platelet-rich plasma lead to earlier return to sport when compared with conservative treatment in acute muscle injuries? A systematic review and meta-analysis. *Arthroscopy* 2018;34(1):281–288.e281. DOI: 10.1016/j.arthro.2017.06.039.
24. Ebert JR, Wang A, Smith A, et al. A midterm evaluation of postoperative platelet-rich plasma injections on arthroscopic supraspinatus repair: a randomized controlled trial. *Am J Sports Med* 2017;45(13):2965–2974. DOI: 10.1177/0363546517719048.
25. Molloy T, Wang Y, Murrell G. The roles of growth factors in tendon and ligament healing. *Sports Med* 2003;33(5):381–394. DOI: 10.2165/00007256-200333050-00004.
26. Badade PS, Mahale SA, Panjwani AA, et al. Antimicrobial effect of platelet-rich plasma and platelet-rich fibrin. *Indian J Dent Res* 2016;27(3):300–304.