

## CASE REPORT

# Stellate Ganglion Block for Treatment of Patient with Raynaud's Syndrome

Anagha MV<sup>1</sup>, Rangalakshmi<sup>2</sup>, Gautam Das<sup>3</sup>

## ABSTRACT

Raynaud's syndrome is characterized by abnormal vascular constriction of digits and extremities from a widespread of interaction of sympathetic nervous system, vascular endothelium, and endocrine system. Our case report is about a 65-year-old female, farmer by occupation presenting with pain and discoloration of distal phalanx of index, middle, and ring fingers of right hand treated with stellate ganglion block under ultrasonography (USG) guidance with a combination of triamcinolone, 0.5% lignocaine, and normal saline. Post procedure, Horner's syndrome noted to confirm the block, and 24 hours later, the patient had significant pain relief with slight improvement of the discoloration.

**Keywords:** Raynaud's syndrome, Stellate ganglion block, Ultrasonography.

*Journal on Recent Advances in Pain* (2019): 10.5005/jp-journals-10046-0149

## INTRODUCTION

Raynaud's syndrome is a disease of abnormal sympathetic tone which produces local vasospasm of arterial network involving arterioles, arteriovenous anastomoses, and rarely proximal vessels.<sup>1</sup>

Treatment is done in a stepwise fashion with moderate symptoms requiring pharmacotherapy in the form of calcium channel blocker or selective serotonin reuptake inhibitor (SSRI).<sup>2</sup> If no response with these, phosphodiesterase inhibitor, losartan, or topical nitrate is used. For severe symptoms with ischemia, a combination therapy was utilized including use of antiplatelets, endothelin receptor inhibitor, or botulinum toxin before sympathectomy.<sup>3</sup>

Here we present a case of Raynaud's syndrome with ischemic digit discoloration which was successfully managed by stellate ganglion block.

## CASE DESCRIPTION

A 65-year-old female patient, farmer by occupation presented with 2 months of history of pain and reddish-blue discoloration of distal phalanges of index, middle, and ring fingers of right hand (Fig. 1).

The numerical rating scale (NRS) was 8. Pain was continuous, aggravated by farming activities, cooking, and washing vessels and relieved only slightly with medication. Pain was more toward the evening. Pain detect tool score was 5, which indicated somatic type of pain, and patient health questionnaire 9 score was 8, which indicated mild depression. The patient was known hypertensive on tablet amlodipine 5 mg once daily. On examination, apart from the discoloration, it was tender on palpation. Tone and power of muscles were normal.

## MANAGEMENT

The patient was diagnosed to have Raynaud's syndrome and planned for stellate ganglion block under ultrasonography (USG) guidance. After standard nil per oral (NPO) protocol and basic investigations, the patient was shifted to operation theatre (OT). Monitors were attached and baseline vitals were evaluated and IV fluid started. Under USG guidance, 40 mg triamcinolone + 0.5% preservative free lignocaine and normal saline (total volume: 10 mL) was injected after confirming sonological landmarks as shown in Figure 2.

<sup>1,2</sup>Department of Anaesthesiology, RajaRajeswari Medical College and Hospital, Bengaluru, Karnataka, India

<sup>3</sup>Department of Pain Medicine, Daradia Pain Hospital, Kolkata, West Bengal, India

**Corresponding Author:** Anagha MV, Department of Anaesthesiology, RajaRajeswari Medical College and Hospital, Bengaluru, Karnataka, India, Phone: +91 9008988522, e-mail: mv.anagha@gmail.com

**How to cite this article:** Anagha MV, Rangalakshmi, Das G. Stellate Ganglion Block for Treatment of Patient with Raynaud's Syndrome. *J Recent Adv Pain* 2019;5(3):90–91.

**Source of support:** Nil

**Conflict of interest:** None

Post procedure, the patient was monitored for 2 hours. Horner's syndrome noted to confirm the block as shown in Figure 3. The patient had NRS score of 3 after 24 hours with slight improvement in color.



**Fig. 1:** Hand showing Raynaud's disease

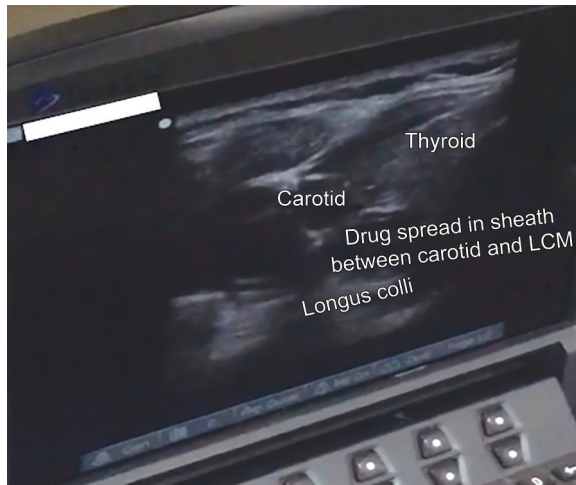


Fig. 2: Ultrasound image of drug spread

## DISCUSSION

Stellate ganglion is a cervical sympathetic ganglion which when blocked by local anesthetic prevents the sympathetic discharge resulting in dilatation of peripheral vessels and thus preventing progression of gangrene in digits.<sup>4</sup>

Stellate ganglion block is performed by depositing local anesthetic between longus colli muscle and carotid sheath at the level of C6 or C7 vertebra.<sup>5</sup> Stellate ganglion block works by blocking the neural connections in its region of innervation, improvement in the blood supply of the region, and reduction of adrenal hormone plasma concentration, thereby relieving effects of Raynaud's syndrome. It is helpful in multitude of conditions such as complex regional pain syndrome (CRPS) of upper limb, peripheral vascular disease, upper limb embolism, postherpetic neuralgia, to name a few.

Use of USG to perform this block has been found to be more effective and safer than landmark technique as it avoids needle injury to blood vessels nearby. It can also be performed under fluoroscopic guidance with the use of contrast dye. Nevertheless USG has gained wider popularity, it is safer, real-time injection of drug, no radiation exposure, and hence, we chose to perform the procedure with USG.

Efficacy of the block varies from person to person with some showing response with single injection while some require up to

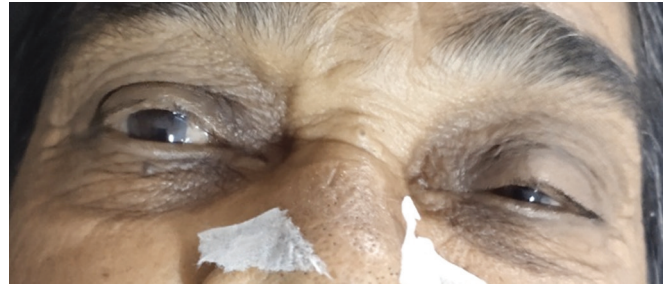

Fig. 3: Horner's syndrome

10 injections. The block lasts from few hours to several weeks.<sup>6</sup> Use of neurolytic agents such as alcohol or phenol can prolong duration of action of block but due to presence of vital structures in the vicinity of the ganglion their use is less popular.

## CONCLUSION

In summary, our case had Raynaud's syndrome involving the digits of right hand which was managed by USG stellate ganglion block with good postprocedure outcome. With the skillful use of USG, we were able to accurately give the block without any complications and is the best available technique for management of patients with such conditions.

## REFERENCES

1. Bakst R, Merola J, Franks A, et al. Raynaud's phenomenon: pathogenesis and management. *J Am Acad Dermatol* 2008;59(4): 633–653. DOI: 10.1016/j.jaad.2008.06.004.
2. Hughes M, Herrick A. Raynaud's phenomenon. *Best Pract Res Clin Rheumatol* 2016;30(1):112–132. DOI: 10.1016/j.berh.2016.04.001.
3. Wigley F, Flavahan N. Raynaud's Phenomenon. *N Engl J Med* 2016;375(6):556–565. DOI: 10.1056/NEJMr1507638.
4. Yamazaki H, Nishiyama J, Suzuki T. Use of perfusion index from pulse oximetry to determine efficacy of stellate ganglion block. *Local Reg Anesth* 2012;5:9–14. DOI: 10.2147/LRA.S30257.
5. Narouze S. Ultrasound-guided stellate ganglion block: safety and efficacy. *Curr Pain Headache Rep* 2014;18(6):424. DOI: 10.1007/s11916-014-0424-5.
6. Yucel I, Demiraran Y, Ozturan K, et al. Complex regional pain syndrome type I: efficacy of stellate ganglion blockade. *J Orthop Traumatol* 2009;10(4):179–183. DOI: 10.1007/s10195-009-0071-5.