

# Regional Anesthesia as Supplementation to General Anesthesia in Endonasal Surgeries

Sarika S Naik<sup>1</sup>, Sudhir M Naik<sup>2</sup>

## ABSTRACT

**Background:** Endoscopic surgeries are minimally invasive surgeries to treat sinus pathologies. The challenges faced by the anesthesiologist are to provide bloodless field of surgery, to maintain hemodynamic stability, and to reduce anesthetic supplementation to facilitate early recovery of the patient. The preferred anesthesia is general with controlled ventilation, stable surgical field, and airway protection with adequate anesthesia. Problems faced during the procedure are to keep the minimum the bleeding during surgery so that a better visibility of the endoscopic magnified surgical field, faster awakening after reversal of general anesthesia, faster return of protective airway reflexes, and optimal postoperative analgesia. Sphenopalatine ganglion block (SPGB) has proven an effective adjuvant to general anesthesia during sinonasal surgery. Reduced bleeding increases visibility and reduces operative time with reduced complications and better results. In our study, SPGB was supplemented with the general anesthesia to evaluate the comfort of operability, opioid supplementation, inhalation anesthetic requirement, and intraoperative and postoperative complications.

**Materials and methods:** Our study is a randomized controlled triple-blind study with 30 patients in each group. In both the groups, general anesthesia was given. In group I, SPGB was given with a 10 mL of 1% xylocaine local anesthetic, and in group II, SPGB was given with placebo.

**Results:** We have observed that there is a reduced intraoperative and postoperative bleeding in group I, the field of vision is better in group I, and fentanyl supplementation and isoflurane consumption was less in group I. The intraoperative and postoperative complications were less in group I.

**Conclusion:** Sphenopalatine ganglion block regional anesthesia is reliable supplementation to general anesthesia in endonasal endoscopic procedures to provide stable surgical field with reduced anesthetic requirement and minimal intraoperative and postoperative complications.

**Keywords:** Endonasal surgery, General anesthesia, Postoperative respiratory system evaluation score, Sphenopalatine ganglion block.

*Journal on Recent Advances in Pain* (2019): 10.5005/jp-journals-10046-0136

## INTRODUCTION

Endonasal endoscopic sinus surgery is the minimally invasive surgical method for the treatment of sinus pathology which has taken a full circle toward conservative management in the present evidence-based scenario.<sup>1</sup> The telescopic vision using the endoscope has given surgeons a direct visualization of critical landmarks and greater degree of freedom of instrumentation to comprehend and clear the disease from areas of pathogenesis of sinusitis.<sup>2</sup> The preferred anesthesia is general with controlled ventilation with a stable surgical field and airway protection with adequate anesthesia and analgesia.<sup>1</sup> The major problems faced during the procedure are to keep the minimum the bleeding during surgery so that a better visibility of the endoscopic magnified surgical field,<sup>1</sup> faster awakening after reversal of general anesthesia, faster return of protective airway reflexes, and optimal postoperative analgesia.<sup>1</sup> Reduced bleeding increases visibility intraoperatively and reduces operative time with reduced complications and better results of surgery.<sup>1</sup> Hypotension maintained during anesthesia and 30° head end elevation increases the intraoperative hemostasis.<sup>3</sup> Regional blocks have complemented inhalation anesthesia in endonasal surgeries to maintain low blood pressure, reduce blood loss, reduce the anesthetic agent requirements, and reduce possible postoperative complications and pain.<sup>4</sup> Sphenopalatine ganglion block (SPGB) has proven an effective adjuvant to general anesthesia during sinonasal surgery.<sup>4-7</sup>

The ganglion has somatosensory effects through the trigeminal and facial nerves, visceral motor functions through its parasympathetic activity via the superficial petrosal nerve,

<sup>1</sup>Department of Anesthesia and Critical Care, The Oxford Medical College, Hospital and Research Center, Bengaluru, Karnataka, India

<sup>2</sup>Department of ENT, Head and Neck Oncosurgery, The Oxford Medical College, Hospital and Research Center, Bengaluru, Karnataka, India

**Corresponding Author:** Sarika S Naik, Department of Anesthesia and Critical Care, The Oxford Medical College, Hospital and Research Center, Bengaluru, Karnataka, India, Phone: +91 8088000800, e-mail: bitta301@gmail.com

**How to cite this article:** Naik SS, Naik SM. Regional Anesthesia as Supplementation to General Anesthesia in Endonasal Surgeries. *J Recent Adv Pain* 2019;5(2):40-44.

**Source of support:** Nil

**Conflict of interest:** None

and sympathetic functions through its connection to the cervical sympathetic chain via deep petrosal nerve and sensory distribution to orbit, nose, palate, and buccal mucosa.<sup>8</sup> We have used the ganglion block to reduce the operative time and improve quality, while in the literature, it was used to reduce head ache and facial pain. Transnasal endoscopic approach had stood the test of time and the best possible approach for the ganglion block in present time.<sup>9,10</sup> We evaluated efficacy of SPGB combined with general anesthesia in patients undergoing endoscopic endonasal surgeries. The parameters compared were difference in blood loss, isoflurane consumption, fentanyl used, recovery time, postoperative pain, and postoperative complications in both the groups.

## MATERIALS AND METHODS

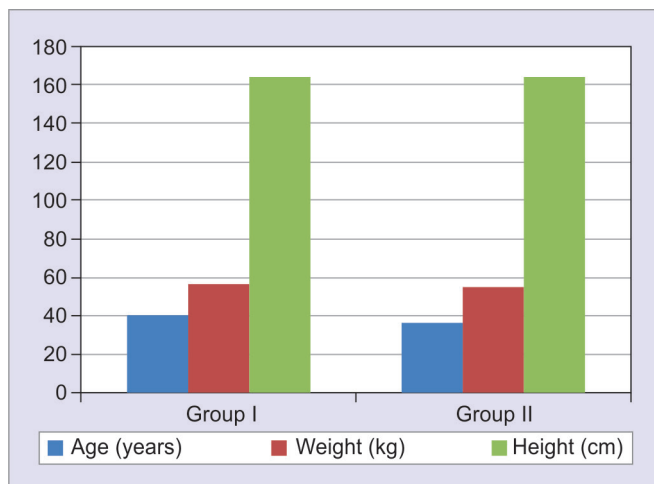
This is a controlled trial with a random allocation of 60 patients in group I ( $n = 30$ ) and group II ( $n = 30$ ), which included patients posted for endoscopic sinus surgeries with septoplasties done. Group I had 30 patients operated under general anesthesia with bilateral SPGB under endonasal endoscopic guidance. The group II had 30 patients operated under general anesthesia alone with placebo SPGB given (Table 1 and Fig. 1).

We used the random allocation table and allotment of the cases into groups was done by a staff nurse A (blinded). Later the scrub sister B prepares the 1% xylocaine infiltrate SPGB1 and placebo SPGB2 and records it against the patients UHID no of the hospital. The 10 cc syringes are loaded and the external appearance of both SPGB1 and SPGB2 appear similar. General anesthesia with endotracheal intubation was done in all cases and nasal packing done with 10 mL 4% lidocaine and 3 ampoules of adrenaline topically. After 20 minutes, SPGB was done as described with the syringe provided by sister 2 (blinded). The parameters were noted by sister 3 (blinded) and recorded according to the protocol. The evaluation was done by the primary investigator with the blinded data and later analyzed by the statistician. The statistician report was decoded by the assistant investigator and tabulated accordingly.

The parameters recorded were difference in blood loss, isoflurane consumption, fentanyl used and supplementation of muscle relaxant, recovery time, postoperative pain, and postoperative complications in groups I and II. Written informed consent was taken about being included as a part of the study and patients with other comorbidities were excluded from the study. Only American Society of Anesthesiologists (ASA) grade I and ASA grade II were included. All the need for recording the parameters were explained to the patient and the visual analog scale (VAS)

**Table 1:** Patients preoperative background

		Mean	<i>p</i> value
Age (years)	Group I	40.13	0.1563
	Group II	36.60	
Weight (kg)	Group I	56.47	0.2473
	Group II	55.03	
Height (cm)	Group I	164.37	0.9220
	Group II	164.20	



**Fig. 1:** Patients preoperative background

for pain which he has to mark postoperatively was made familiar. Operative procedures included shifting the patients to the theater under random allocation table. The procedure of preparation and premedication was kept uniform for all patients like securing the intravenous access with 18 g cannula with ringer lactate in the nondominant hand. Premedication with midazolam 1 mg, glycopyrolate 0.2 mg, and fentanyl 2 µg/kg body weight was given and induction was done with propofol 2–3 mg/kg body weight. Vecuronium 0.1 mg/kg to facilitate tracheal intubation with a cuffed endotracheal tube was given. After checking the bilateral air entry, the tube was connected to the closed circuit and oropharyngeal pack inserted.

Lungs were ventilated to maintain the PaCO<sub>2</sub> within 30–40 mm Hg. Anesthesia was maintained with 33% O<sub>2</sub> and 67% N<sub>2</sub>O and isoflurane between 0.2 and 2 minimum alveolar concentration (MAC) to maintain a mean arterial pressure (MAP) between 55 mm Hg and 65 mm Hg and the heart rate between 60 beats and 80 beats per minute. All patients were placed in a 15° reverse Trendelenburg position to improve venous drainage. After achieving satisfactory level of anesthesia, patients were subjected to SPGB. In group II, normal saline was injected in the same way as with local anesthetic in group I. Neither the anesthetists nor the surgeons were informed either local anesthetic or normal saline was given. In both the groups, nasal packing was done with 10 mL of 4% xylocaine and 3 mL of adrenaline. Block was given after 15 minutes of nasal packing to achieve nasal mucosal vasoconstriction to improve access. Surgeons gave the SPGB with 25 g spinal needle under endoscopic guidance. The block was given with 1% xylocaine 5 mL on each side or with 5 mL of normal saline.

The ganglion can be seen as a convergence of some of the vessels of lateral nasal wall toward the sphenopalatine foramen due to the disappearance of the vessels into the foramen called the vanishing point. The sphenopalatine ganglion (SPG) being the largest group of neurons in the head and neck lies in the foramen that lies immediately behind the ethmoidal crest situated at the posterior end of the attachment of the middle turbinate, oriented at an angle of 15°–20° with the sagittal plane. Superior turbinate acts as landmark to the SPG and it is 12 mm above and lateral to the superior border of the choana. Sphenopalatine ganglion is situated in the pterygopalatine fossa and medially is the foramen, which transmits the sphenopalatine vessels and nerves from pterygopalatine fossa to the nose. The ganglion is nearly 5 mm deep to the foramen covered by a layer of connective tissue and mucous membrane.

The hemodynamic goals were to maintain the MAP at 55–65 mm Hg and the heart rate of 60–80 beats per minute, by adjusting the isoflurane concentration and the use of fentanyl. The amount of blood loss, the consumption of isoflurane, and frequency of use of fentanyl and muscle relaxant were evaluated in both groups. Extubation was performed after full recovery and awakening, and ability of patients to follow verbal commands (eye opening or head lift for 5 seconds). The time interval between interruption of anesthetics and extubation was recorded as recovery time. The amount of blood loss was recorded. A scoring system of postoperative respiratory system evaluation, named postoperative respiratory system evaluation scoring (PRSES), was used for evaluation of postoperative respiratory complications. Postoperative respiratory system evaluation score were noted at the 1st, 5th, and 10th minutes after extubation by the same anesthetist. In the recovery room, patients reporting pain score greater than 3 on VAS were managed with incremental intravenous doses of fentanyl 25 µg.

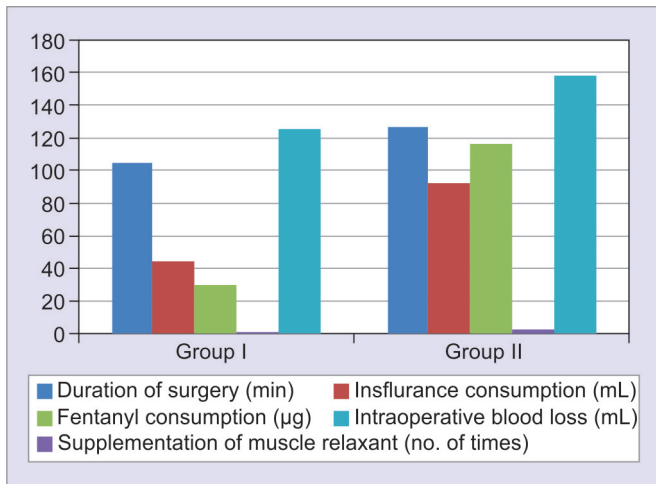
**RESULTS**

The data of all the patients were tabulated in groups I and II. Preoperative history of the patients did not significantly differ between the two groups and were randomly allotted (Table 2 and Fig. 2). In group I, there were 15 males and 15 females. In group II, there were 18 females and 12 males. In group I, there were 12 ASA grade I patients and 18 ASA grade II patients. In group II, there were 14 ASA grade I patients and 16 ASA grade II patients. The mean duration of the surgery in the group II was 104.67 with a standard deviation of 19.87 minutes. The mean duration of the surgery in the group I was 126.17 minutes with a standard deviation of 29.15 minutes. The *p* value is 0.0015, which is statistically very significant. Hence, the duration of the surgery was significantly less in block group II.

The mean isoflurane consumption in the group I was 45.33 mL with a standard deviation of 17.07. In group II, isoflurane consumption was 92.33 mL with a standard deviation of 21.44 and *p* value is 0.0001, which is significant. Isoflurane consumption was significantly reduced in group II with SPGB. The mean fentanyl consumption in group I with the block was 30 µg. The mean fentanyl consumption in the group II was 116.67 µg. The *p* value is 0.0001, which is highly significant. Opioids consumption is reduced in the group I with the SPGB. The mean muscle relaxant supplementation in group I with the SPGB is 0.87 times with a standard deviation of 0.73. The muscle relaxant supplementation in the group II was 2.67 times with a standard deviation of 0.11. The *p* value is 0.0001, which is significant. Supplementation of muscle relaxant is significantly reduced in the group I (Table 2).

**Table 2:** Intraoperative observations

		Mean	<i>p</i> value
Duration of surgery (minutes)	Group I	104.67	0.0015
	Group II	126.17	
Isoflurane consumption (mL)	Group I	45.33	0.0001
	Group II	92.33	
Fentanyl consumption (µg)	Group I	30	0.0001
	Group II	116.67	
Supplementation of muscle relaxant (number of times)	Group I	0.87	0.0001
	Group II	2.67	
Intraoperative blood loss (mL)	Group I	125	0.0018
	Group II	158.33	



**Fig. 2:** Intraoperative observations

The mean intraoperative blood loss in group I with the block is 125 mL and a standard deviation of 41.52. The mean blood loss in the group II is 158.33 with a standard deviation of 37.33. The *p* value is 0.0018, which is significant. The intraoperative blood loss is significantly reduced in the patients with none required blood transfusion or presented with excessive blood loss. The mean recovery time in the group I with the block is 7.10 minutes in comparison with the group II, where the mean recovery time is 10.50 minutes. The *p* value is 0.0004, which is significant, indicating decreased recovery time in group I with SPGB (Table 3 and Fig. 3). The mean postoperative fentanyl requirement in group I is 37.50 µg in comparison with group II, where the mean fentanyl requirement is 58.33 µg. The *p* value is 0.0001, which is significant. The analgesic requirement in the block is decreased in patients with SPGB group. Postoperative respiratory system evaluation score was better in group I than group II with PRSES-1 meaning no respiratory complication were seen in group I more than group II (Table 4).

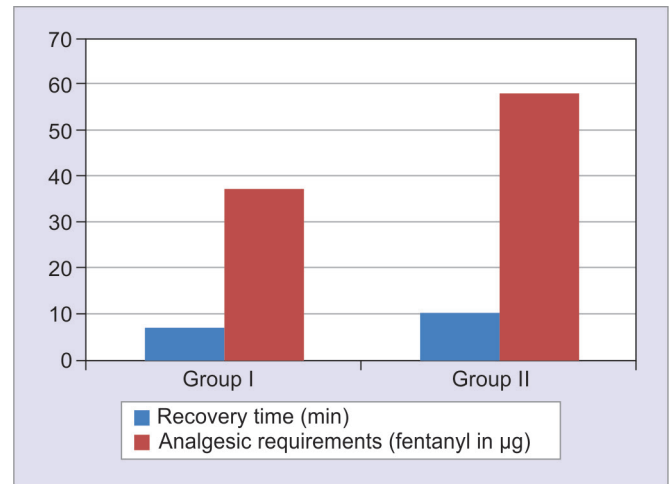
**DISCUSSION**

After endonasal endoscopic surgery, effects of inhalational and intravenous anesthesia and analgesia disappear in 2–3 hours or even less. So the regional blocks in the form of SGB or infraorbital nerve block extend the postoperative analgesia.<sup>11,12</sup> Nasal packing which amounts to most of the postoperative pain and discomfort immediately after surgery and thereafter leads to delayed functional recovery and it frequently contributes to dissatisfaction among patients.<sup>13–15</sup>

With the advancements in endoscopic surgery, the pain of the surgical wound has become minimal and the pain of nasal packing has increased.<sup>16,17</sup> All said and done smooth recovery with optimal analgesia also depends on the stable hemodynamic parameters during and after surgery.<sup>16,17</sup> Also postoperative stress and pain shoots up the blood pressure from sympathetic stimulation as pain can cause postoperative bleeding.<sup>16,17</sup> The pterygopalatine

**Table 3:** Postoperative observations

		Mean	<i>p</i> value
Recovery time (minutes)	Group I	7.10	0.0004
	Group II	10.50	
Analgesic requirements (fentanyl in µg)	Group I	37.50	0.0001
	Group II	58.33	



**Fig. 3:** Postoperative observations

**Table 4:** PRSES score

		PRSES 1	PRSES 2	PRSES 3–5	Mean	p value
PRSES 1st minute	Group I	13	15	2	1.67	0.0138
	Group II	5	19	6	2.27	
PRSES 5th minute	Group I	18	12		1.40	0.0332
	Group II	11	15	4	1.77	
PRSES 10th minute	Group I	22	8	0	1.20	0.0107
	Group II	15	12	3	1.60	

foramen lodges the largest parasympathetic ganglion of the head and neck, i.e., the SPG, which receives the sensory, sympathetic, and parasympathetic roots. Sphenopalatine branches of maxillary nerve give the sensory roots while the deep petrosal gives the sympathetic nerve roots.<sup>18</sup> The SPG regulates the nasal mucosal blood flow as the preganglionic parasympathetic fibers derived from the greater petrosal branch of the facial nerve synapse with neurons here.<sup>18</sup> Hence, SPGB regulates the blood supply of the ethmoid, sphenoid, and frontal sinuses, which are supplied by the ethmoidal artery and the supraorbital artery, the branches of the internal carotid artery.<sup>18</sup> The sympathetic tone can be reduced by intravenous agents like propofol which helps in diminishing circulation in nasal cavity and sinuses, improving the ease of surgery with a clear hemostatic field.<sup>18</sup> Also some studies have shown no significant differences with concern to intraoperative bleeding using isoflurane and propofol.<sup>19</sup> Cho et al. reported that SPG block has limited utility for postoperative analgesia in patients undergoing functional endoscopic sinus surgery (FESS).<sup>20</sup> On the contrary, Kesimci et al. reported that either bupivacaine or levobupivacaine provided effective postoperative analgesia after FESS.<sup>21</sup>

The use of sympatholytic drugs (dexmedetomidine and clonidine) is proven for better hemodynamic stability.<sup>22,23</sup> The topical SPGB dates back to the previous century with the use of cocaine topical for minimal surgical procedures.<sup>22,23</sup> Osguthorpe et al. in their study analyzed the multimodal analgesic techniques of adding bilateral blockade of the SGB to a standardized GA plan for better pain control and recovery times with less opioid administration.<sup>24</sup> They reported no supplemental narcotic at in the SPGB group compared to the GA group and also faster discharge and reduced postoperative pain and effective antiemesis.<sup>24</sup> Also studies have reported the infraorbital nerve block has better postoperative analgesia in nasal surgeries and endonasal procedures in adult as well as in pediatric population.<sup>4,5</sup> A better analgesia was reported with pack removal procedures with the SPGB.<sup>4,5</sup> Hwang et al. reported better postoperative analgesia with infraorbital nerve block in their study on 40 patients with septoplasties.<sup>25</sup> Meanwhile, the postoperative pain scores which are usually maximal in the first postoperative day did not seem to be significantly better in this study.<sup>25</sup>

Our study is done in a medical college teaching hospital and the confounding factors are tried to be kept minimal as the surgeries are done by a single surgeon with one assistant and scrub nurse, and SGB is given by the same surgeon. Endoscopy facilitates the exact localization of the anatomy of the sphenopalatine foramen so direct injection of the target ganglion is possible. The literature also report the varied anatomy to the cause of less effectiveness of the block in some studies, but with improved optics and the less diameter, endoscopes have made maneuvering through the nose more possible even in severe obstruction. The advantages of SPGB are well-documented in the literature, but a study to evaluate all

the parameters regarding the hemostasis, intraoperative stability and postoperative analgesia are less. So we have made an effort at including all these parameters in a single study.<sup>25</sup>

The combined use of general anesthesia and endoscopic SPGB has improved surgical field (decrease blood loss), reduction of isoflurane consumption, also fentanyl supplementation, faster recovery, reduction of postoperative pain, and reduction of postoperative respiratory complications according to PRSES scores (2–5).

## CONCLUSION

The sphenopalatine block when added to general anesthesia has in our study reduced intraoperative bleeding, reduced isoflurane consumption, reduced opioid supplementation, and improved postoperative analgesia. So for the sphenopalatine block, regional anesthesia is reliable complement to general anesthesia in endonasal endoscopic procedures.

## REFERENCES

- Al-Mujaini A, Wali U, Alkhabori M. Functional endoscopic sinus surgery: indications and complications in the ophthalmic field. *Oman Med J* 2009;24(2):70–80. DOI: 10.5001/omj.2009.18.
- McLaughlin Jr RB. History of surgical approaches to the frontal sinus. *Otolaryngol Clin North Am* 2001;34(1):49–58. DOI: 10.1016/S0030-6665(05)70294-2.
- Romlin B, Petruson K, Nilsson K. Moderate superficial hypothermia prolongs bleeding time in humans. *Acta Anaesthesiol Scand* 2007;51(2):198–201. DOI: 10.1111/j.1399-6576.2006.01181.x.
- Higashizawa T, Koga Y. Effect of infraorbital nerve block under general anesthesia on consumption of isoflurane and postoperative pain in endoscopic endonasal maxillary sinus surgery. *J Anesth* 2001;15(3):136–138. DOI: 10.1007/s005400170014.
- Molliex S, Navez M, Baylot D, et al. Regional anesthesia for outpatient nasal surgery. *Br J Anaesth* 1996;76(1):151–153. DOI: 10.1093/bja/76.1.151.
- Danielsen A. Functional endoscopic sinus surgery on a day case outpatient basis. *Clin Otolaryngol* 1992;17:473–477. DOI: 10.1111/j.1365-2273.1992.tb01699.x.
- Lee WC, Kapur TR, Ramsden WN. Local and regional anesthesia for functional endoscopic sinus surgery. *Ann Otol Rhinol Laryngol*; 1997;106(9):767–769. DOI: 10.1177/000348949710600910.
- Cambareri JJ. Sphenopalatine ganglion. In: *Image Guided Pain Management* Thomas PS, ed. Lippincott Raven Publishers, Philadelphia; 1997. pp. 27–33.
- Prasanna A, Murthy PS. Sphenopalatine ganglion block under vision using rigid nasal sinuscope. *Reg Anesth* 1993;18(2):139–140.
- Koshy RC, Varghese BT. Sphenopalatine ganglion neurolytic block in the management of intractable pain due to head and neck malignancies (abstract). *J Anesth Clin Pharmacol* 1999;15:379–379.
- Friedman M, Venkatesan TK, Lang D, et al. Bupivacaine for postoperative analgesia following endoscopic sinus surgery. *Laryngoscope* 1999;106(11):1382–1385. DOI: 10.1097/00005537-199611000-00014.



12. Bicer C, Eskitascioglu T, Aksu R, et al. Comparison of preincisional infiltrated levobupivacaine and ropivacaine for acute postoperative pain relief after septorhinoplasty. *Curr Ther Res Clin Exp* 2011;72(1): 13–22. DOI: 10.1016/j.curtheres.2011.02.003.
13. Fernandes SV. Postoperative care in functional endoscopic sinus surgery. *Laryngoscope* 1999;109(6):945–948. DOI: 10.1097/00005537-199906000-00020.
14. Gottschalk A, Ochroch EA. Preemptive analgesia: what do we do now? *Anesthesiology* 2003;98(1):280–281. DOI: 10.1097/00000542-200301000-00047.
15. Chidambaram A, Nigam A, Cardozo AA. Anticipated absence from work ('sick leave') following routine ENT surgery: are we giving the correct advice? A postal questionnaire survey. *Clin Otolaryngol Allied Sci* 2001;26(2):104–108. DOI: 10.1046/j.1365-2273.2001.00433.x.
16. Karaman E, Gungor G, Alimoglu Y, et al. The effect of lidocaine, bupivacaine and ropivacaine in nasal packs on pain and hemorrhage after septoplasty. *Eur Arch Otorhinolaryngol* 2011;268(5):685–689. DOI: 10.1007/s00405-010-1432-7.
17. Al-Qudah M. Endoscopic sphenopalatine ganglion blockade efficacy in pain control after endoscopic sinus surgery. *Int Forum Allergy Rhinol* 2016;6(3):334–338. DOI: 10.1002/alr.21644.
18. Bhattacharyya S, Tewari MK, Ghosh S, et al. Evaluation of the efficacy of bilateral sphenopalatine ganglion block in endoscopic sinus surgery under general anesthesia: a randomized prospective controlled trial. *Res Opin Anesth Intens Care* 2016;3(4):173–178. DOI: 10.4103/2356-9115.195878.
19. Law NL, Ng KF, Irwin MG, et al. Comparison of coagulation and blood loss during anesthesia with inhaled isoflurane or intravenous propofol. *Br J Anaesth* 2001;86(1):94–98. DOI: 10.1093/bja/86.1.94.
20. Cho DY, Drover DR, Nekhendzy V, et al. The effectiveness of preemptive sphenopalatine ganglion block on postoperative pain and functional outcomes after functional endoscopic sinus surgery. *Int Forum Allergy Rhinol* 2011;1(3):212–218. DOI: 10.1002/alr.20040.
21. Kesimci E, Öztürk L, Bercin S, et al. Role of sphenopalatine ganglion block for postoperative analgesia after functional endoscopic sinus surgery. *Eur Arch Otorhinolaryngol* 2012;269(1):165–169. DOI: 10.1007/s00405-011-1702-z.
22. Shams T, El Bahnasawe NS, Abu-Samra M, et al. Induced hypotension for functional endoscopic sinus surgery: a comparative study of dexmedetomidine versus esmolol. *Saudi J Anaesth* 2013;7(2):175–180. DOI: 10.4103/1658-354X.114073.
23. Mohseni M, Ebneshahidi A. The effect of oral clonidine premedication on blood loss and the quality of the surgical field during endoscopic sinus surgery: a placebo-controlled clinical trial. *J Anesth* 2011;25(4):614–617. DOI: 10.1007/s00540-011-1157-9.
24. Osguthorpe JD. Surgical outcomes in rhinosinusitis: What we know. *Otolaryngol Head Neck Surg* 1999;120(4):451–453. DOI: 10.1053/hn.1999.v120.a95228.
25. Hwang J, Liu C, Liu T, et al. Sphenopalatine ganglion block before removal of nasal packing. *Laryngoscope* 2003;113(8):1423–1424. DOI: 10.1097/00005537-200308000-00030.