

# Case Report on Unusual Presentation of Herniated Intervertebral Disk

Jeshnu P Tople<sup>1</sup>, Gautam Das<sup>2</sup>, Subhasree P Das<sup>3</sup>, Deepak KP Garg<sup>4</sup>, Wiquar Ahmed<sup>5</sup>

## ABSTRACT

Lumbar disk herniation with radiculitis is commonly presented as low back pain radiating down the lower extremity unilaterally along the affected dermatome. There can be various presentations of lumbar radiculopathy such as nondermatomal distribution of pain, patchy distribution of pain, and mismatch between clinical presentation and image findings. Symptoms of lumbar radiculopathy or radiculitis typically aggravate on walking and have partial relief on rest and forward bending. We got an atypical case of herniated lumbar disk where the patient presented with absence of low back pain, absence of pain along the thigh, older age, and pain aggravating on sitting. It emphasizes that one should not exclude any clinical diagnoses unless proved.

**Keywords:** Disk herniation, Lumbosacral radiculopathy, Radiculopathy in elderly.

*Journal on Recent Advances in Pain* (2019): 10.5005/jp-journals-10046-0135

## INTRODUCTION

Lumbosacral radicular syndrome is characterized by a radiating pain in one or more lumbar or sacral dermatomes; it may or may not be accompanied by other radicular irritation symptoms and/or symptoms of decreased function.<sup>1</sup> Low back pain with radiation to lower extremity can be caused by diverse pathologies such as lesions of intervertebral discs; degenerative spinal disorders; neoplastic, infectious, traumatic, and metabolic and vascular lesions affecting nerve roots and lumbosacral plexus; pathologic lesions and entrapment neuropathies involving sciatic nerves; pain of myofascial origin; and pain originating from sacroiliac and facet joints.<sup>2</sup> The incidence of low back pain with radicular symptoms ranges from 12 to 40%.<sup>2</sup> And the point prevalence is 4.6–13.4%, whereas the lifetime prevalence is 1.2–43%.<sup>1</sup>

This case is presented to illustrate how lumbar radiculopathy can be manifested from herniated lumbar intervertebral disk without any complaint of back pain and pain can aggravate after sitting for few minutes.

## CASE DESCRIPTION

A 64-year-old male presented to our clinic with chief complaint of pain over lateral aspect of right leg and dorsum of right foot since 5 days. Pain was associated with numbness, tingling, sharp shooting sensation along lateral aspect of right leg, and dorsum of right foot till great toe. Pain gets aggravated by sitting for 3–4 minutes and walking for 2–3 minutes; pain was relieved by standing and lying down. There was no history of trauma, fall, and loss of weight. There was no bladder and bowel dysfunction. He did not report any history of back pain recently or in the past few years. He is known case of diabetes mellitus since 18 years and had undergone coronary artery bypass graft surgery 18 years back.

Examination revealed average built adequately nourished individual. He preferred to be in standing position than sitting during clinical interview. The gait and posture was normal. The range of motion of lumbar spine was normal. Sensory examination of lower limb suggested that there was 40% loss of fine touch along right L5 dermatome compared to left side. On motor examination, there was weakness of dorsiflexion for great toe with a power of 4/5.

<sup>1</sup>Department of Pain, Daradia Pain Hospital, Kolkata, West Bengal, India

<sup>2</sup>Department of Pain Medicine, Daradia Pain Clinic, Kolkata, West Bengal, India

<sup>3–5</sup>Department of Interventional Pain, Daradia Pain Hospital, Kolkata, West Bengal, India

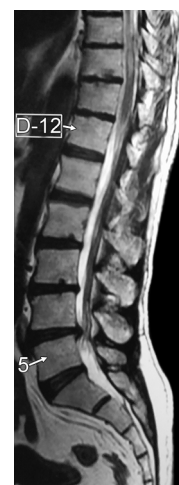**Corresponding Author:** Jeshnu P Tople, Department of Pain, Daradia Pain Hospital, Kolkata, West Bengal, India, Phone: +91 9990093497, e-mail: jeshnu@gmail.com

**How to cite this article:** Tople JP, Das G, Das SP, *et al.* Case Report on Unusual Presentation of Herniated Intervertebral Disk. *J Recent Adv Pain* 2019;5(2):57–59.

**Source of support:** Nil

**Conflict of interest:** None

Reflexes were normal. The straight leg rising (SLR) test was negative on both sides. On spine examination, there was no axial or paramedian tenderness.



**Fig. 1:** Magnetic resonance imaging showing herniated intervertebral disk: sagittal view

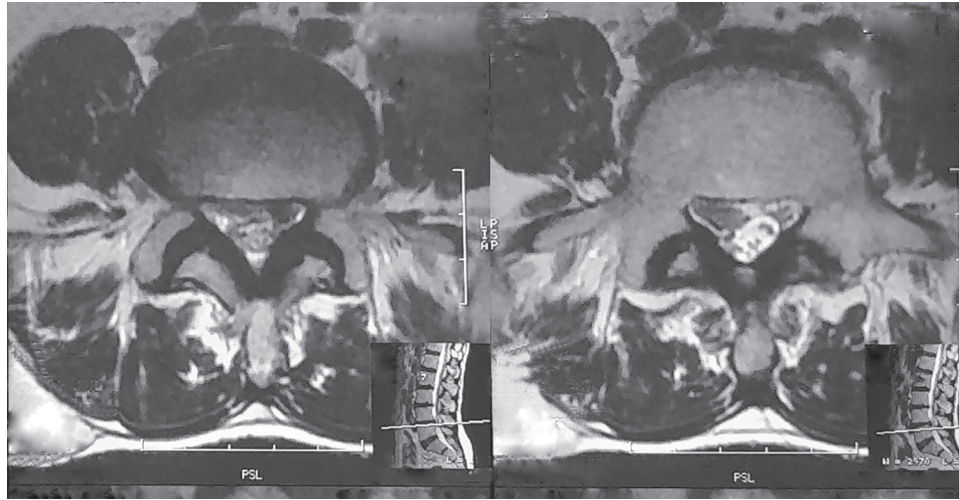


Fig. 2: Magnetic resonance imaging showing herniated intervertebral disk: transverse view

Magnetic resonance imaging (MRI) was done which was suggestive of downward migrated L4–5 intervertebral disk on right side. We treated the patient conservatively for L5 radiculopathy (Figs 1 and 2).

## DISCUSSION

Lumbar disk herniation with radiculitis is commonly presented as low back pain radiating down the lower extremity unilaterally along the affected dermatome. Along with nociceptive pain, there are usually some features of neuropathic pain including but not limited to tingling, numbness, burning, pinprick sensation, or sharp shooting pain. In radiculopathy, apart from these features, there is neurological deficit such as sensory loss along the affected dermatome, and/or motor weakness of the muscles supplied by affected nerve root, and/or loss of deep and superficial reflexes. Also one must exclude the presence of cauda equine syndrome as acute lower lumbar disk herniation can lead to this devastating clinical picture.<sup>3</sup> Symptoms of lumbar radiculopathy or radiculitis typically aggravate on walking and have partial relief on rest and forward bending.<sup>4</sup> However, not all patients present with the typical clinical scenario. There can be various presentations of lumbar radiculopathy such as nondermatomal distribution of pain, patchy distribution of pain, and mismatch between clinical presentation and image findings.<sup>5–7</sup>

Our patient had pain over lateral aspect of the leg and dorsum of foot on right side and weakness (4/5) of right extensor hallucis longus. However, there was no complaint of low back pain and pain along the lateral or posterolateral aspect of the thigh. Moreover, his pain gets aggravated on sitting for 3–4 minutes and walking for 2–3 minutes. So we suspected of pain of myofascial origin of iliopsoas or piriformis. As the patient was a diabetic for more than 18 years, another possible diagnosis was diabetic peripheral neuropathy, but keeping in mind the acuteness of onset of symptoms in a well-controlled diabetic patient, diabetic neuropathy was excluded. Magnetic resonance imaging was done prior to our consultation which was suggestive of downward migrated L4–5 intervertebral disk on right side. This was to our surprise as herniated disk typically reduces pain on sitting and is uncommon in older age group patients. However, this could explain rest of the clinical picture like motor weakness and distribution of pain. We conservatively managed the patient on oral pregabalin 75 mg two times a day and nortryptilline 10 mg two times a day. The natural history of

disk herniation has been demonstrated as high as 93% resolution in 24 months and from 58 to 88% in the 10 days to 6 months post-injury for lumbar disk herniations with radiculopathy. In elderly patients, the SLR test may be positive only in a minority of the patients with sciatica. Hence, negative SLR test in elderly patients with sciatica should not deviate the clinicians from diagnosis of the lumbar disk herniation.<sup>8</sup>

During the literature search, we encountered one report in which a case of thoracic disk herniation (T4/5 and T6/7) characterized by posture-related dynamic changes in neurological symptoms, i.e., numbness extending from the trunk to the entire lower limbs was deteriorated in the standing and sitting positions, was relieved in the supine position and disappeared in the prone position.<sup>9</sup>

## CONCLUSION

Degeneration of the intervertebral disk from a combination of factors can result in herniation. The presence of pain, radiculopathy, and other symptoms depends on the site and degree of herniation. Initial screening for red flag signs and monitoring for the development of significant complications such as neurologic defects, cauda equina syndrome, or refractory pain are essential in the management of lumbar disk herniation. This atypical presentation which includes absence of low back pain, absence of pain along the thigh, older age, and pain aggravating on sitting once again highlights the need to keep an eye open on all the possible causes of pain. It emphasizes that one should not exclude any clinical diagnoses unless proved.

## REFERENCES

1. Boxem KV, Cheng J, Patijn J. In: *Lumbosacral radicular pain* Zundert JV, ed. Evidence based interventional pain medicine. Wiley Blackwell; 2012.
2. Malik K. Low back pain. In: Benzon H, ed. *Practical management of pain*, 5th ed., Philadelphia: Elsevier Inc; 2014. p. 312.
3. Rammurthy. Evaluation of patient with back pain. In: Das G, ed. *Basics of pain management*, 2nd ed., New Delhi: CBS; 2017. p. 38.
4. Boxem KV, Cheng J, Patijn J. Lumbosacral radicular pain. *Pain Pract* 2010;10(4):339–358. DOI: 10.1111/j.1533-2500.2010.00370.x.
5. Murphy DR, Hurwitz EL, Gerrard JK, et al. Pain patterns and descriptions in patients with radicular pain: does the pain necessarily follow a specific dermatome? *Chiropr Osteopat* 2009. DOI: 10.1186/1746-1340-17-9.

6. Jensen MC, Brant-Zawadzki MN, Obuchowski N, et al. Magnetic resonance imaging of the lumbar spine in people without back pain. *N Engl J Med* 1994;331:69–73. DOI: 10.1056/NEJM199407143310201.
7. Yeung JT, Johnson JI, Karim AS. Cervical disc herniation presenting with neck pain and contralateral symptoms: a case report. *J Med Case Rep.* 2012;6:166. DOI: 10.1186/1752-1947-6-166.
8. Tabesh H, Tabesh A, Fakharian E. The effect of age on result of straight leg raising test in patients suffering lumbar disc herniation and sciatica. *J Res Med Sci* 2015;20(2):150–153.
9. Funayama T, Noguchi H, Abe T, et al. A case of thoracic disc herniation characterized by marked posture-related dynamic changes in neurological symptoms. *Interdiscip Neurosurg* 2018;14:1–4. DOI: 10.1016/j.inat.2018.05.015.