

CASE REPORT

Bipolar Radiofrequency Ablation of Genicular Nerves in Patients with Pacemaker

Ashok Jadon

ABSTRACT

Radiofrequency ablation (RFA) of genicular nerves (GN) provides good long-term pain relief in patients with knee joint pain. Unipolar RFA is commonly used technique, however, it is contraindicated in patients with implanted pacemaker due to risk of pacemaker failure and arrhythmia. We present a case report of two cases of genicular nerve RFA where bipolar RFA was used successfully in patients with permanent pacemaker to manage chronic knee pain. Both patients showed effective pain relief. Bipolar RFA was done uneventfully without any complication.

Keywords: Bipolar RFA, Genicular nerves, Knee pain, Pacemaker, Radiofrequency ablation.

How to cite this article: Jadon A. Bipolar Radiofrequency Ablation of Genicular Nerves in Patients with Pacemaker. *J Recent Adv Pain* 2015;1(2):97-99.

Source of support: Nil

Conflict of interest: None

INTRODUCTION

Chronic knee pain is common in all age groups. Some patients who fail conservative therapy benefit from radiofrequency neurotomy. Radiofrequency ablation (RFA) of genicular nerves (GN) provides good long-term pain relief in patients with knee joint pain.^{1,2} The common modality of RF used for knee genicular nerve ablation is unipolar technique,^{1,2} however, unipolar RF is contraindicated in patients with implanted pacemaker due to risk of pacemaker malfunction and arrhythmia.^{3,4} In patients with pacemaker bipolar electric cauterly is being used successfully, therefore, we hypothesized that bipolar RF can be used for RFA of genicular nerves. We present a case report of two cases where bipolar RF was used in patients with permanent pacemaker due to conduction defect in heart.

Chief Consultant and Head

Department of Anesthesia and Pain Relief Services, Tata Motors Hospital, Jamshedpur, Jharkhand, India

Corresponding Author: Ashok Jadon, Chief Consultant and Head, Department of Anesthesia and Pain Relief Services, Tata Motors Hospital, Jamshedpur-831004, Jharkhand, India, e-mail: jadona@rediffmail.com

CASE REPORTS

Case 1

A 64 years old male patient with chronic left knee pain was scheduled for RFA of genicular nerves after patient refusal for knee implant due to poor cardiac reserve and associated high risk for surgery. He was a known case of hypertension and ischemic heart disease (IHD). Medically, he was stable with well controlled blood pressure and without current episode of angina or syncope etc. He was on tablet losartan, aspirin, pregabalin, amitriptyline and tramadol with paracetamol. Permanent pacemaker was implanted due to repeated syncopal attacks one and half year back.

Case 2

A 56 years old female patient with pain in right knee due to osteoarthritis was advised RFA of genicular nerves due to side effects of analgesic drugs (gastric ulcer) and unwillingness for surgery. She was a known case of complete heart block and was on permanent pacemaker for more than 2 years. She was on tablet nifedipine retard, pregabalin, paracetamol and pantoprazole.

Technique

Patients were informed about the procedure and informed consent was obtained. As a first step, diagnostic block was given one week before the scheduled RFA with 2.0 ml lidocaine (1%) at all three tentative areas of genicular nerves under fluoroscopy.^{1,5} Both patients reported more than 80% reduction in pain on visual analog scale (VAS) which lasted for 3 to 4 hours only. During RFA preparation and procedure physician's help was taken regarding pacemaker status and necessary arrangements to manage any cardiac complications were done. Genicular RFA was done as done by standard three points technique used by Choi et al (Fig. 1).¹ However, in our technique second RF needle was inserted near the first needle at approximately 10 mm distance (Figs 2 and 3) and both needles were stimulated for 90 seconds at 80°C. Two cycles were completed by rotating the needles by 180°. Pain was assessed by Oxford knee score (OKS) (0 = no disability, 48 = total functional

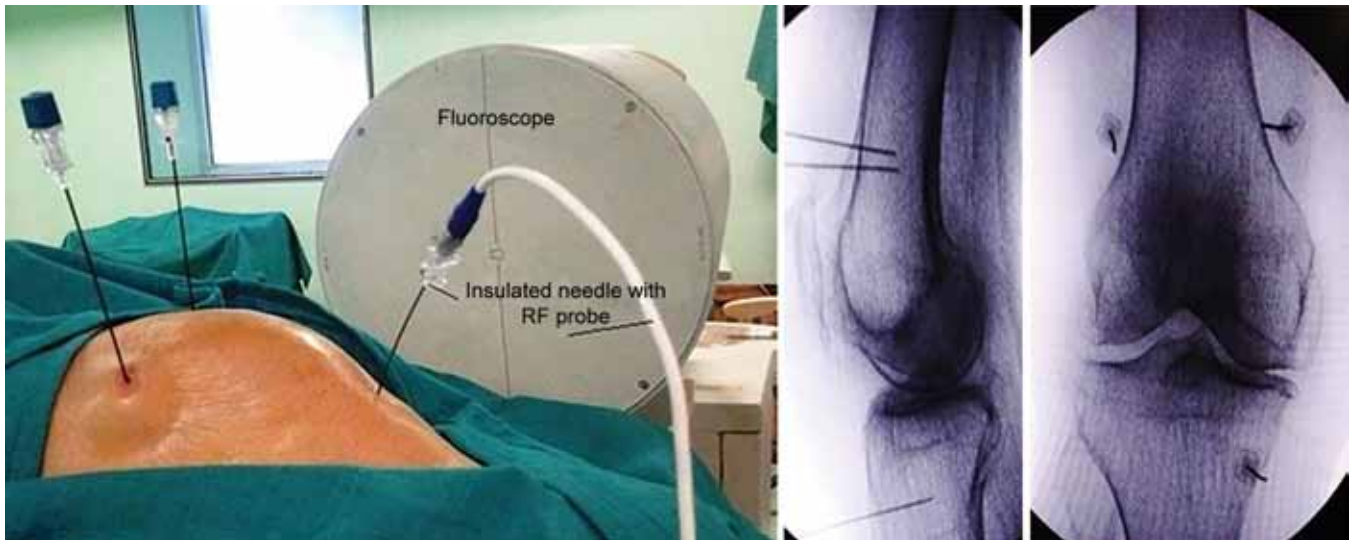


Fig. 1: Standard three needle technique with fluoroscopic image

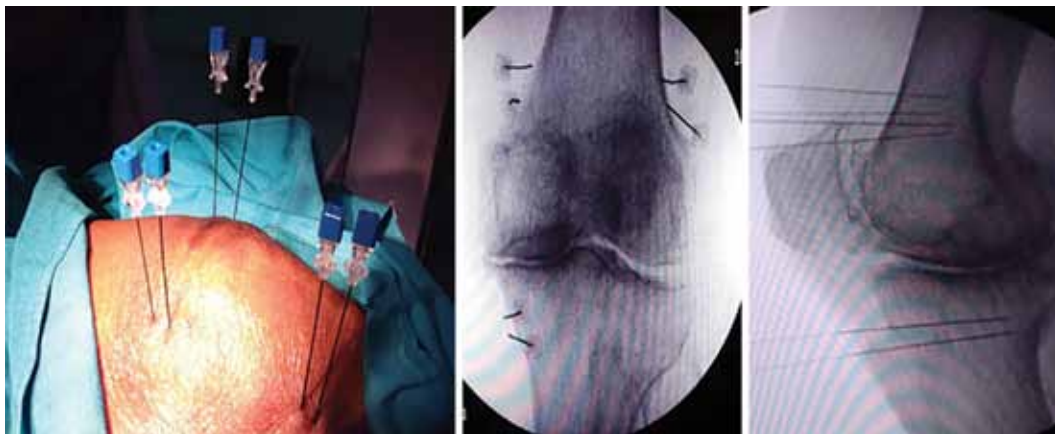


Fig. 2: Bipolar RF technique

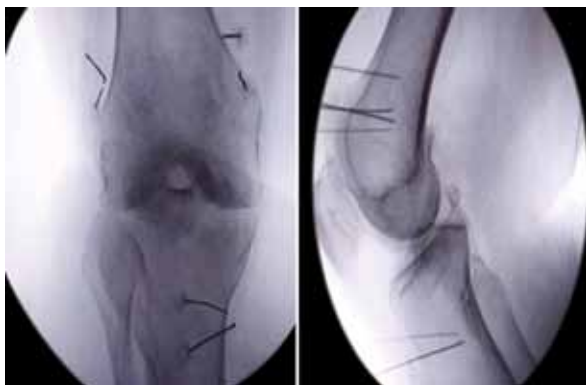

Fig. 3: Fluoroscopic image of bipolar RF needle placement

inability) and VAS (0 = no pain, 10 = worst pain) before and after the procedure at day-1, day-7, and at every month till 6 months (Table 1).

RESULTS

Oxford knee score and VAS showed marginal difference in results. Both patients on OKS showed 52 and 60% pain reduction till 3rd month (VAS 4/10 and 3/10), and 38 and 40% at end of 6th month (VAS 5/10 and 6/10) (Table 1). No intraoperative and post-procedure complications were noticed.

Table 1: Oxford knee score and VAS

		<i>*Baseline scores (before RFA)</i>	<i>One week</i>	<i>One month</i>	<i>2nd Month</i>	<i>3rd Month</i>	<i>4th Month</i>	<i>5th Month</i>	<i>6th Month</i>
Case 1	OKS	42	20	20	20	23	26	28	29
	VAS	9/10	3	3	3	4	4	6	5
Case 2	OKS	40	22	20	20	20	24	30	30
	VAS	9/10	2	3	4	3	5	6	6

*OKS (0–48) and VAS (0–10)

DISCUSSION

Genicular nerves are sensory nerves branches of the tibial, common peroneal and obturator nerves. They supply the capsule of the knee joint as well as the intra-articular and extra-articular ligaments. There are six genicular nerves around the knee however, due to anatomical reasons only three nerves are accessible to RFA. These nerves are superior medial and inferior medial branches from tibial nerve and superior lateral branch from common peroneal nerve.⁵ Due to emission of electromagnetic energy by radiofrequency generator RFA may result in variety of changes in pacemaker either during or after the treatment. Many functional aberrations like sensing failures, pacing failures, prolonged pauses, tachyarrhythmias and complete pacemaker inhibition have been reported due to electromagnetic interference (EMI).³ To avoid such complication American Society of Anesthesiologist (ASA) task force has given a practice advisory for the perioperative management of patients with cardiac implantable pacemakers.⁴ This advisory has given some suggestions like, deactivation of implanted generators during RFA, use of magnet over pacemaker, distance of grounding electrode 15 cm away from pacing leads, careful evaluation of pacing system during and after the procedure and use of bipolar electrocautery system if possible.⁴ Bipolar RFA has been used successfully to manage thoracic facet pain and sacroiliac joint pain either with intention to create larger lesions or due to difficult and variable anatomy of the target nerves.^{6,7} The use of bipolar RFA of genicular nerves for knee pain is not reported earlier, however, the safety of bipolar RFA in patients with pacemaker have been documented in other procedures.^{8,9} As other techniques to manage chronic knee pain have been found unsatisfactory in terms of prolonged pain relief¹⁰ and RFA of genicular nerves found effective not only in patients waiting for knee replacement^{1,2,11} but also even in patients who continue to have pain after arthroplasty.¹² Our patients made us to think 'out-of-the-box' to use bipolar RFA in presence of pacemaker but need for pain relief by RFA of genicular nerves. We used bipolar thermoablation technique wherein both RFA cannulas were kept approximately 10 mm away from each other and RFA was done at 80°C temperature for 90 seconds and RF cannula were rotated by 180° after completion of first cycle to get wide and consistent lesions.^{13,14} Both patients had effective pain relief without any technical difficulty or complications.

CONCLUSION

Two cases of chronic knee pain were managed successfully with bipolar RFA where conventional RFA was risky due

to implanted pacemaker. Experience with more number of cases is required before any recommendation can be made in favor of bipolar RFA for genicular nerve ablation.

REFERENCES

1. Choi WJ, Hwang SJ, Song JG, Leem JG, Kang YU, Park PH. Radiofrequency treatment relieves chronic knee osteoarthritis pain: a double-blind randomized controlled trial. *Pain* 2011;52:481-487.
2. Ikeuchi M, Ushid AT, Izumi M, Tani T. Percutaneous radiofrequency treatment for refractory anteromedial pain of osteoarthritic knees. *Pain Medicine* 2011;12:546-551.
3. Pfeiffer D, Tebbenjohanns J, Schumacher B, Jung W, Luderitz B. Pacemaker function during radiofrequency ablation. *Pacing Clin Electrophysiol* 1995;18:1037-1044.
4. Practice advisory for the perioperative management of patients with cardiac implantable electronic devices: pacemakers and implantable cardioverter-defibrillators: an updated report by the American Society of Anesthesiologists Task Force on Perioperative Management of Patients with Cardiac Implantable Electronic Devices. *Anesthesiology* 2011;114:247-261.
5. Franco CD, Buvanendran A, Petersohn JD, Menzies RD, Menzies LP. Innervation of the anterior capsule of the human knee: implications for radiofrequency ablation. *Regional Anesthesia and Pain Medicine* 2015;40:363-368.
6. Kim D. Bipolar intra-articular radiofrequency thermocoagulation of the thoracic facet joints: a case series of a new technique. *Korean J Pain* 2014;27:43-48.
7. Ferrante FM, King LF, Roche EA, Kim PS, Aranda M, Delaney LR, et al. Radiofrequency sacroiliac joint denervation for sacroiliac syndrome. *Reg Anesth Pain Med* 2001;26:137-142.
8. Ijuin S, Tamai T, Uto H, Onishi H, Sakae H, Muromachi K. Two patients with pacemakers who safely underwent radiofrequency ablation with bipolar electrodes to treat primary hepatocellular carcinoma. *KANZO* 2015;56:57-64.
9. Zollett R, Khan M, Okano D, Munir M. Bipolar radiofrequency ablation in the presence of pacemaker and peripheral nerve stimulator. Poster presented on February 14, 2008 at 24th Annual Meeting of American Academy of Pain Medicine in Orlando, Florida.
10. Cheng OT, Souzdamnitski D, Vrooman B, Cheng J. Evidence-based knee injections for the management of arthritis. *Pain Med* 2012;13:749-753.
11. Yi YS, Wang SJ, Liu CS, Yu JM, Kou DW. Effects of genicular nerve radiofrequency ablation combined with intra-articular injection of sodium hyaluronate on the treatment of refractory knee osteoarthritic pain. *Chinese J Pain Medicine* 2012;6:004.
12. Protzman NM, Gyi J, Malhotra AD, Kooch JE. Examining the feasibility of radiofrequency treatment for chronic knee pain after total knee arthroplasty. *PMR* 2014;6:373-376.
13. Cosman ER, Gonzalez CD. Bipolar radiofrequency lesion geometry: implications for palisade treatment of sacroiliac joint pain. *Pain Practice* 2011;11:3-22.
14. Gofeld M, Faclier G. Radiofrequency denervation of the lumbar zygapophyseal joints—targeting the best practice. *Pain Medicine* 2008;9:204-211.