

Pg Forum

REHAB CHALLENGES

A 68 years old female presented with severe low back pain and paraparesis for last two months. She also lost 3 kg weight during the same period. On examination we got lower motor type of weakness in L4, L5 distribution with intact bladder and bowel. Her x-ray lumbosacral spine (Fig 1) showed wedge compression and inflammatory markers were high (ESR 109 and CRP 42). Interestingly her chest x-ray (Fig 2) showed elevated right hemi diaphragm. USG of whole abdomen picked up heterogeneous mass 12×10.3cm and small satellite lesions limited to right lobe of liver. Mean while her MRI (Fig 3) picked up a right lower lobe consolidation and compression of cauda equina. So a final diagnosis of metastatic carcinoma with possible lung primary was made.

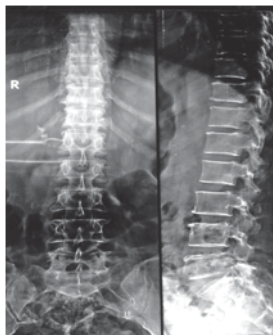


Fig 1

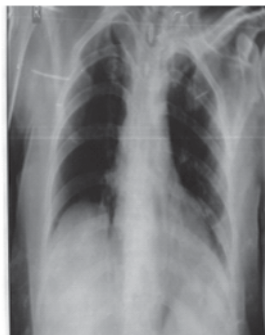

Fig 2

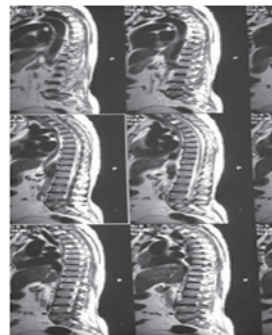


Fig 3

On conservative management with exercise schedule, spinal orthoses along with opiates her symptoms relieved little bit. The oncology team involved with active medical management. But still patient is quiet depressed and is in agony. She is desperate for ambulation as soon as possible.

Please opine regarding further rehabilitation plans for this patient.