

CASE REPORT

Esthetic Management of Misplaced Implant

¹Vaibhao I Shambharkar, ²Shweta R Sonare, ³Mitul K Mishra, ⁴Amber W Raut

ABSTRACT

Implant positioning plays an important role for giving esthetics as well as for proper functioning of the prosthesis. Accurate diagnosis and treatment planning are required for successful implant prosthesis. Improper positioning of implant creates esthetics and functional challenge for the prosthodontist. Adequate amount of bone is necessary for functional and esthetic reconstruction of soft-tissue architecture surrounding the implant. For axially placed malpositioned implant, prefabricated or custom-made angled abutments may be used to achieve functional and esthetic comfort. In case of apicocoronally placed implant, gingival ceramics can aid to create emergence profile surrounding the implant. Dental practitioners must have knowledge to create optimal soft-tissue profile surrounding the teeth and implant restorations. Improper positioning of implant not only increases the chances of repeat surgery but also gives psychological trauma to patients. This case report describes esthetic achievement for the patient with labial misplaced implant.

Keywords: Esthetics, Improper positioning of implant, Misplaced implant.

How to cite this article: Shambharkar VI, Sonare SR, Mishra MK, Raut AW. Esthetic Management of Misplaced Implant. *Int J Clin Implant Dent* 2015;1(3):104-106.

Source of support: Nil

Conflict of interest: None

INTRODUCTION

Accurate dental implant positioning in relation to alveolar bone and adjacent teeth plays an important role to protect health of the surrounding gingival tissue and the esthetics of the implant. Malpositioned maxillary anterior implant creates difficult situation for preserving

and reproducing natural mucogingival architecture surrounding it.^{1,2} Diagnosis and treatment planning play an important role for proper positioning and successful implant prosthesis.¹ Malpositioned implant and poorly fabricated definitive prosthesis can overload the implant system, can cause peri-implantitis, and finally lead to failure of the implant. In case of malpositioned implant, angulated abutment can be used to give accurate prosthesis. Some studies suggest that angled abutment can create stress on the supporting implants, adjacent bone, and the prosthesis.^{3,4} This case report describes the technique to give esthetics and to correct artificial gingival architecture surrounding the malpositioned implant.

CASE REPORT

A 42-year-old female referral from the oral surgery was reported to the Department of Prosthodontics, Government Dental College and Hospital, Nagpur, with implant placed in maxillary left central incisor region. Intraoral clinical examination revealed far buccally placed implant in maxillary left central incisor region (Fig. 1). The patient was concerned mainly for esthetics. Recontouring of the soft tissue was essential to achieve natural emergence profile, so according to treatment plan gingivectomy surrounding the implant was done. Open tray impression technique was used to make the final impression. Impression was made and the cast was obtained. Working cast was marked 1 mm wide around the implant site and scraped to a depth of 2 mm for fabrication of provisional restoration (Figs 2A to C). Cast scraping and fabrication of provisional restoration was

^{1,3,4}Assistant Professor, ²Private Practitioner

¹Department of Prosthodontics, Swargiya Dadasaheb Kalmegh Smruti Dental College and Hospital, Nagpur, Maharashtra, India

²Department of Dentistry, Vaibhao Dental Clinic, Nagpur Maharashtra, India

³Department of Periodontics, Swargiya Dadasaheb Kalmegh Smruti Dental College and Hospital, Nagpur, Maharashtra, India

⁴Department of Endodontics and Conservative Dentistry Swargiya Dadasaheb Kalmegh Smruti Dental College and Hospital, Nagpur, Maharashtra, India


Corresponding Author: Vaibhao I Shambharkar, Assistant Professor, Department of Prosthodontics, Swargiya Dadasaheb Kalmegh Smruti Dental College and Hospital, Nagpur Maharashtra, India, Phone: +919028404514, e-mail: vaibhao.shambharkar@gmail.com

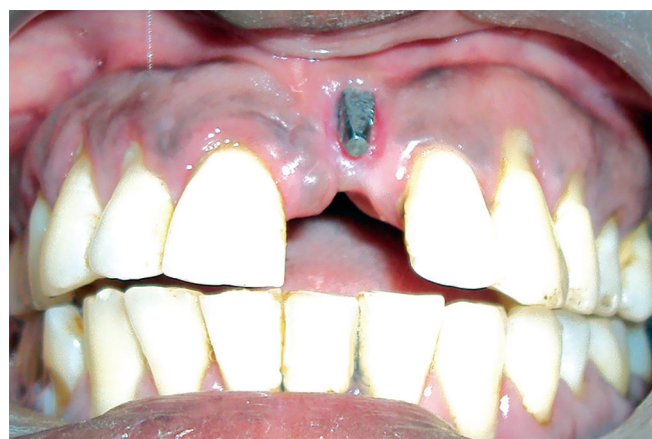
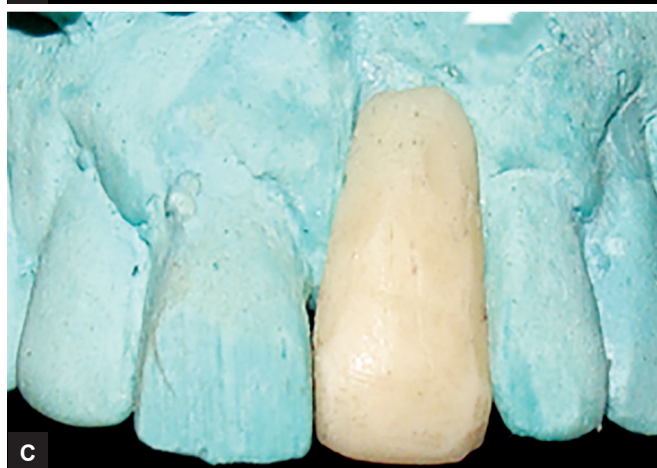
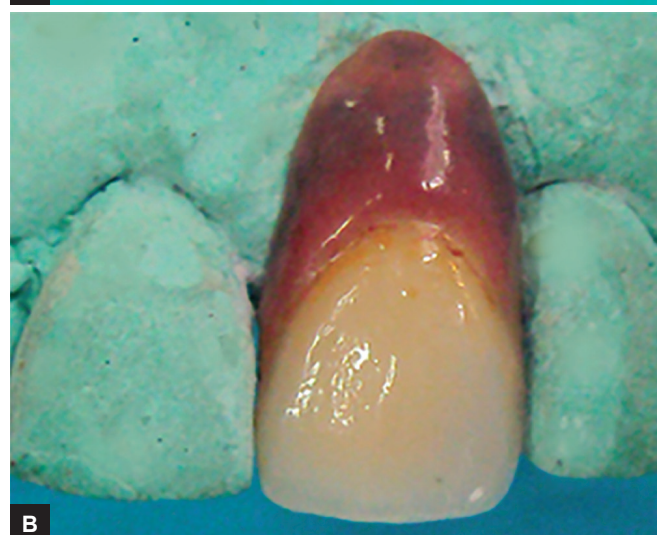Fig. 1: Labially misplaced implant



Figs 2A to C: (A) Labially misplaced implant, (B) cast scraping procedure, and (C) provisional restoration



Figs 3A and B: (A) Metal tryin, and (B) characterization using gingival porcelain

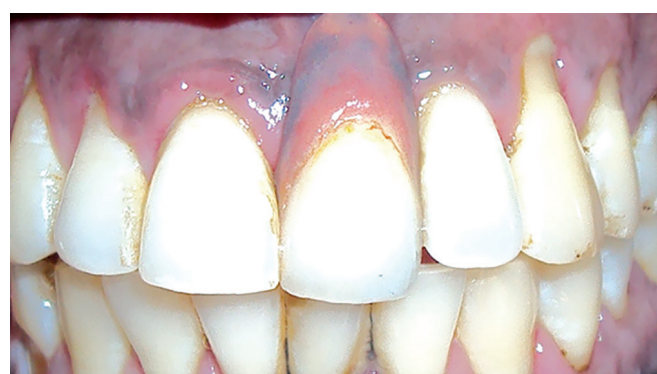

Fig. 4: Final restoration

repeated at a regular interval to create emergence profile surrounding the implant. The patient was recalled after 1, 3, and 6 months regularly to check the position of gingiva. After creating the emergence profile, final impression was made and metal coping was fabricated (Figs 3A and B). Shade selection was done and gingival porcelain was added to give esthetics to final restoration (Fig. 4).

DISCUSSION

Prosthetic replacement of teeth in maxillary anterior edentulous region with implant has become more challenging task for prosthodontist with rise of demands for esthetics and function. The following case report describes the treatment of a malpositioned osseointegrated, intruded, buccally placed dental implant.

There are several factors which are responsible for proper implant placement, such as fabrication of surgical stent, radiographic examinations, soft- and hard-tissue contours, selection of abutment, design of definitive prosthesis, and systemic condition of the patient.⁵ Management of misplaced implant requires accurate treatment planning. In case of extremely compromised cases, the treatment has been limited to surgical removal of misplaced implant followed by newer placement. However, surgical removal of the malpositioned implant often results in defects in bone and soft-tissue anatomy which requires subsequent surgical repair.⁶ In this case, implant position was too buccal in comparison with the remaining natural teeth. Two options were discussed with the patients: The first option was removal of the misplaced implant followed by fixed prosthesis or placement of newer implant in correct position. The second option was sequential molding of the gingiva surrounding the implant by using provisional restoration followed by permanent prosthesis. The patient was not convinced for the removal of misplaced implant. In case of misplaced implant, prefabricated or custom-made angled abutments may be used to restore esthetics, function, and comfort of the patient.^{3,4} But, here in this case, position of the implant has restricted the use of angulated abutment. Ideal soft-tissue emergence profile was achieved with the aid of a provisional restoration evaluated and recontoured at specific time intervals. Recontouring of the working cast facilitated application of controlled pressure around the tissue surface of the provisional restoration.⁷ This served the purpose of sculpting the tissues around the abutment to achieve the planned emergence profile.⁷ The tissue surface of the provisional restoration was polished at each interval to prevent plaque accumulation. The first provisional restoration was checked 1 month later. Gingival margin was lower surrounding the implant, so cast scraping procedure was repeated on the new working cast and a new provisional restoration was fabricated for proper gingival positioning surrounding the implant. Strict instruction regarding hygiene around the implant was given during the entire period of treatment procedure. The patient was recalled after 1-, 3-, and 6-month intervals to check the status of the hygiene maintained by the patient and the condition of the provisional restoration. Gingival harmony is an important element in the esthetics of the smile. Clinicians need to have the essential knowledge to create an optimal

soft-tissue profile around teeth and implant restorations. Poor shade selection for the prosthesis and lack of interdental papillae also account for implant esthetic failures.^{7,8} Thus, among the conditions considered essential for success in rehabilitation with dental implants, the prosthesis made over the implant has to be satisfactory to the clinician and patient. These include angled abutments and/or custom porcelain overcoat, artificial gingiva, elongated crowns, and secondary grafts.⁷ This article aims to demonstrate the correction of an esthetic problem caused by the improper positioning of a dental implant by sequential molding of the gingiva surrounding the implant.

CONCLUSION

For successful implant restorations, diagnosis and treatment planning play major roles. Every patient is concerned mainly for esthetics, so the clinician should try to achieve esthetics by applying basic knowledge and innovative techniques.

REFERENCES

1. Jivraj S, Chee W. Treatment planning of implants in the aesthetic zone. *Br Dent J* 2006 Jul;201(2):77-89.
2. Talwar BS. A focus on soft tissue in dental implantology. *J Indian Prosthodont Soc* 2012 Sep;12(3):137-142.
3. Sethi A, Kaus T, Sochor P. The use of angulated abutments in implant dentistry: Five-year clinical results of an ongoing prospective study. *Int J Oral Maxillofac Implants* 2000 Nov-Dec;15(6):801-810.
4. de Avila ED, de Molon RS, de Barros-Filho LA, de Andrade MF, Mollo Fde A Jr, de Barros LA. Correction of malpositioned implants through periodontal surgery and prosthetic rehabilitation using angled abutment. *Case Rep Dent* 2014;2014:702630.
5. Lin CL, Wang JC, Ramp LC, Liu PR. Biomechanical response of implant systems placed in the maxillary posterior region under various conditions of angulation, bone density, and loading. *Int J Oral Maxillofac Implants* 2008 Jan-Feb;23(1):57-64.
6. Misch K, Wang HL. Implant surgery complications: etiology and treatment. *Implant Dent* 2008 Jun;17(2):159-168.
7. Gupta A, Sahegal R, Tagore M, Patil PG, Kothari B, Puri S. Achieving desired esthetic outcome for a single tooth implant restoration with tissue excess using a multidisciplinary treatment approach: a clinical report. *J Prosthodont* 2011 Apr;20(3):228-232.
8. Deshpande S, Kumar DRV, Deshpande S, Gaikwad A, Chandra S. Aesthetic management of malpositioned implant following extraction of endodontically failed tooth. *Indian J Public Health Res Dev* 2012 Apr-Jun;3(2):173-175.