

## CASE REPORT

# Foreign Body Maxillary Antrum Masquerading as Osteomyelitis

<sup>1</sup>Sunil Kumar, <sup>2</sup>Hitendra P Singh, <sup>3</sup>Anupriya Hajela, <sup>4</sup>Abhishek B Singh, <sup>5</sup>Manish Chandra

## ABSTRACT

Foreign bodies in maxillary antrum, whatever their origin or nature, are unusual. Usually it presents as unilateral unexplained chronic rhinosinusitis and rarely as fistula over facial skin. The diagnosis is usually based on the history, proper examination, and radiological findings. Mostly foreign bodies are of dental origin, such as tooth roots, dental impression material, root-filling materials, dental implants, and burs. Foreign bodies in maxilla lodge during various procedures, but sometimes, there may be history of blast injuries and penetrating objects. We are reporting a special case of foreign body maxillary antrum that occurred during the road traffic accidents and was misdiagnosed and treated for a long time as osteomyelitis.

**Keywords:** Foreign body maxillary antrum, Osteomyelitis, Rhinosinusitis.

**How to cite this article:** Kumar S, Singh HP, Hajela A, Singh AB, Chandra M. Foreign Body Maxillary Antrum Masquerading as Osteomyelitis. *Int J Adv Integ Med Sci* 2018;3(1):51-53.

**Source of support:** Nil

**Conflict of interest:** None

## INTRODUCTION

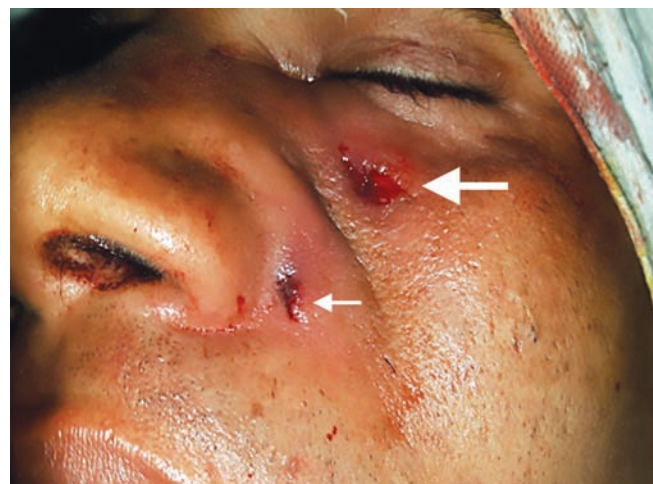Road traffic accidents and blast injuries are the two most common causes of facial trauma. Such type of accidents can cause penetration of foreign bodies in paranasal sinuses. Most of the foreign bodies of the paranasal sinuses are iatrogenic (60%), while accidents are involved in 25% cases.<sup>1</sup> Maxillary sinus is the most common site for foreign body lodgment.<sup>2</sup> Iatrogenic foreign bodies occur mostly due to dental procedures, such as implants, titanium plates, and gutta-percha.<sup>2,3</sup> Foreign bodies due to road traffic accidents are mostly wooden sticks, stone pieces, etc.<sup>1</sup> There are various presentations of such type of patients starting from sinusitis to osteomyelitis.

Metallic foreign bodies are sometimes diagnosed under routine radiological investigations.

## CASE REPORT

A 30-year-old male patient was referred to the outpatient department with discharging sinus over left side of cheek and foul smelling purulent nasal discharge for 1 month. Patient had mild pain and heaviness. He had history of road traffic accident 2 months back with some lacerated wound over left side face, which was healed after conservative treatment. On inspection, there were two small fistulous openings over left side face with purulent discharge. There was mild swelling and redness along with loss of sensations over left side of face (Fig. 1).

Anterior rhinoscopy showed left side deviated nasal septum with congested and edematous nasal mucosa. Routine hematological investigation was normal. Computed tomography scan revealed bony defect of the anterior wall of left maxillary antrum with heterogeneously hyperdense lesion of the maxillary antrum extending to left nasolabial fold suggestive of inflammatory with possibility of fungal element. Based on history, examination, and investigations, provisional diagnosis of osteomyelitis was made. As patient was continuously under conservative treatment without significant improvement, it was decided for proper debridement under general anesthesia. Maxillary antrum was opened using Caldwell–Luc approach (Fig. 2).



**Fig. 1:** Fistulous opening on the left side of face

<sup>1,2,5</sup>Associate Professor, <sup>3,4</sup>Assistant Professor

<sup>1,2,4,5</sup>Department of Otorhinolaryngology and Head and Neck Surgery, King George's Medical University, Lucknow, Uttar Pradesh, India

<sup>3</sup>Department of ENT, Bharat Ratna Dr. Babasaheb Ambedkar Municipal General Hospital, Mumbai, Maharashtra, India

**Corresponding Author:** Sunil Kumar, Associate Professor Department of Otorhinolaryngology and Head and Neck Surgery King George's Medical University, Lucknow, Uttar Pradesh India, Phone: +919415820661, e-mail: drsunil\_kumar123@rediffmail.com

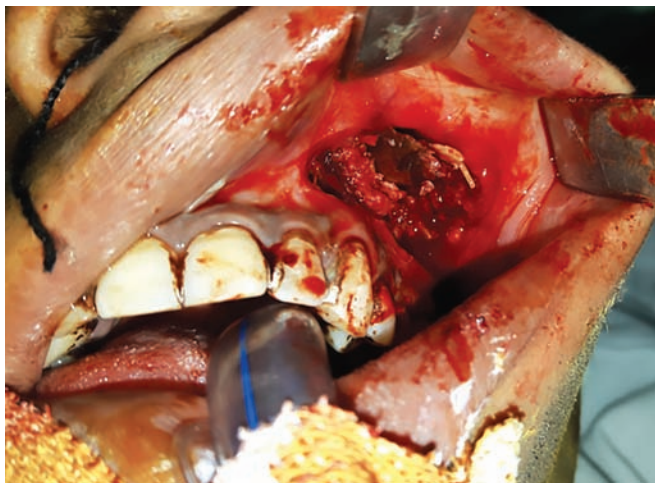


Fig. 2: Wooden piece in maxillary antrum

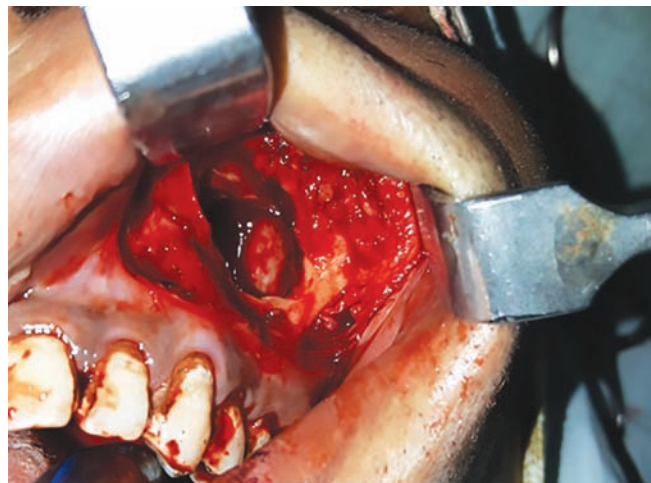

Fig. 3: Maxillary antrum after foreign body removal

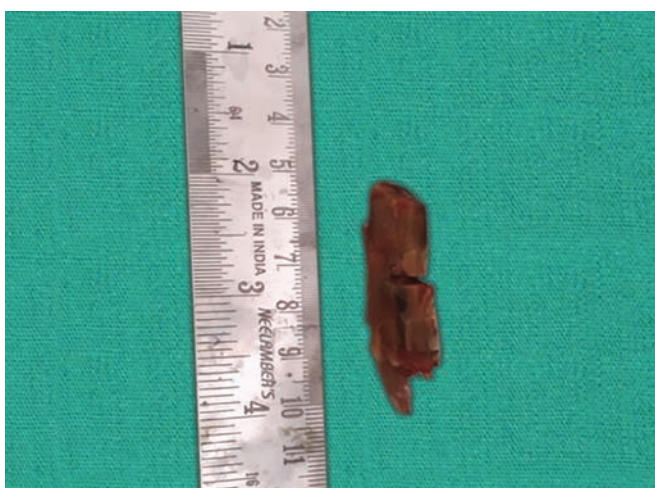

Fig. 4: Foreign body (wooden piece)

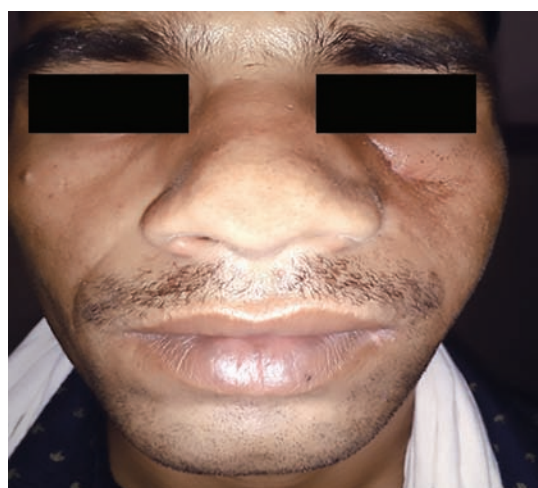

Fig. 5: Follow-up after 1 month

It was filled with wooden piece which was removed (Fig. 3) and antrum was cleared properly (Fig. 4).

Fistulous opening was freshened and sutured. Postoperative period was uneventful. Patient was followed up after 1 month with complete resolution of all the problems (Fig. 5).

## DISCUSSION

On review of literature, various types of foreign bodies are reported in maxillary antrum, mostly during dental procedures. Oroantral fistula following dental extraction is also one of the causes of foreign body lodgment in maxillary antrum. Signs and symptoms depend upon the nature of the foreign bodies and alteration of mucociliary clearance. Inert material and metallic foreign bodies usually present late and sometimes diagnosed incidentally on radiological investigations. Vegetative foreign body as in our case causes continuous irritation of antral mucosa and leads to sinusitis-like features.<sup>4</sup> Sometimes, severe symptoms like foul smelling nasal discharge, nasal stuffiness, swelling, and redness over

face may complicate the simple diagnosis and cases are misdiagnosed and mistreated for a long time without any significant improvement.

Patients presenting with history of trauma should undergo proper investigations to rule out foreign bodies, as cases have reported with symptoms of sinusitis after 12 years.<sup>5</sup> Diagnostic nasal endoscopy should be a part of work-up of patients. In our case, foul smelling discharge from nasal cavity, from fistulous opening over face, endoscopic examination, and radiological investigation pointed toward osteomyelitis maxilla. But due to unsatisfactory response to conservative treatment, it was decided to debride and later on diagnosed as foreign body maxilla.<sup>6</sup> It is very important to choose the approach, either endoscopic or Caldwell-Luc. As it was decided on complete debridement, Caldwell-Luc approach was used in our case. In pre-endoscopic stage, Caldwell-Luc approach was the gold standard for the maxillary antrum.<sup>7</sup> Sometimes it is preferred over endoscopy to properly visualize and irrigate the maxillary sinus, especially in large foreign body.<sup>8</sup>

## CONCLUSION

Foreign body must be kept in mind in patients presenting with unilateral maxillary sinusitis or features of osteomyelitis, especially when there is no response to conservative treatment. In such type of cases, detailed history about previous dental procedures, road traffic accidents, or blast injuries must be taken. Radiological investigation may clearly indicate about foreign body, but there is again confusion in cases of radiolucent foreign body. Endoscopic removal is the preferred choice initially, but it can be combined with Caldwell–Luc approach to increase proper visualization and to remove large foreign bodies.

## REFERENCES

1. Lima MM, Moreira CA, da Silva VC, de Freitas MR. 34 self-inflicted foreign bodies in the maxillary sinus. *Braz J Otorhinolaryngol* 2008 Nov-Dec;74(6):948.
2. Krause HR, Rustemeyer J, Grunert RR. Foreign body in paranasal sinuses. *Mund Kiefer Gesichtschir* 2002 Jan;6(1):40-44.
3. Liston PN, Walters RF. Foreign bodies in the maxillary antrum: a case report. *Aust Dent J* 2002 Dec;47(4):344-346.
4. Dobariya V, Sheikh KM, Shastri M, Desai S, Savani M. An unusual case of penetrating ocular trauma with a pressure cooker whistle. *Del J Ophthalmol* 2014 Mar;24(3):207-208.
5. Pang KP, Siow JK, Tan HM. Migration of a foreign body in the maxillary sinus illustrating natural mucociliary action. *Med J Malaysia* 2005 Aug;60(3):383-385.
6. Friedlich J, Rittenberg BN. Endoscopically assisted Caldwell-Luc procedure for removal of a foreign body from the maxillary sinus. *J Can Dent Assoc* 2005 Mar;71(3):200-201.
7. Kaushik S, Singh A, Karthikeyan A. Unusual foreign body in the maxillary antrum: a case report. *Internet J Otorhinolaryngol* 2009;12:2.
8. Smith II, Joseph L, Emko P. Management of a maxillary sinus foreign body (dental bur). *Ear Nose Throat J* 2007 Nov;86(11):677-678.