

# Morphological and Morphometric Study of Vermian Fossa

<sup>1</sup>Archana Singh, <sup>2</sup>Rakesh Gupta

## ABSTRACT

**Introduction:** Vermian fossa (VF) is also known as middle cerebellar fossa of Verga. It is present at lower part of internal occipital crest of occipital bone, over which inferior vermis of cerebellum lies. As very few studies are done on VF, so the present study was conducted.

**Objective:** To know the incidence, morphology, and morphometry of VF in adult human skulls.

**Materials and methods:** In the present study, 60 dry human skulls were examined for the presence or absence of VF, and shape and depth of VF. Morphometry of VF was done with digital Vernier caliper.

**Results:** In the present study, incidence of VF was 66.7% (in 40 skulls). Among observed VF (40), 32 (80%) were type I (triangular) and 8 (20%) were of type II (quadrangular) in shape, and 75% were shallow and 25% were deep. Average length of VF was  $16.98 \pm 4.3$  mm, and width was  $13.52 \pm 2.25$  mm.

**Conclusion:** In the present study, incidence of VF was quite higher than other studies but almost similar to other Indian studies. Although the sample size of the present study is less, this may provide some help to neurosurgeons, clinicians, and morphologist as the studies on VF are very less.

**Keywords:** Cerebellum, Occipital bone, Vermian fossa, Vermis.

**How to cite this article:** Singh A, Gupta R. Morphological and Morphometric Study of Vermian Fossa. Int J Adv Integ Med Sci 2017;2(4):198-200.

**Source of support:** Nil

**Conflict of interest:** None

## INTRODUCTION

Vermian fossa is also known as middle cerebellar fossa of verga.<sup>1</sup> It is a small depression at the lower part of internal occipital crest over which the inferior vermis of cerebellum lies.<sup>2</sup> On the inner aspect of occipital bone, a median elevation is present on the squamous part known as internal occipital crest which descends from internal occipital protuberance. Internal occipital crest gives attachment to falx cerebelli.<sup>3</sup> Internal occipital crest diverges around

the foramen magnum, and diverged limbs of it bounds a fossa, which may vary in shape and size.<sup>1</sup> Sometimes it may be divided by a bony ridge into upper and lower parts. Very little work has been done on morphometric and morphological aspects of the VF. Hence, the present study was aimed to determine the incidences of VF in the adult human dry skull.

## MATERIALS AND METHODS

In the present study, 60 dry adult human skulls were examined. The study was carried out in the Department of Anatomy and Forensic Medicine of Rohilkhand Medical College and Hospital, Bareilly, and Institute of Dental Sciences, Bareilly, Uttar Pradesh, India. Damaged bones were excluded from the study. Inner aspects of squamous part of occipital bone were examined for presence or absence of VF.

### Morphological Classification of VF

- According to the shapes, VF is classified as
  - *Type I:* Triangular
  - *Type II:* Quadrangular
  - *Type III:* Atypical (shapes other than types 1 and 2)
- According to the depth (shallow or deep)
  - *Morphometrically:* Length and width of VF were measured with the digital Vernier caliper (Fig. 1).
  - *Length:* From most superior to most inferior part of fossa (in mm)
  - *Breadth:* At the maximum point (in mm)
  - *Statistical analysis:* Done using Statistical Package for the Social Sciences, version 22.0.

## RESULTS

In the present study, total 60 skulls were observed and in 40 skulls (66.7%) VF was present and in 20 skulls (33.3%) it was absent (Graph 1). Among the 40 observed VF samples, 32 (80%) were triangular (type I) (Fig. 2 and

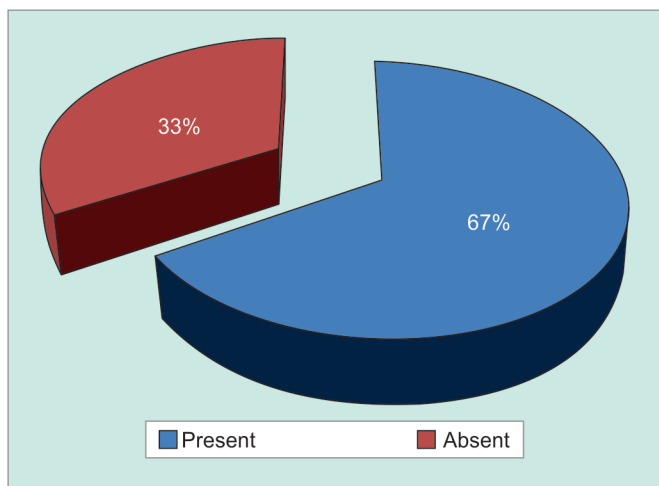
<sup>1</sup>Assistant Professor, <sup>2</sup>Professor

<sup>1,2</sup>Department of Anatomy, Rohilkhand Medical College and Hospital, Bareilly, Uttar Pradesh, India

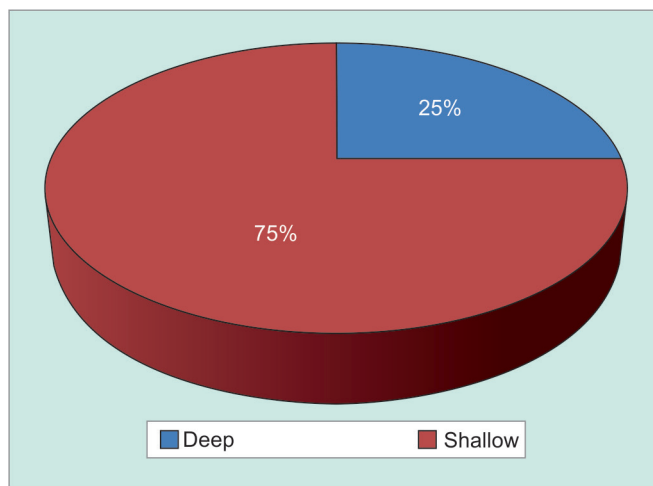
**Corresponding Author:** Archana Singh, Assistant Professor Department of Anatomy, Rohilkhand Medical College and Hospital, Bareilly, Uttar Pradesh, India, Phone: +919935462440 e-mail: drarchana279@gmail.com



Fig. 1: Digital Vernier caliper



Graph 1: Incidence of VF



Graph 2: Shapes of VF




Fig. 2: Triangular shape (type I VF)

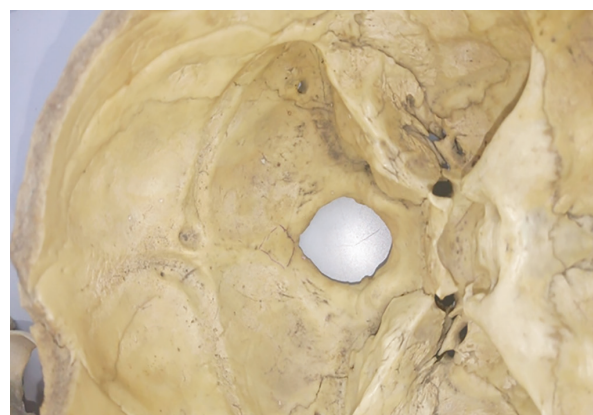


Fig. 3: Quadrangular shape (type II VF)

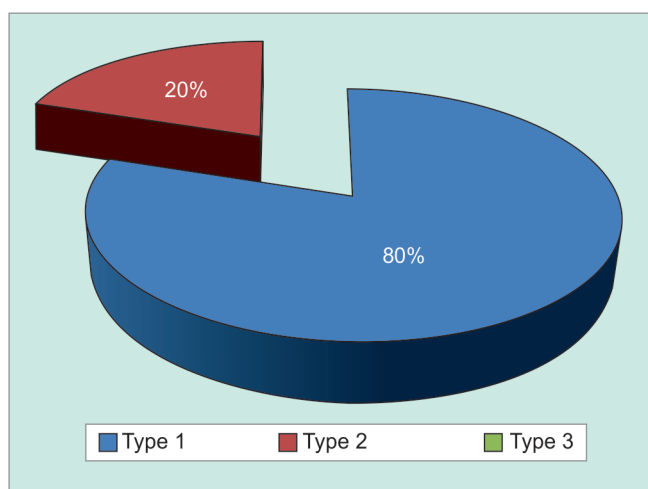
Table 1: Results showing incidence, morphometric and morphological characteristic of VF

Present	Absent	Shallow	Deep	Type I	Type II	Type III	AP length (mm)	Width (mm)
40 (66.7%)	20 (33.3%)	30 (75%)	10 (25%)	32 (80%)	8 (20%)	–	16.98 ± 4.54	13.52 ± 2.25

Graph 2) and 8 (20%) were quadrangular (type II) (Fig. 3 and Graph 2) in shape, and 30 (75%) were shallow and 10 (25%) were deep (Graph 3). On morphometric analysis of VF, average length was 16.98 + 4.54 mm, and width was 13.52 + 2.25 (Table 1).

**DISCUSSION**

On the internal surface of squamous part of temporal bone, internal occipital protuberance is present from where ridged sagittal and horizontal extension divides the internal surface of squamous temporal bone into four compartments. Upper two fossae accommodate the occipital pole of the cerebral hemisphere and lower two fossae are occupied by the cerebellar hemisphere. A prominent internal occipital crest gives attachment to falx cerebelli.<sup>4</sup> This internal occipital crest diverges and covers a V-shaped fossa dorsal to foramen magnum known as VF. It lodges the inferior cerebellar vermis, which includes tuber, pyramid, uvula, and nodule.<sup>4</sup>



Graph 3: Percentage of shallow and deep VF

Well-marked VF was reported in animals like lemur and marmoset and was absent in the macaque monkey and Cercopithecus by East.<sup>5</sup>

Berge and Bergman<sup>6</sup> reported the incidence of VF to be only 4% in their study, and no other details were studied, while Kale et al<sup>7</sup> reported 8.2% VF in Turkish skull and for the first time they classified the fossa morphologically into type I (triangular), type II (quadrangular), and type III (atypical). They noted 53.84% type I, 30.76% type II, and 15.38% as type III VF. While in the present study, incidence of VF was 66.7%, which is quite high.

Murlimanju et al<sup>8</sup> have found VF in 71.42% Indian human skulls, 76% were of type I, 8% of type II, and 16% of type III. Average length of VF was 13.6 mm, and breadth was 11.9 mm.

Yadav et al<sup>9</sup> and Ranjan et al<sup>10</sup> did similar studies on human skull. Yadav et al<sup>9</sup> found incidence of VF in 72.7% specimens, in 72.5% cases fossa was triangular (type I), in 10% quadrangular (type II), and in 17.5% shape of fossa was atypical (type III), while Ranjan et al<sup>10</sup> observed VF in 80% specimens, which is quite higher than in the present study. In 70.45%, bone shape of VF was triangular, in 7.95% quadrangular, and in 21.59% bones, it was atypical in shape. In the present study, in 80% the shape of fossa was triangular and in 20% cases it was quadrangular, while there was no atypical shape found.

Kale et al<sup>7</sup> measured the VF and found average length of fossa to be 27.8 mm, and width was 11.9 mm, while in the present study, length was 16.98 + 4.54 mm, which is lower than that reported by Kale et al,<sup>7</sup> and width was 13.52 + 2.25 mm, which is almost similar to that in Kale et al's study.<sup>7</sup> Comparisons between other Indian studies and the present study are shown in Table 2, measured findings of VF are almost similar to the present study (Table 2).

The anatomy of cerebellum along with vermis is of interest to many clinicians, and it has been reported that some cases of cerebellar cortical dysplasia are associated with vermian malformations.<sup>11</sup> So these data may be valuable in studies of diseases or malformations that cause change in shape and size of fossa.

**Table 2:** Comparison of morphological and morphometric findings of different studies

	<i>Kale et al<sup>7</sup></i>	<i>Murlimanju et al<sup>8</sup></i>	<i>Yadav et al<sup>9</sup></i>	<i>Ranjan et al<sup>10</sup></i>	<i>Present study</i>
VF	Turkish	Indian	Indian	Indian	Indian
Incidence (%)	8.22	71.40	72.70	80	66.7
Type I (%)	53.8	76	27.5	70.45	80
Type II (%)	30.80	8.00	10	7.95	20
Type III (%)	15.40	16	17.50	21.59	–
Average length (mm)	27.8	13.6	14.2	13.4	
Average breadth (mm)	18.4	11.9	12.1	12.1	

## CONCLUSION

The present study may provide some anatomical data to the neurosurgeons, clinicians, and morphologists on VF, as the studies on VF are very less. The data of the present study can be correlated with surgically relevant considerations. Detailed and accurate knowledge of the variability of the human morphology and morphometry improves the diagnosis and therapeutic performance. The clinician who operates intracranial images or interprets radiological images should be aware of the anatomical variations. The incidence of VF is higher in our study as compared with previous study and it might be because of racial variations. We believe that this study can also provide clue about the shape of the inferior cerebellar vermis. The present study might also help those who are involved with pathologies around foremen magnum, such as Arnold Chiari malformation. The future implication of this study includes correlation of the data with surgically relevant considerations.

## REFERENCES

- Bergman, RA.; Thompson, SA.; Afifi, AK.; Saadeh, FA. Compendium of human anatomic variation. Baltimore (MD): Urban & Schwarzenberg, 1988. p. 200.
- Poddar, S.; Bhagat, A. Handbook of osteology. 12th ed. Patna: Scientific Book Co; 2007. p. 43.
- Grant, JCB.; Basmajian, JV. Grant's method of anatomy. 7th ed. Baltimore (MD): The Williams & Wilkins Co.; 1965. pp. 720-721.
- Standring, S. Gray's anatomy, the anatomical basis of clinical practice. 39th ed. Elsevier: Churchill Livingstone; 2005. p. 353, 463-464.
- East CF. A rare abnormality of the occipital bone. J Anat 1926 Jul;60(Pt 4):416-417.
- Berge JK, Bergman RA. Variations in size and in symmetry of foramina of the human skull. Clin Anat 2001 Nov;14(6):406-413.
- Kale A, Öztürk A, Aksu F, Taskara N, Bayraktar B, Gurses IA, Zeybek FG, Gayretli O. Vermian fossa—anatomical study. J Ist Faculty Med 2008 Dec;71(4):106-108.
- Murlimanju BV, Prabhu LV, Sharmada KL, Saralaya VV, Pai MM, Kumar CG, Jiji PJ, Dhananjaya KV. Morphological and morphometric study of the "vermian fossa" in Indian human adult skulls. J Morphol Sci 2010;130(3):148-151.
- Yadav A, Chauhan K, Nigam GL, Sharma A, Yadav A. Morphological and morphometrical analysis of the vermian fossa in dry adult skulls of western Uttar Pradesh population: an osteological study. Int J Anat Res 2014 Sep;2(3):478-480.
- Ranjan RK, Kataria DS, Yadav U. Vermian fossa: an anatomical study of Indian human dry skull. Int J Health Sci Res 2015 Aug;5(8):238-242.
- Soto-Ares G, Delmaire C, Deries B, Vallee L, Pruvo JP. Cerebellar cortical dysplasia: MR findings in a complex entity. AJNR Am J Neuroradiol 2000 Sep;21(8):1511-1519.