

CASE REPORT

Tuberculosis of Middle Ear

¹Ankit Gulati, ²Vikas Kakkar, ³Chandni Sharma, ⁴Mohit Pareek, ⁵Surender Bishnoi

ABSTRACT

A 32-year-old female presented with a history of otorrhea and hearing loss in her right ear since 2 years. On examination, external auditory canal was found to be filled with polypoidal tissue along with mucopurulent discharge. Audiometry showed mixed hearing loss of 50, 55, and 60 dB with air-bone gap of 30, 35, and 40 dB at frequencies of 0.5, 1, and 2 kHz respectively. She was operated for the same, and biopsy was sent for histopathological examination, which showed granulomatous inflammation. The patient was treated with antituberculous therapy, and she responded fully to the treatment.

Keywords: Otorrhea, Pale granulation tissue, Tuberculous otitis media.

How to cite this article: Gulati A, Kakkar V, Sharma C, Pareek M, Bishnoi S. Tuberculosis of Middle Ear. *Int J Adv Integ Med Sci* 2017;2(2):104-105.

Source of support: Nil

Conflict of interest: None

INTRODUCTION

Tuberculosis (TB) can attack almost every organ in the human body and threatens millions of lives worldwide. Approximately one-third of total human population is infected by *Mycobacterium tuberculosis*.¹ India is the country with the highest burden of TB, with the World Health Organization statistics for 2013 giving an estimated incidence figure of 2.1 million cases of TB for India out of a global incidence of 9 million.² Tuberculosis can be pulmonary or extrapulmonary. Extrapulmonary contributes 12 to 15% of all cases of which middle ear TB constitutes less than 1%. The incidence of tuberculous otitis media (TOM) is 1.9 to 42.8 per million. *Mycobacterium tuberculosis* is the most common agent causing TB worldwide.¹

CASE REPORT

A 32-year-old female presented with a 2-year history of right-sided otorrhea and hearing loss. The discharge was insidious in onset, scanty, mucopurulent, nonfoul smelling, and occasionally stained with blood. Hearing loss was insidious in onset and gradually progressive. Otoscopy revealed edema of the external auditory canal with polypoidal tissue seen arising from the posterosuperior quadrant of tympanic membrane. Audiometry showed mixed hearing loss of 50, 55, and 60 dB with air-bone gap of 30, 35, and 40 dB at frequencies of 0.5, 1, and 2 kHz respectively. The patient was treated with topical and systemic antibiotics with no relief for which the patient was investigated and was diagnosed as diabetic. She was put on oral hypoglycemic agents, but there was no relief in discharge despite adequate blood sugar control. The discharge was sent for culture and sensitivity, which was reported sterile. As there was no relief in symptoms of the patient, modified radical mastoidectomy was performed. Intraoperatively, the middle ear was found to be filled with exuberant and pale granulation tissue, which was removed and sent for histopathological examination. The long process of incus was necrosed. Histopathological examination showed giant cells and macrophages with necrotic and calcified tissue (Fig. 1).

On the 10th postoperative day, external auditory canal was found to be filled with discharge along with gaping of the postauricular incision, which led to suspicion of the patient suffering from TOM. The patient was then investigated to rule out tuberculous etiology. Chest X-ray,

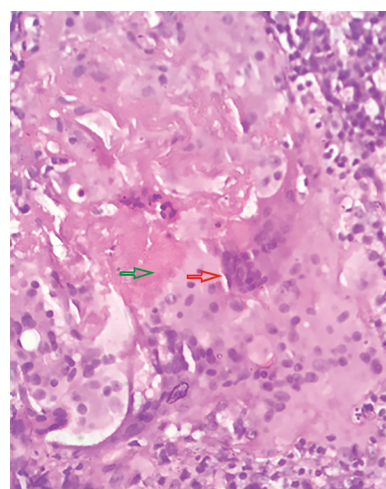


Fig. 1: Histopathological section showing giant cells (red arrow) and necrosis (green arrow) (hematoxylin and eosin, 40×)

¹Senior Resident, ²Senior Professor, ³Assistant Professor
⁴Junior Resident, ⁵Consultant

¹Department of ENT, Adesh Medical College & Hospital, Ambala Haryana, India

²⁻⁴Department of ENT, Pt. Bhagwat Dayal Sharma Post Graduate Institute of Medical Sciences, Rohtak, Haryana, India

⁵Haryana Civil Medical Services, Haryana, India

Corresponding Author: Ankit Gulati, Senior Resident Department of ENT, Adesh Medical College & Hospital, Ambala Haryana, India, e-mail: gulati.ankit07@gmail.com

Mantoux test, and sputum for acid-fast bacilli were done, which came out to be inconclusive. The patient was then put on category I antituberculous therapy (ATT). After 4 weeks of ATT, her ear was dry and the postauricular wound healed.

DISCUSSION

In developing countries, TB is very common. It is caused by *M. tuberculosis*, *Mycoplasma hominis*, and *Mycobacterium bovis*. *Mycoplasma hominis* and *M. bovis* species usually affect the ear.³ Tuberculosis of middle ear is rare and usually occurs due to infected cow's milk.⁴ In patients with known or suspected TB along with chronic middle ear infection, TOM should be suspected; however, lack of evidence of TB elsewhere does not exclude TOM possibility.⁵ Diabetes mellitus is a risk factor for active TB regardless of study design, the incidence of TB in the community, or the place of study.⁶ The risk of TB attributed to diabetes is 25%.⁷

Wallmer⁸ described classical features of TOM which includes painless otorrhea, pale granulation tissue, hearing loss (conductive, sensorineural, and mixed), ipsilateral facial nerve paralysis, multiple tympanic membrane perforation, and bony necrosis. Nowadays, chronic ear discharge, resistant to conventional antibiotic therapy, is the most frequent finding.¹ Jean Louis Petit first described TB of the temporal bone in the 18th century.⁹ Due to concurrent presence of other bacteria, bacteriological tests are often negative.¹ Local antibiotic treatment causes further masking of growth of *M. tuberculosis*. Ziehl-Neelsen staining is characterized by low sensitivity.¹⁰ Culture is more sensitive, but it is usually difficult to culture acid-fast bacilli in extrapulmonary TB. Histopathology is a more reliable diagnostic test.¹ Middle ear mucosal biopsy shows Langerhans giant cells, epithelioid cells along with caseous necrosis.¹¹ Tuberculous otitis media may be caused by three routes (hematogenous, Eustachian tube, and direct implantation). Radiological examination is nonspecific. Differential diagnosis may include chronic suppurative otitis media, Wegener's granulomatosis, histiocytosis X, sarcoidosis, and osteomyelitis.¹ Medical management is the treatment

of choice while surgical intervention is usually controversial. Surgery should be considered in cases where there is no definite clinical diagnosis, in patients presenting with complications, and for taking biopsy. Cho et al¹⁰ have reported better results in patients who have undergone surgery followed by ATT as compared with nonoperated patients with TOM.¹

CONCLUSION

Tuberculous otitis media should be suspected in patients with a continuously discharging ear, not responding to antibiotics. The suspicion should be raised in patients with a co-immunosuppressant condition, such as diabetes, as they are more prone to develop TB. Antituberculous therapy is the main line of treatment, with surgery being reserved for complications mainly.

REFERENCES

1. Liktar B, Liktar B, Liktar B Jr, Kalman J, Horvath B, Sziklai I, Karosi T. Primary tuberculosis of the middle ear cleft: diagnostic and therapeutic considerations. *Eur Arch Otorhinolaryngol* 2014 Jul;271(7):2083-2089.
2. World Health Organization. Global tuberculosis report 2014. Geneva: World Health Organization; 2014.
3. Miracle LS, Ayala I, Suárez JF, Malagón J, Nellen H, Halabe J, Piscioti L. Otitis media tuberculosa. *An Med Assoc Med Hosp ABC* 2005;50(1):30-34.
4. Mahajan M, Agrawal DS, Singh NP, Gadre DJ. Tuberculosis of middle ear – a case report. *Ind J Tub* 1995;42:55.
5. Kirsch CM, Wehner JH, Jensen WA, Kagawa FT, Campagna AC. Tuberculous otitis media. *South Med J* 1995 Mar;88(3):363-366.
6. Jeon CY, Murray MB. Diabetes mellitus increases the risk of active tuberculosis: a systematic review of 13 observational studies. *PLoS Med* 2008 Jul;5(7):e152.
7. Deshmukh PA, Shaw T. Pulmonary tuberculosis and diabetes mellitus. *Ind J Tub* 1984;31:114-117.
8. Wallmer LJ. Tuberculous otitis media. *Laryngoscope*. 1953; 63:1058-77.
9. Plester D, Pusalkar A, Steinbach E. Middle ear tuberculosis. *J Laryngol Otol* 1980 Dec;94(12):1415-1421.
10. Cho YS, Lee HS, Kim SW, Chung KH, Lee DK, Koh WJ, Kim MG. Tuberculous otitis media: a clinical and radiological analysis of 52 patients. *Laryngoscope* 2006 Jun;116(6):921-927.
11. Linthicum FH, Jr. Tuberculous otitis media. *Otol Neurotol* 2002;23:235-236.