

IMAGES IN HYPERTENSION

Fibromuscular Dysplasia of Renal Artery

Kakarla S Rao

ABSTRACT

Fibromuscular dysplasia (FMD) of the renal artery is one of the etiological factors of secondary hypertension. The etiology is unknown. Conventional radiography is ideal when interventional methods are planned. The beaded appearance is the typical appearance of FMD on angiogram.

Keywords: Fibromuscular dysplasia, Idiopathic, Nonatherosclerotic.

How to cite this article: Rao KS. Fibromuscular Dysplasia of Renal Artery. *Hypertens J* 2016;2(2):103-104.

Source of support: Nil

Conflict of interest: None

INTRODUCTION

A 35-year-old female was diagnosed with new-onset hypertension. Due to significant elevation in blood pressure and her age, the possibility of "secondary" hypertension was considered.^{1,2} Work-up revealed unilateral right renal artery stenosis due to fibromuscular dysplasia (FMD). The angiogram shown in Figure 1 is the typical appearance of FMD. For reasons not firmly known, FMD is more common in women than in men. Hormonal etiology may be a factor but not established. Fibromuscular dysplasia of renal arteries should be suspected in women with new onset or severe hypertension. The condition responds favorably to percutaneous transluminal angioplasty.³⁻⁵

Fibromuscular dysplasia is an idiopathic, segmental, noninflammatory and nonatherosclerotic disease that can affect all layers of both small and medium caliber arteries. The exact etiology is not known and the pathophysiology is vague. This occurs predominantly in young women of child-bearing age and is often unilateral. It may be familial. Routine laboratory investigations are usually nonproductive, but in long-standing cases, renal impairment may be noted. Pathologically, FMD is classified into three main types: Intimal, medial, and adventitial. Conventional radiography may not be helpful. Color

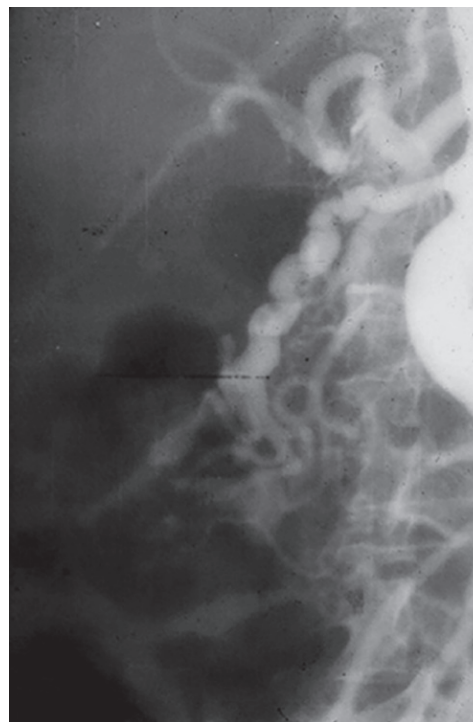


Fig. 1: Typical appearance of FMD

ultrasonography is helpful but it is not good for management. Computed tomography and magnetic resonance imaging are quite helpful. Conventional angiography is ideal in case interventional methods are to be adopted.^{3,6-8}

REFERENCES

1. Slovut DP, Olin JW. Fibromuscular dysplasia. *N Engl J Med* 2004 Apr 29;350(18):1862-1871.
2. Olin JW, Gornik HL, Bacharach JM, Biller J, Fine LJ, Gray BH, Gray WA, Gupta R, Hamburg NM, Katzen BT, et al. Fibromuscular dysplasia: state of the science and critical unanswered questions: a scientific statement from the American Heart Association. *Circulation* 2014 Mar 4;129(9):1048-1078.
3. Savard S, Steichen O, Azarine A, Azizi M, Jeunemaitre X, Plouin PF. Association between 2 angiographic subtypes of renal artery fibromuscular dysplasia and clinical characteristics. *Circulation* 2012 Dec 18;126(25):3062-3069.
4. Smit JV, Wierema TK, Kroon AA, de Leeuw PW. Blood pressure and renal function before and after percutaneous transluminal renal angioplasty in fibromuscular dysplasia: a cohort study. *J Hypertens* 2013 Jun;31(6):1183-1188.
5. Olin JW, Froehlich J, Gu X, Bacharach JM, Eagle K, Gray BH, Jaff MR, Kim ES, Mace P, Matsumoto AH, et al. The United States Registry for Fibromuscular Dysplasia: results in the first 447 patients. *Circulation* 2012 Jun 26;125(25):3182-3190.

Chairman

KIMS Foundation Research Centre, Krishna Institute of Medical Sciences, Secunderabad, Telangana, India

Corresponding Author: Kakarla S Rao, Chairman, KIMS Foundation Research Centre, Krishna Institute of Medical Sciences Secunderabad, Telangana, India, Phone: +9104023563155 e-mail: subbaraokakarla25@gmail.com

6. Lüscher TF, Keller HM, Imhof HG, Greminger P, Kuhlmann U, Largiadèr F, Schneider E, Schneider J, Vetter W. Fibromuscular hyperplasia: extension of the disease and therapeutic outcome. Results of the University Hospital Zurich Cooperative Study on Fibromuscular Hyperplasia. *Nephron* 1986;44 (Suppl 1):109-114.
7. Olin JW, Pierce M. Contemporary management of fibromuscular dysplasia. *Curr Opin Cardiol* 2008 Nov;23(6):527-536.
8. Trinquart L, Mounier-Vehier C, Sapoval M, Gagnon N, Plouin PF. Efficacy of revascularization for renal artery stenosis caused by fibromuscular dysplasia: a systematic review and meta-analysis. *Hypertension* 2010 Sep;56(3):525-532.