

Comparison between Acetal Resin and Cobalt-chromium Removable Partial Denture Clasps: Effect on Abutment Teeth Supporting Structures

¹Tarek Mohamed, ²Osama Abdulmoneam Baraka, ²Magdy Mostafa Badawy

¹Dental Prosthesis, Department of Dentistry, Dental Center, King Fahd Hospital, Saudi Arabia

²Professor, Department of Removable Prosthodontics, Faculty of Dental Medicine, Al-Azhar University, Cairo, Egypt

Correspondence: Tarek Mohamed, Dental Prosthesis, Department of Dentistry, Dental Center, King Fahd Hospital, Medina El Munawara, Saudi Arabia, Phone: 00966-530970800, e-mail: tarook62@hotmail.com

ABSTRACT

Statement of problem: Acetal resin has been introduced as an esthetic partial denture clasp material. However, the effects of these clasps on the abutment teeth supporting structures were not clear.

Purpose: To evaluate the effects of acetal resin clasps on the abutment teeth supporting structures as compared to cobalt-chromium clasps.

Materials and methods: Twenty patients, 12 males and 8 females, with Kennedy class III modification I partially edentulous maxilla and dentulous mandibles were selected for this study. Patients were divided into two equal groups; group 1 received maxillary cobalt-chromium partial denture frameworks with acetal resin Akers clasps. Group 2 received maxillary partial denture with cobalt-chromium frameworks and Akers cobalt-chromium clasps. Crevicular fluid, epithelial attachment loss, and bone height and density of the abutment teeth were evaluated at partial denture insertion and after 6 and 12 months. Paired t-test was used at $p \leq 0.05$ to assess the changes in the above parameters in each group. Student t-test was used to compare between the two groups.

Results: Crevicular fluid measurements were significantly higher in the first group than that in the second group. There were no differences in epithelial attachment loss between the two groups. There were significantly higher reductions in the bone height and in the bone density in the second group than that in the first group.

Conclusion: Acetal resin clasps were superior to cobalt-chromium clasps as produced fewer reductions in bone height and in bone density around the abutment teeth inspite of produced increase in the crevicular fluid.

Clinical implications: Since there were lesser reductions in bone height and in bone density around acetal resin clasp abutments, it could be used successfully to retain partial dentures. However, meticulous oral hygiene and proper insertion and removal of partial denture with acetal resin clasps were required to decrease gingival inflammation and crevicular fluid amount.

Keywords: Cobalt-chromium, Removal partial denture, Acetal resin.

INTRODUCTION

Fabricating an esthetically pleasing removable partial denture while avoiding the unsightly display associated with conventional clasp assemblies presented a challenge to dentists. Among other techniques, this could be done using acetal resin clasps as simple and effective means of improving removable partial denture esthetics.¹

Patients often cite lack of retention and poor esthetics as reasons for not wearing their partial dentures. Traditional metal alloy clasps have been shown to exert forces on abutment teeth that exceed those capable of producing tooth movement. In addition, metal display on anterior teeth is often unacceptable. The technopolymer materials were purported to have superior flexibility and exerted less force than the metals on the abutment teeth. These forces fell within the physiological range of those abutments and considered safe for use. This coupled with their pleasing esthetics made them suitable for use on periodontally

compromised teeth, those with deep undercuts and on anterior teeth.²

Acetal resin is being marketed for the construction of retentive and supportive components of removable partial dentures. The material has a flexural modulus lower than that of polymethylmethacrylate and is insufficiently rigid to be used as a supporting element for partial dentures. Acetal resin clasps may be resilient enough to engage undercuts for the retention of removable partial dentures but the low flexural modulus requires that the resin be used in greater cross-sectional area than metal alloys in order to gain useful retention. This greater bulk has implications for plaque accumulation and maintenance of periodontal health.³

The use of removable partial denture creates the potential for quantitative and qualitative changes in plaque formation on the remaining teeth and thereby increases the risk for development of gingivitis and periodontitis. If plaque control

is established, orthodontic forces will not cause periodontal damage even if the periodontal supporting tissues are markedly reduced. But in the presence of plaque, the same forces may aggravate the process of periodontal breakdown.⁴

Partial denture clasps can cause local irritation. Forces transmitted by the clasps may cause destruction to the periodontium. Clasps change the flow of food over the tooth surface disrupting the self-cleansing action and preventing the mucus of the lips, tongue and cheeks from measuring the gingival tissues.⁵

Ninety-two patients were examined after placement of removable partial dentures. No clinical significant changes in tooth mobility or sulcus depth were shown after 2 years analysis. Significant higher gingival inflammation levels and higher caries incidence were found in the abutment teeth. These findings were consistent with higher plaque levels presented at the covered surfaces. With regular oral and prosthetic care the patients could exhibit lower plaque and gingival inflammation levels than were recorded.⁶

Five studies had been carried out with the aim of evaluating the effect of removable partial denture on remaining teeth. All these studies agreed that the periodontal conditions of the teeth adjacent to the dentures were poorer than around those not directly involved in its construction due to food stagnation and difficult oral hygiene caused by the removable partial denture components. In addition, removable partial denture might sink into the soft tissues causing bone resorption; and bars and clasps might impinge the gingiva.⁷

The periodontal diseases in removable partial denture wearers were investigated. It was found that removable partial dentures increased the risk of periodontal diseases around the teeth involved in its support and retention because denture components encourage food stagnation and plaque accumulation.⁸

A clinical survey of cobalt-chromium removable partial denture wearers was conducted to investigate the effects of denture wearing on oral tissues. A random sample of patients who had received their dentures 5 to 6 years previously was selected. Those who had been constantly wearing the removable partial dentures were examined by one calibrated examiner under an optimal clinical setting. The patients' dental, periodontal and mucosal statuses were assessed. Mucosal lesions under the cobalt-chromium removable partial dentures were uncommon in this study sample. However, a high prevalence of plaque, gingivitis, and gingival recession were found especially in dentogingival surfaces in close proximity (within 3 mm) to the dentures. Thus, there was a special need for regular oral hygiene reinforcement, scaling and prophylaxis among removable partial denture wearers.⁹

MATERIALS AND METHODS

Crevicular fluid, epithelial attachment loss, and bone height and density were used as parameters to make a comparison between acetal resin and cobalt-chromium removable partial

denture clasps of the same dimensions regarding their effects on abutment teeth supporting structures.

Twenty patients 12 males and 8 females with Kennedy's class III modification I partially edentulous maxilla and dentulous mandible were selected for this study. The patients were divided into two equal groups. For the first group, the patients received maxillary partial denture with metallic cobalt-chromium frameworks and acetal resin clasps (Pressing di Monticelli Rag. Stefano – 47046 Misano Adriatico – Italy). For the second group, the patients received maxillary partial denture with metallic cobalt-chromium frameworks and cobalt-chromium clasps (METAPLUS VP – Germany). Maxillary premolar was used as anterior abutment and maxillary molar was used as posterior abutment on both sides for construction of maxillary removable partial denture (Figs 1 and 2). Clinical examination of the maxillary partial denture abutments showed that it was free from caries, gingival inflammation, periodontal pockets, and there was no tooth mobility. By X-ray evaluation the partial denture abutments were free from periapical or periodontal pathosis. The selected patients were free from systemic diseases that may affect the alveolar bone condition. Full mouth scaling and root planning were performed to all patients, and they were instructed for proper oral hygiene and

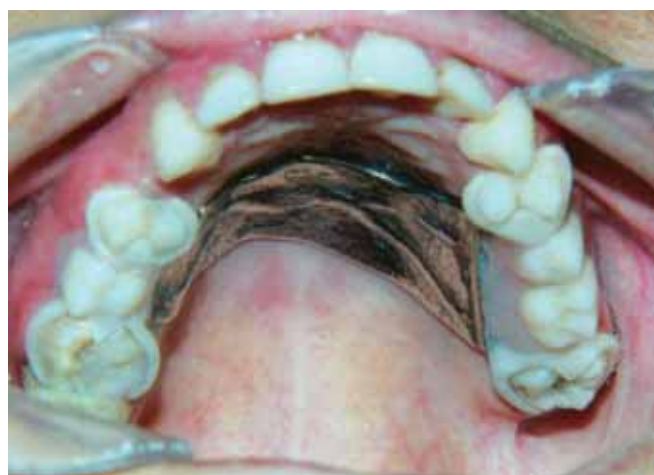

Fig. 1: Upper partial denture with acetal resin clasps in patient's mouth

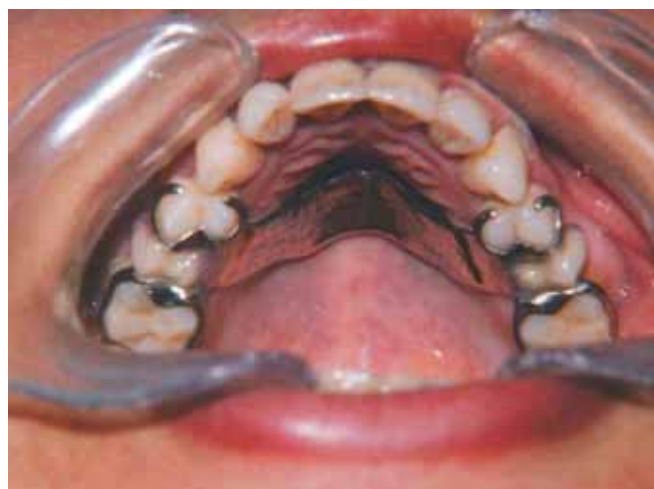

Fig. 2: Upper partial denture with cobalt-chromium clasps in patient's mouth

home care using toothbrush and dental floss. Crevicular fluid, epithelial attachment loss, and bone height and density were measured around the maxillary partial denture abutments at the time of partial denture insertion, 6 and 12 months from insertion.

Measuring the Crevicular Fluid

It was collected using Whatman filter papers number one. The filter papers were cut in strips of 3 mm width and 10 mm length. The area around each abutment was isolated by cotton rolls and dried gently by dry air. The strips were placed at the orifices of gingival crevices of buccal and palatal surfaces of the abutments and left in place for three minutes. The strips were removed and immediately inserted in 2% ninhydrin solution for 1 minute and kept to dry.¹⁰ The areas of the strips which stained dark purple indicated the amount of the collected crevicular fluid. The surface area of the strip which stained dark purple was measured by using square millimeter graduated transparent paper superimposed over the stained filter paper. The stained area was traced on the graduated transparent paper and the number of the square millimeters was calculated and approximated to half square millimeter. The mean surface areas of the tested teeth were calculated and recorded (Figs 3 and 4).

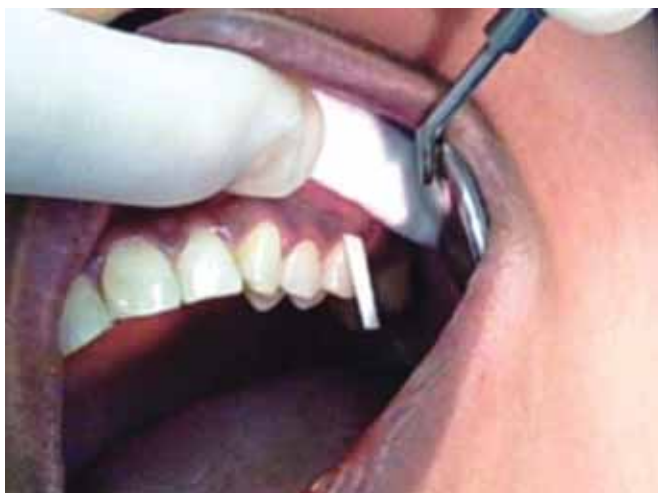

Fig. 3: Collection of the crevicular fluid sample




Fig. 4: Measuring of surface area of collected crevicular fluid

Measuring the Epithelial Attachment Loss

Two composite resin dots 4 mm away from the free gingival margin were done on the midbuccal and midpalatal surfaces of the maxillary partial denture abutments to be used as fixed reference points for measuring of the epithelial attachment loss. It was measured in mm from the cemento-enamel junction under the composite resin dot on each surface to the base of the pocket. All measurements were done by using of William's graduated periodontal probe (Ash, Detray, England). The mean epithelial attachment loss of the premolars and molars abutments was calculated and recorded (Fig. 5).

Measuring Bone Height and Density

Charged-coupled device system (RVJ – AET, ARDET, s.r.i., Milano, Italy) consisted of an electronic chip used as a sensor for the radiation with a cable connected the sensor to the computer and the image was displayed immediately on the computer monitor after exposure, Orix X-ray machine (Orix – AET, ARDET, s.r.i., Milano, Italy), Rinn XCP periapical film holder (Rinn Corporation, XCP instrument, USA), and an individually constructed radiographic acrylic template were used for making standardized digital images for the anterior and posterior maxillary partial denture abutments following the long cone paralleling technique.¹¹ The template was designed to receive the Rinn XCP film holder in a position palatal to the anterior and posterior abutments and parallel to their long axes. The radiographic template with the bite block carrying the sensor chip was inserted in the patient's mouth. The bite block was assembled to the plastic aiming ring at the end of the cone by means of the indicator arm. The electronic sensor chip was exposed by the Orix X-ray machine at 65 kilovolt, 10 milliamperere for 0.2 second. The stored images of each patient were interpreted at the end of the follow-up period by one examiner at two different times to decrease intra- and interobserver errors and the means of the two trials were recorded. The linear measurement system supplied by the Digora software (Orion Corporation, Soredex, Finland) was

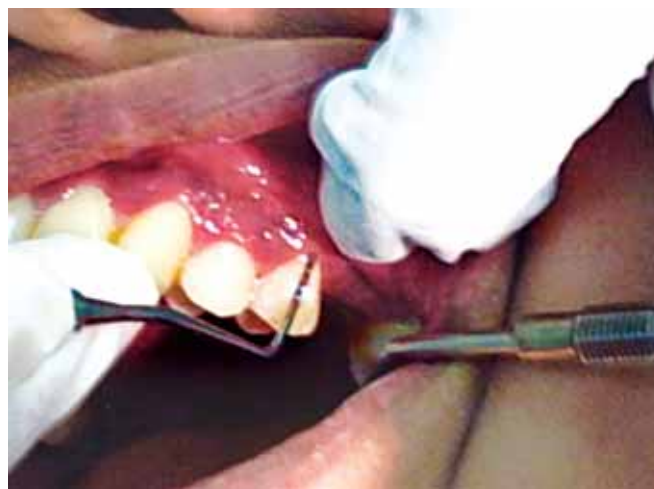

Fig. 5: Measuring of the epithelial attachment loss

used for assessing the mesial and the distal marginal bone height around the anterior and the posterior maxillary partial denture abutments. Parallel lines to the long axis of the mesial and the distal surfaces of each abutment were made. At each site the evaluation was made by measuring the distance in mm from the crest of the alveolar bone to the apex of the tooth. The changes in the bone height in the subsequent measurements were calculated. The mean changes of the mesial and distal bone heights of the premolars and molars were considered as the bone changes of that patient. The software of the Digora system was used for evaluation of the changes in the bone density mesially and distally to the anterior and the posterior maxillary partial denture abutments. This was done by making a line on the mesial and a line on the distal surfaces of each maxillary partial denture abutment. The line extended from the crest of the alveolar ridge to the apex of the tooth and passed adjacent to the space of the lamina dura parallel to the surface of the root. The value indicating bone density along each line was recorded and the mean value of all abutments readings was calculated (Figs 6 to 8).



Fig. 6: The radiographic template with the Rinn XCP bite block and film holder carrying the sensor chip

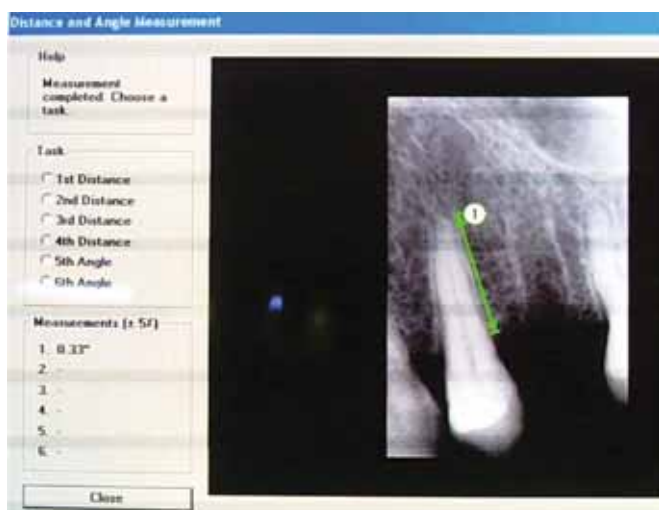

Fig. 7: Linear measurements of the alveolar bone height with the Digora software

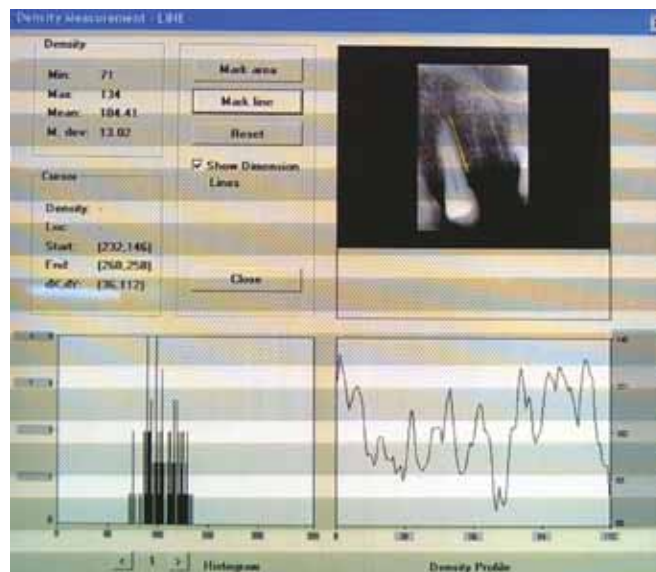


Fig. 8: Densitometric measurement of the alveolar bone with the Digora software

Statistical analysis was carried out using the statistical analysis system program (SAS). Paired t-test was used at $p \leq 0.05$ to assess the changes in crevicular fluid, epithelial attachment loss, and bone height and density within each group at partial denture insertion, 6 and 12 months from insertion. Student t-test was used to compare between the two groups.

RESULTS

The results of this study were shown in Tables 1 to 12.

DISCUSSION

Increase in crevicular fluid measurements for both groups during this study was in agreement with the studies made by Javid and Low (1984),¹² and Spielberger et al (1984)¹³ that mentioned that effect of partial denture clasps on the flow of food over the abutment tooth surface disrupting the self-cleansing action and preventing the mucus of the lips, tongue and cheeks from massaging the gingival tissues. In addition removable partial denture may sink into the soft tissues causing gingival inflammation. The increase in the crevicular fluid measurements for the first group was significantly higher than that for the second group at the different follow-up intervals. This could be due to the fact that acetal resin clasp is a flexible clasp that may impinge the gingiva during insertion and removal of the denture specially with the habit of some patients to secure the denture finally in its place by pressing the denture down from the clasp arm.

For epithelial attachment loss in the first and second groups, there was no significant change in the attachment loss measurements at the different follow-up intervals. This finding was in agreement with the studies made by Bergman et al (1971),¹⁴ Schwalm et al (1977),⁶ Gomes et al (1980),¹⁵ Bergman et al (1982),¹⁶ Chandler and Brudvik (1984),¹⁷ Bergman (1987),⁴ and Petridis and Hempton (2001),¹⁸ who mentioned

Comparison between Acetal Resin and Cobalt-chromium Removable Partial Denture Clasps: Effect on Abutment Teeth

Table 1: The effect of clasp type on crevicular fluid measurements (mm²)

Measurement	Interval	Group I		Group II	
		Mean	SD	Mean	SD
Crevicular fluid	At denture insertion	1.319	0.723	1.206	0.603
	After 6 months	1.581	0.885	1.281	0.741
	After 12 months	1.738	0.955	1.350	0.728

Group I: Acetal resin clasp; Group II: Cobalt-chromium clasp; SD: Standard deviation

Table 2: The effect of clasp type on attachment loss measurements (mm)

Measurement	Interval	Group I		Group II	
		Mean	SD	Mean	SD
Attachment loss	At denture insertion	1.056	0.323	1.125	0.526
	After 6 months	1.056	0.323	1.125	0.526
	After 12 months	1.088	0.374	1.162	0.572

Group I: Acetal resin clasp; Group II: Cobalt-chromium clasp; SD: Standard deviation

Table 3: The effect of clasp type on bone height measurements (mm)

Measurement	Interval	Group I		Group II	
		Mean	SD	Mean	SD
Bone height	At denture insertion	15.397	1.560	14.125	1.561
	After 6 months	15.239	1.574	13.856	1.473
	After 12 months	15.005	1.586	13.540	1.449

Group I: Acetal resin clasp; Group II: Cobalt-chromium clasp; SD: Standard deviation

Table 4: The effect of clasp type on bone density measurements

Measurement	Interval	Group I		Group II	
		Mean	SD	Mean	SD
Bone density	At denture insertion	176.125	19.381	182.212	24.183
	After 6 months	173.575	19.460	178.362	24.425
	After 12 months	169.788	19.032	173.862	24.762

Group I: Acetal resin clasp; Group II: Cobalt-chromium clasp; SD: Standard deviation

Table 5: The effect of time on crevicular fluid measurements (mm²) of groups I and II

Interval	Group I			Group II		
	Mean changes	SD	p	Mean changes	SD	p
At insertion—6 months	0.262	0.218	***	0.075	0.291	NS
6 months—12 months	0.156	0.162	***	0.069	0.103	**
At insertion—12 months	0.419	0.304	***	0.144	0.279	*

SD: Standard deviation; p: Probability level for the effect of time; NS: Nonsignificant ($p > 0.05$); *Significant at $p \leq 0.05$; **Significant at $p \leq 0.01$; ***Significant at $p \leq 0.001$

Table 6: The effect of time on attachment loss measurements (mm) of groups I and II

Interval	Group I			Group II		
	Mean changes	SD	p	Mean changes	SD	p
At insertion—6 months	0.000	0.000	NS	0.000	0.000	NS
6 months—12 months	0.031	0.080	NS	0.038	0.082	NS
At insertion—12 months	0.031	0.080	NS	0.038	0.082	NS

SD: Standard deviation; p: Probability level for the effect of time; NS: Nonsignificant ($p > 0.05$)

Table 7: The effect of time on bone height measurements (mm) of groups I and II

Interval	Group I			Group II		
	Mean changes	SD	p	Mean changes	SD	p
At insertion—6 months	-0.158	0.074	***	-0.269	0.135	***
6 months—12 months	-0.234	0.097	***	-0.316	0.139	***
At insertion—12 months	-0.392	0.133	***	-0.585	0.247	***

SD: Standard deviation; p: Probability level for the effect of time; ***Significant at $p \leq 0.001$

Table 8: The effect of time on bone density measurements of groups I and II

Interval	Group I			Group II		
	Mean changes	SD	p	Mean changes	SD	p
At insertion—6 months	-2.550	0.805	***	-3.850	1.735	***
6 months—12 months	-3.788	1.445	***	-4.500	2.028	***
At insertion—12 months	-6.338	1.379	***	-8.350	3.302	***

SD: Standard deviation; p: Probability level for the effect of time; **Significant at $p \leq 0.01$; ***Significant at $p \leq 0.001$

Table 9: The effect of clasp type on changes in the crevicular fluid measurements (mm^2)

Measurement	Interval	Group I		Group II		p
		Mean changes	SD	Mean changes	SD	
Crevicular fluid	At insertion—6 months	0.262	0.218	0.075	0.291	*
	6 months—12 months	0.156	0.162	0.069	0.103	*
	At insertion—12 months	0.419	0.304	0.144	0.279	**

SD: Standard deviation, p: Probability level between groups I and II; *Significant at $p \leq 0.05$; **Significant at $p \leq 0.01$

Table 10: The effect of clasp type on changes in the attachment loss measurements (mm)

Measurement	Interval	Group I		Group II		p
		Mean changes	SD	Mean changes	SD	
Attachment loss	At insertion—6 months	0.000	0.000	0.000	0.000	NS
	6 months—12 months	0.031	0.080	0.038	0.082	NS
	At insertion—12 months	0.031	0.080	0.038	0.082	NS

SD: Standard deviation; p: Probability level between groups I and II; NS: Nonsignificant ($p > 0.05$)

Table 11: The effect of clasp type on changes in the bone height measurements (mm)

Measurement	Interval	Group I		Group II		p
		Mean changes	SD	Mean changes	SD	
Bone height	At insertion—6 months	-0.158	0.074	-0.269	0.135	**
	6 months—12 months	-0.234	0.097	-0.316	0.139	*
	At insertion—12 months	-0.392	0.133	-0.585	0.247	**

p: Probability level between groups I and II; SD: Standard deviation; *Significant at $p \leq 0.05$; **Significant at $p \leq 0.01$

Table 12: The effect of clasp type on changes in the bone density measurements

Measurement	Interval	Group I		Group II		p
		Mean changes	SD	Mean changes	SD	
Bone density	At insertion—6 months	-2.550	0.805	-3.850	1.735	**
	6 months—12 months	-3.788	1.445	-4.500	2.028	NS
	At insertion—12 months	-6.338	1.379	-8.350	3.302	*

p: Probability level between groups I and II; SD: Standard deviation; NS: Nonsignificant ($p > 0.05$); *Significant at $p \leq 0.05$; **Significant at $p \leq 0.01$

that, removable partial dentures did not cause any adverse periodontal reactions, provided that preprosthetic periodontal health had been established and maintained with meticulous oral hygiene. On the other hand, this finding was in disagreement with the study made by Tuominen et al (1989)¹⁹ who mentioned that wearing of removable partial denture significantly increased the odds of having periodontal pockets in general as well as the odds of having deeper periodontal pocket.

For bone height changes in the first and second groups, there was highly significant reduction in its measurements at the different follow-up intervals. This finding was in agreement with the studies made by Waerhaug (1968),⁷ Rissin et al (1979),²⁰ and Yusof and Isa (1994)²¹ who mentioned that the periodontal conditions of the teeth adjacent to the dentures were poorer than around those not directly involved in its construction due to food stagnation and difficult oral hygiene caused by the removable partial denture components. In addition, removable partial denture might sink into the soft tissues causing bone resorption. The reduction in the bone height measurements for the second group was significantly higher than that for the first group at the different follow-up intervals. This could be due to the fact that the rigid cobalt-chromium clasp transferred more stresses to the abutment teeth than flexible acetal resin clasp did.

For bone density changes in the first and second groups, there was very high significant reduction in its measurements at the different follow-up intervals. This was explained on the basis that increased total occlusal load on the abutments supporting the partial denture could account for this significant variation in the bone density. The reduction in the bone density measurements for the second group was significantly higher than that for the first group at the first follow-up interval. This could be due to the fact that the rigid cobalt-chromium clasp

transferred more stresses to the abutment teeth than flexible acetal resin clasp did.

CONCLUSION

Acetal resin clasps were superior to cobalt-chromium clasps as produced fewer reductions in bone height and in bone density around the abutment teeth inspite of produced increase in the crevicular fluid.

REFERENCES

1. Chu CH, Chow TW. Esthetic designs of removable partial dentures. *Gen Dent* 2003;51:322-24.
2. Sykes LM, Dullabh HD, Chandler HD, Bunn B, Essop AR. Flexibility of technopolymer clasps compared with cobalt-chromium and titanium clasps. *SADJ* 2002;57:166-71.
3. Fitton JS, Davies EH, Hewlett JA, Pearson GJ. The physical properties of a polyacetal denture resin. *Clin Mater* 1994;17:125-29.
4. Bergman B. Periodontal reactions related to removable partial dentures. *J Prosthet Dent* 1987;58:454-58.
5. Morris ML. Artificial grown contours and gingival health. *J Prosthet Dent* 1962;12:1146-56.
6. Schwalm CA, Smith DE, Erickson JD. A clinical study of patients 1 to 2 years after placement of removable partial dentures. *J Prosthet Dent* 1977;38:380-91.
7. Waerhaug J. Periodontology and partial prosthesis. *Int Dent J* 1968;18:101-06.
8. Wilding RJC, Reddy J. Periodontal disease in partial denture wearers: A biological index. *J Oral Rehabil* 1987;14:111-24.
9. Yeung AL, Lo EC, Chow TW, Clark RK. Oral health status of patients 5-6 years after placement of cobalt-chromium removable partial dentures. *J Oral Rehabil* 2000;27:183-89.
10. Martin LP, Noble WH. Gingival fluid in relation to tooth mobility and occlusal interferences. *J Periodontol* 1974;45:444-49.

11. Plotnick IJ, Beresin VE, Simkins AB. A technique for standardized serial dental radiographs. *J Periodontol* 1971; 42:297-99.
12. Javid N, Low S. The removable partial denture as a periodontal prosthesis. *Dent Clin North Am* 1984;28:337-48.
13. Spielberger MC, Lubow RM, Bange AA, Mayhew RB. Effect of retentive arm clasp design on gingival health. A feasibility study. *J Prosthet Dent* 1984;52:397-400.
14. Bergman B, Hugoson A, Olsson C. Periodontal and prosthetic conditions in patients treated with removable partial dentures and artificial crowns. A longitudinal 2-year study. *Acta Odontol Scand* 1971;29:621-38.
15. Gomes BC, Renner RP, Bauer PN. Periodontal considerations in removable partial dentures. *J Am Dent Assoc* 1980;101: 496-98.
16. Bergman B, Hugoson A, Olsson C. Caries, periodontal and prosthetic findings in patients with removable partial denture: A 10-years longitudinal study. *J Prosthet Dent* 1982;48: 506-14.
17. Chandler JA, Brudvik JS. Clinical evaluation of patients 8 to 9 years after placement of removable partial dentures. *J Prosthet Dent* 1984;51:736-43.
18. Petridis H, Hempton TJ. Periodontal considerations in removable partial denture treatment: A review of the literature. *Int J Prosthodont* 2001;14:164-72.
19. Tuominen R, Ranta K, Paunio L. Wearing of removable partial denture in relation to periodontal pockets. *J Oral Rehabil* 1989; 16:119-26.
20. Rissin L, House JE, Conway C, Loflus ER, Chauncey HH. Effect of age and removable partial dentures on gingivitis and periodontal disease. *J Prosthet Dent* 1979;42:217-23.
21. Yousof Z, Isa Z. Periodontal status of teeth in contact with denture in removable partial denture wearers. *J Oral Rehabil* 1994;21:77-86.