

# A Study to evaluate Some of the Esthetic Factors determining Attractive Smile

<sup>1</sup>Roseline D Meshramkar, <sup>2</sup>Ravi Agarwal, <sup>3</sup>Lekha K Pillai, <sup>4</sup>Ramesh K Nadiger

## ABSTRACT

**Aim:** The objective of the study is to evaluate some of the esthetic factors which will determine an attractive smile.

**Materials and methods:** This study was conducted with 214 students, between the age of 18 and 25 years, from Dharwad SDM College of Dental Sciences with natural dentition and who fulfilled the required criteria; the frontal photograph was taken of each individuals with smile displaying upper anterior teeth as well as gingiva. Each student's smile was compared, analyzed, and evaluated. Differences between smile types were determined statistically with Z-proportionality test.

**Results:** Five elements of smile were analyzed. The difference in smile type between men and women was statistically significant. Average smile was the most common with 48.13%, followed by high smile of 37.38%, and low smile was the least common with 14.49%. The downward curvature was the most common with 48.60% followed by straight curvature 42.88% and the lowest common was upward curvature with 8.88%. Straight curvature was the most common followed by parallel curvature and reverse curvature. Totally, 64.95% students showed lower lip touch of the maxillary teeth, and 22.43% showed lower lip not touching the teeth. And, 12.62% showed lower lip slightly covering teeth; 64.95% displayed till 2nd premolar; 32.24% displayed till the first molar; and 2.8% displayed till canine.

**Conclusion:** The average smile was the most common with downward curvature, straight maxillary incisal curve with the lower lip, maxillary anterior teeth not touching the lower lip, and a number of teeth displayed till the second premolar. Smile analysis must be assessed in association with the face in order to define esthetic rehabilitation of smile. It will give guidelines for restoration of esthetics in anterior.

**Keywords:** Attractive smile, Esthetics, Smile, Smile analysis, Smile design.

**How to cite this article:** Meshramkar RD, Agarwal R, Pillai LK, Nadiger RK. A Study to evaluate Some of the Esthetic Factors determining Attractive Smile. *Int J Prosthodont Restor Dent* 2016;6(2):31-36.

**Source of support:** Nil

**Conflict of interest:** None

<sup>1,4</sup>Professor, <sup>2</sup>Pediatric Dental Consultant, <sup>3</sup>Professor and Head

<sup>1-4</sup>Department of Prosthodontics, SDM College of Dental Sciences and Hospital, Dharwad, Karnataka, India

**Corresponding Author:** Roseline D Meshramkar, Professor Department of Prosthodontics, SDM College of Dental Sciences and Hospital, Dharwad, Karnataka, India, Phone: +918362468142, e-mail: roselinemeshramkar@yahoo.co.in

## INTRODUCTION

A pleasant smile is an expression of joy, while another smile may be exhilarating or embarrassed gleeful/winsome or hateful.<sup>1</sup> A smile when pleasing and attractive to observer enriches not only the one who smiles, but those who view it. Esthetics have become increasingly important in the practice of modern restorative dentistry and synonymous with a natural harmonious appearance.<sup>2</sup> A smile expresses itself mainly in the oral region and eyes.<sup>3</sup> Often the demand for esthetics motivates the patients to seek dental treatment.<sup>4,5</sup> In current health and esthetic conscious world, a smile is considered an important component of overall appearance and well-being.<sup>6</sup> An attractive smile would be the goal of esthetic dentistry. The importance of an attractive smile and its effect on the positive self-image cannot be overemphasized.<sup>7</sup> An attractive smile clearly enhances the acceptance of the individual in our society by improving the initial impression and interpersonal relationship. Tjan and Miller<sup>7</sup>, in their study, reported that an average smile exhibits the full length of maxillary anterior teeth, displays an incisal curve of the maxillary teeth, i.e., parallel to the inner curvature of the lower lip, and displays the maxillary anterior teeth and premolar. There are many factors that determine the attractive smile. This study formulates a standard of normalcy in an esthetic smile relative to smile type, the parallelism of maxillary incisal curve with the lower lip, upper lip curvature, the relationship of maxillary anterior teeth and lower lip, and the number of teeth displayed. Whenever restoring anterior teeth, esthetics plays an important role to achieve good knowledge of smile and factors affecting it. Hence, the aim of the study is to analyze and compare different smiles to estimate the esthetic quality of subjects using different scores for smiles. The objective of the study is to evaluate whether the five elements of smile used in the study determine the attractive smile. This may serve as a guideline for the restoration of esthetics for an anterior component of dentition.

## MATERIALS AND METHODS

This study was conducted after project approval by the ethical committee on research. A comparative analysis of some esthetic factors that influence attractive smiles was conducted with two full-face photographs of a dental student studying in Dharwad SDM Dental Institute. The

sample consisted of 214 dental students, of whom 140 were women and 72 were men of 18 to 25 years of age with natural dentition and who fulfilled the required criteria. The criteria for inclusion were: Students should have no missing teeth, orthodontic treatment, maxillofacial surgery, prosthodontic treatment, the unpleasant gingival color or contours, unpleasant fracture teeth, or structural deformity of teeth. Class 1 occlusion was not included because five elements of smile were considered irrespective of type of occlusion.

### OBTAINING THE PHOTOGRAPH

A frontal photograph was taken of each individual with head in upright position and at eyesight level with a smile displaying maxillary anterior teeth as well as gingiva using Nikon DSLR 200 camera with 1:1 100 mm microlens digital flash umbrella (two) simplex-pro, lighting and staging were kept constant. All the students were asked to smile naturally or asked to say cheese and one or two photo shots were taken. All photographs were saved in personal computer image measurement program. Each subject's smile was compared and analyzed and evaluated carefully by visual judgment rather than mathematical measurements by two evaluators.

Five elements of the smile were analyzed in this study: The upper lip position, upper lip curvature, parallelism of the maxillary anterior incisal curve with the lower lip, the relationship between the maxillary anterior teeth and the lower lip, and the number of teeth displayed in a smile.

1. Upper lip position was divided into three categories  
A high smile reveals the total cervico incisal length of the maxillary anterior teeth and a contiguous band of gingival; an average smile reveals 75 to 100% of the maxillary anterior teeth and the interproximal only, and a low smile displays less than 75% of the anterior teeth.
2. Upper lip curvature was divided into three categories  
Upward means that the corner of the mouth is higher than the center of the lower border of the upper lip; straight means that the corner of the mouth and the center of the lower border of the upper lip are on a straight line; and downward means that the corner of the mouth is lower than the center of the lower border of the upper lip.
3. Parallelism of the maxillary anterior incisal curve with the lower lip was divided into three categories.

Parallel means that the incisal edges of the maxillary anterior teeth are parallel to the upper border of the lower lip; straight means that the incisal edges of the maxillary anterior teeth are in a straight line; and reverse means the incisal edges of the maxillary anterior teeth curved in reverse to the upper border of the lower lip.

4. Relationship between maxillary anterior teeth and lower lip was divided into three categories: Slightly covered means that the incisal edge of the maxillary anterior teeth was slightly covered by the lower lip; touching means that the incisal edge of the maxillary anterior teeth just touched the lower lip; not touching means that the incisal edge of the maxillary anterior teeth did not touch the lower lip.
5. The teeth displayed in a smile: The mean esthetic rank of the subjects who displayed the first molar was the highest and the mean esthetic rank of the subjects who displayed the canine was the lowest.

### RESULTS

Differences were noticed between smile type, upper lip curvature, the parallelism of the maxillary anterior incisal curve with the lower lip, the relationship between the maxillary anterior teeth and the lower lip, maxillary incisal curve relating to touching the lower lip. The number of teeth displayed in a smile was determined statistically with the Z-proportionality test. Table 1 shows the upper lip position (smile type) comparison between males and females (Fig. 1). A total of 45.77% of women and 20.83% of men showed a high smile, 52.78% of men followed by 8.45% of women average smile, and 26.39% men showed a low smile. The difference in smile type between men and women was statistically significant (Graph 1). The average smile was most common followed by a high smile, and low smile was the least common. Table 2 compares upper lip curvature of men and women (Fig. 2). A total of 52.11% of women and 41.67% of men showed downward curvature, 38.73% of women and 50.00% of men showed straight curvature, followed by 9.15% women and 8.33% of men showed upward curvature (Graph 2). The straight curvature of upper lip between men and women was statistically significant when compared with downward and upward curvatures. Table 3 compares parallelism

**Table 1:** The upper lip position (smile type) comparison between men and women

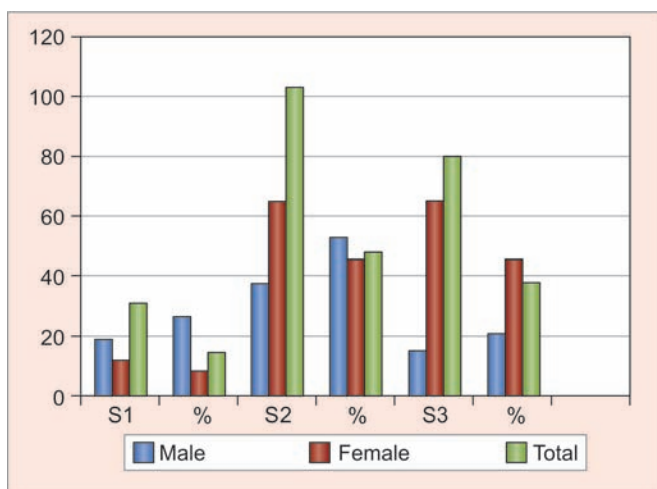
Sex	S1	Percentage	S2	Percentage	S3	Percentage	Total
Men	19	26.39	38	52.78	15	20.83	72
Women	12	8.45	65	45.77	65	45.77	142
Total	31	14.49	103	48.13	80	37.38	214
Z = 1.2263, p = 0.2201, NS			Z = -2.5741, p = 0.0101, S		Z = -4.7405, p = 0.0000, S		

Chi-square = 19.0490; df = 2; p = 0.0000; S: Significant



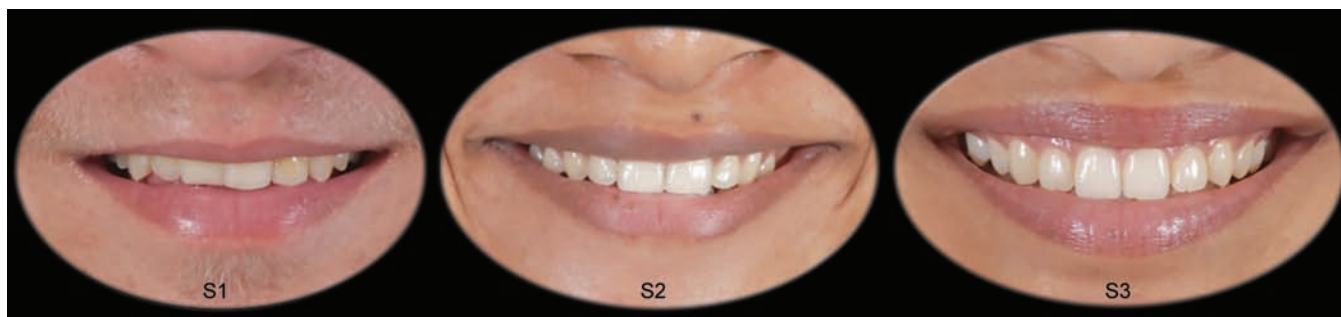

Fig. 1: (S1) Low smile; (S2) Average smile; (S3) High smile



Graph 1: Upper lip position

of the maxillary anterior incisal curve with the lower lip of men and women (Fig. 3). A total of 52.11% of women and 30.56% of men showed straight curvature, 40.14% of women and 27.78% of men showed parallel curvature, and 7.75% of women and 41.67% of men showed reverse curvature (Graph 3). Straight curvature was most common followed by parallel curvature and reverse curvature.

Table 2: Comparison of upper lip curvature of men and women

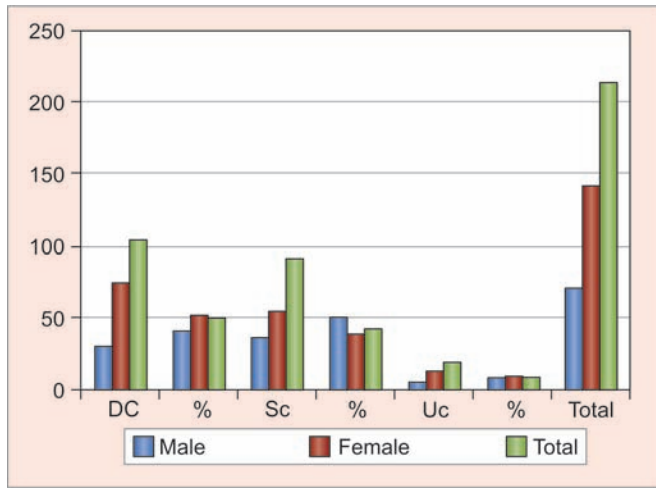
Sex	Dc	Percentage	Sc	Percentage	Uc	Percentage	Total
Men	30	41.67	36	50.00	6	8.33	72
Women	74	52.11	55	38.73	13	9.15	142
Total	104	48.60	91	42.52	19	8.88	214

Z = -3.9728, p = 0.0001, NS      Z = -1.9498, p = 0.0512, S      Z = -1.5068, p = 0.1319, NS

Chi-square = 2.5350; df = 2; p = 0.2814; NS: Nonsignificant; S: Significant

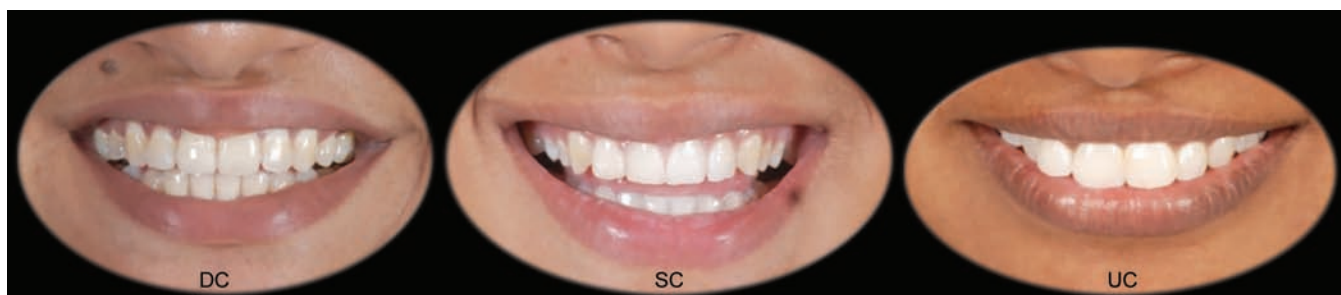

Fig. 2: (Dc) Downward curvature; (Sc) Straight curvature; (Uc) Upward curvature



Graph 2: Upper lip curvature

**DISCUSSION**

The basic knowledge of the esthetic aspects of natural dentition may contribute in a simple, yet, efficient manner toward reducing difficulties in the dentist vs patient relationship with regard to the patient’s smile, esthetic appearance, and psychosocial integration.

A large number of individuals seek dental care because of esthetic reasons that are the desire to look more attractive by improving their smiles.<sup>8</sup> An attractive smile is important for facial esthetics. Tjan and Miller<sup>7</sup> reported an average smile exhibits the full length of maxillary teeth that displays an incisal curve of the maxillary teeth that is parallel to the inner curvature of the lower lip and displays six maxillary anterior teeth and the premolars.

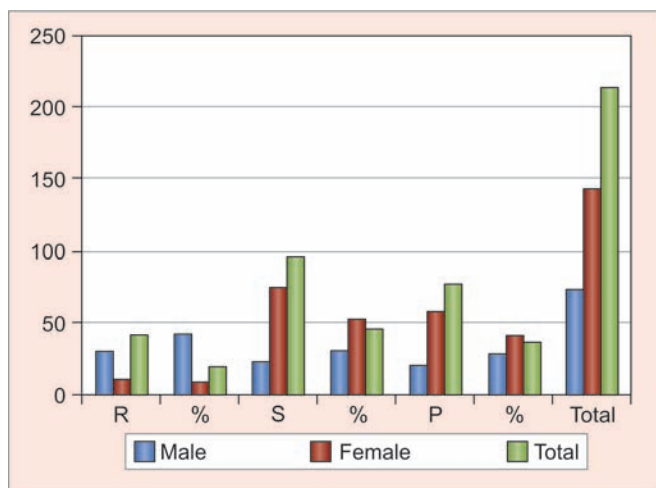
**Table 3:** Comparison of parallelism of the maxillary anterior incisal curve with the lower lip of men and women

Sex	R	Percentage	S	Percentage	p	Percentage	Total
Men	30	41.67	22	30.56	20	27.78	72
Women	11	7.75	74	52.11	57	40.14	142
Total	41	19.16	96	44.86	77	35.98	214
	Z = 2.6922, p = 0.0071, S		Z = -4.6739, p = 0.0000, S		Z = -3.8012, p = 0.0001, S		

Chi-square = 35.6701; df = 2; p = 0.0000; S: Significant

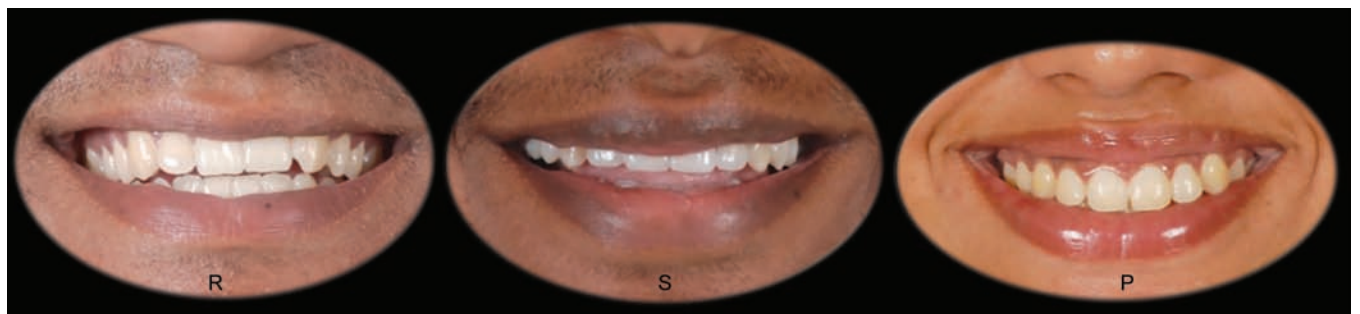

Fig. 3: (R) Reverse curve; (S) Straight; (P) Parallel



Graph 3: Parallelism of maxillary anterior incisal curve with lower lip

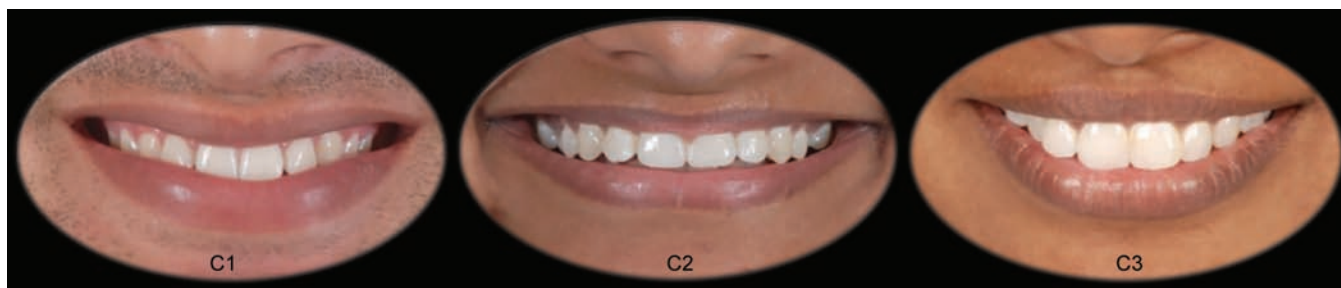Teeth exposed in smiling are the vital parts of the anatomy of a smile.<sup>9</sup> Yoon et al<sup>10</sup> found that in an attractive smile, a full shape of the maxillary teeth was displayed between upper and lower lip. The findings in our study were similar to those of Tjan and Miller<sup>7</sup> and Yoon et al.<sup>10</sup>

In a facial view at rest, the lips may meet in a straight line or curve toward the corner either upward or downward.<sup>9</sup> Smile symmetry refers to the relative symmetric placement of the corners of the mouth in the vertical plane. Generally, it is accepted that in harmonious dental composition, the lower lip accompanies the curvature of the maxillary teeth.<sup>8</sup> Tjan et al<sup>9</sup> determined that the mean of smiles had incisal curvature of the lower lip. Reverse incisal curve has a profound effect on the degree of attraction of a smile. Frush and Fisher<sup>11</sup> have directed toward

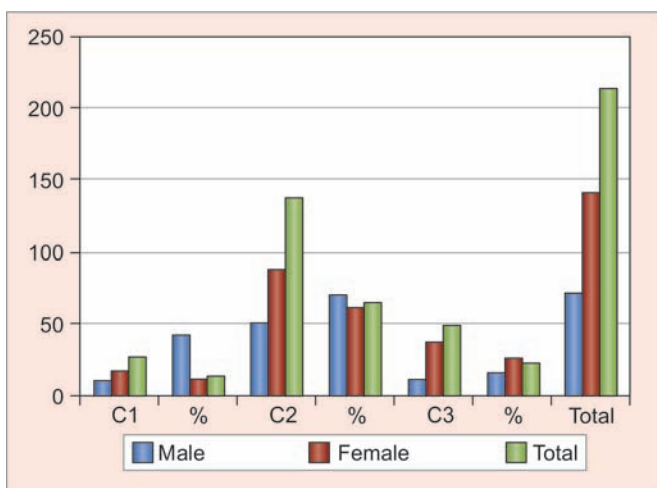
**Table 4:** Comparison of relationship between maxillary anterior teeth and lower lip between men and women

Sex	C1	Percentage	C2	Percentage	C3	Percentage	Total
Men	10	13.89	51	70.83	11	15.28	72
Women	17	11.97	88	61.97	37	26.06	142
Total	27	12.62	139	64.95	48	22.43	214

Z = -1.3037, p = 0.1923, NS      Z = -3.0328, p = 0.0024, S      Z = -3.2993, p = 0.0010, S  
 Chi-square = 3.1910; df = 2; p = 0.2027; NS: Nonsignificant; S: Significant



**Fig. 4:** (C1) Lower lip covering anterior teeth; (C2) Not touching; (C3) Touching



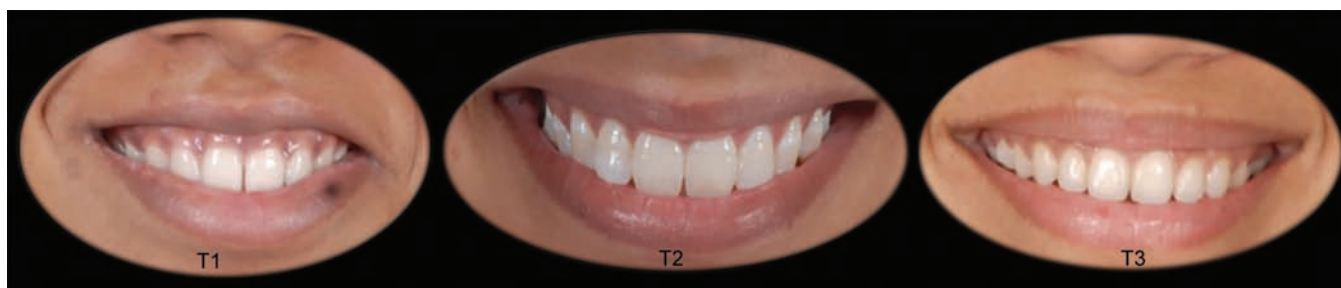**Graph 4:** Relationship between maxillary anterior teeth and lower lip

the harmony between the curvature of the incisal adages of the maxillary and anterior teeth and the upper border of the lower lip. Husley<sup>12</sup> found that the smile line ratio of the congruency of the arc of curvature of the upper border of the lower lip and the arc of curvature of the incisal edges of the maxillary anterior teeth appeared to be important in an attractive smile. The findings are similar to those of our study, where individuals had straight upper lip curvature. The relation of contact between the lower lip and the incisal edges of maxillary teeth is also important in esthetic assessment. According to Tjan, incisal edge of maxillary anterior teeth touching the lower lip and not touching the lower lip is more esthetic than the maxillary anterior teeth slightly covered by the lower lip. In our study, 64.95% of individuals' maxillary anterior teeth did not touch the lower lip.

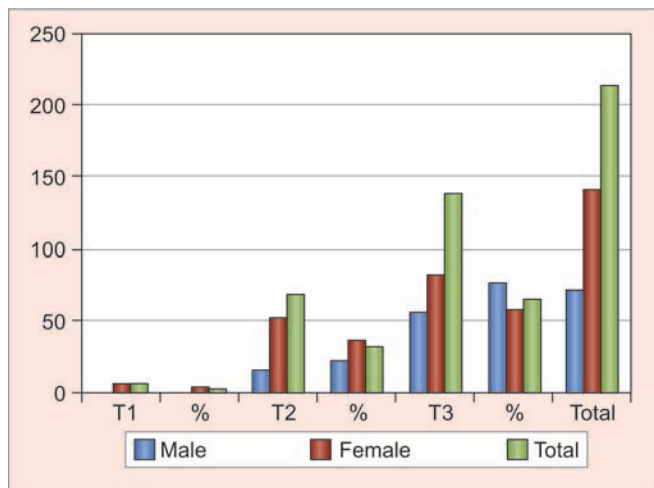
**Table 5:** Comparison of teeth displayed in a smile between men and women

Sex	T1	Percentage	T2	Percentage	T3	Percentage	Total
Men	0	0.00	16	22.22	56	77.78	72
Women	6	4.23	53	37.32	83	58.45	142
Total	6	2.80	69	32.24	139	64.95	214

-      Z = -3.9253, p = 0.0001, S      Z = -2.2476, p = 0.0246, S  
 Chi-square = 9.1690; df = 2; p = 0.0102; S: Significant



**Fig. 5:** (T1) Teeth displayed till canine; (T2) Teeth displayed till premolar; (T3) Teeth displayed till first molar



Graph 5: Teeth displayed in a smile

A number of teeth displayed in a smile are important for planning esthetic restoration. For instance, in 1999, Dong JK stated that the smile with first molar display had highest esthetic rank; and Yoon et al<sup>10</sup> showed that the ideal smile displays the first molar; dentists must be sure to extend their concerns to posterior teeth to maximize smile attractiveness. However, in this study, most of the subjects displayed till the second premolar, which is similar to Tjan and Miller's findings that average smile exhibits six maxillary anterior teeth and the premolar. To create a harmonious smile, the dentist must maintain or create the normal curvature of the lips for proper exposure of red zone of the lips and teeth.<sup>7</sup> In order to provide good esthetics, patients' smiles must be understood, recorded, and analyzed. The desirable aspects may be preserved and graceless components returned to attractiveness.

## CONCLUSION

Within the limitations of the study, it was concluded that when five elements of smile were analyzed, the average

smile was most common, followed by downward curvature, straight maxillary incisal curve with the lower lip, maxillary anterior teeth not touching the lower lip, and number of teeth displayed till second premolar. An attractive smile is influenced by the five factors that were analyzed in the study. Understanding the esthetic criteria of the smile is fundamental for the present-day dentists, considering the growing demand for esthetic treatment. Therefore, the smile analysis must be assessed in association with the face in order to define esthetic rehabilitation of the smile.

## REFERENCES

1. Shapiro HH. Applied anatomy of Head and neck. Philadelphia: JB Lippincott Company; 1943. p. 6, 7.
2. Pilkington EL. Esthetics optical illusion in dentistry. J Am Dent Assoc 1936 Apr;23(4):641-651.
3. Goldstein RE. Study of need for esthetics in dentistry. J Prosthet Dent 1969 Jun;21(6):589-598.
4. Miller IF, Belsky MW. Cosmetics in restorative dentistry. Dent Clin North Am 1967 Mar;10:11-18.
5. Culpepper WD, Mitchell PS, Blass MS. Esthetic factors in ant tooth restoration. J Prosthet Dent 1976;30:576.
6. Culpepper WD, Mitchell PS, Blass MS. Aesthetic factor in ant tooth restoration. J Prosthet Dent 1973;30:576-582.
7. Tjan AHL, Miller GD. Some esthetic factor in smile. J Prosthet Dent 1984 Jan;54(1):24-28.
8. Renner, RP. Dental esthetics. In: Renner, RP., editor. An introduction to dental anatomy and esthetics. Chicago; Quintessence: 1985. p. 241-276.
9. Matthews TG. The anatomy of smile. J Prosthet Dent 1978 Feb;39(2):2-128-134.
10. Yoon ME, Jin TH, Dong JK. A study on the smile in Korean youth. J Korean Acad Prosthodont 1992;30(2):259-270.
11. Frush JP, Fisher RD. The dynasthetic interpretation of the dentogenic concept. J Prosthet Dent 1958 Jul;8(4):558-581.
12. Hulsey CM. An esthetic evaluation of lip-teeth relationships present in the smile. Am J Orthod 1970 Feb;57(2):132-144.