



## Single vs Two-session Root Canal Treatment: A Preliminary Randomized Clinical Study using Cone Beam Computed Tomography

<sup>1</sup>Claudia de Castro Rizzi-Maia, <sup>2</sup>Etevaldo M Maia-Filho, <sup>3</sup>Paulo Nelson-Filho, <sup>4</sup>Raquel AB Segato  
<sup>5</sup>Alexandra M de Queiroz, <sup>6</sup>Francisco WG Paula-Silva, <sup>7</sup>Sângela M da Silva Pereira, <sup>8</sup>Alvaro H Borges  
<sup>9</sup>Léa AB da Silva

### ABSTRACT

**Aims:** To compare root canal treatment of teeth with apical periodontitis (AP) in a single or two visits, using cone beam computed tomography (CBCT).

**Materials and methods:** Twenty-six pairs of teeth (13 patients) were assigned to two groups: Group single-session (GSS): Instrumentation and root canal filling in the same session; and group two-session (GTS): A calcium hydroxide intracanal medication (Calen<sup>®</sup> paste) was used for 14 days between two sessions. Cone beam computed tomography scans were obtained before and 12 months after treatment. The pre- and postoperative volume of the AP lesions was measured in mm<sup>3</sup>. The percentages of volume reduction was compared using Student's t-test and the existence of significant difference between the groups for cases with  $\leq 50\%$  or  $> 50\%$  lesion volume reduction was assessed by chi-squared test ratio likelihood test ( $\alpha = 5\%$ ).

**Results:** The volume reduction was greater in GTS (79.25%) than GSS (68.35%), though without significant difference ( $p > 0.05$ ). After 12 months, complete repair was not observed in any specimen. Lesion volume reduction  $> 50\%$  was significantly greater with the use of an intracanal medication ( $p < 0.05$ ).

**Conclusion:** Twelve months posttreatment, CBCT did not show complete repair in any of the teeth, suggesting that this follow-up period is not sufficient for complete lesion regression. In both groups, similar AP lesion volume reduction was observed

after 12 months, with a more advanced repair ( $> 50\%$  volume reduction) in the teeth medicated with calcium hydroxide intracanal dressing.

**Clinical significance:** Calcium hydroxide intracanal dressing provided clinical evidence to indicate its use in teeth with apical periodontitis prior to definitive root canal filling.

**Keywords:** Apical periodontitis, Calcium hydroxide, Cone beam computed tomography, Root canal treatment, Single session.

**How to cite this article:** de Castro Rizzi-Maia C, Maia-Filho EM, Nelson-Filho P, Segato RAB, de Queiroz AM, Paula-Silva FWG, da Silva Pereira SM, Borges AH, da Silva LAB. Single vs Two-session Root Canal Treatment: A Preliminary Randomized Clinical Study using Cone Beam Computed Tomography. J Contemp Dent Pract 2016;17(7):515-521.

**Source of support:** Nil

**Conflict of interest:** None

### INTRODUCTION

Periapical radiography (PAR) remains the most popular imaging method for endodontic diagnosis and treatment, but limitations arise from the fact that PAR image corresponds to a two-dimensional (2D) aspect of a three-dimensional (3D) structure and superimposition of structures occurs in multiple planes. Small pathologic apical bone losses are usually not detected on PAR<sup>1</sup> and the size of the radiolucencies may underrepresent the true dimensions of the lesions.<sup>2-4</sup> Several studies have referred to cone beam computed tomography (CBCT) as a more accurate imaging resource than PAR for the early detection of apical periodontitis (AP) lesions, even for those still confined within the cancellous bone.<sup>5-12</sup> It has been reported that CBCT has approximately 40% greater capacity to reveal the number of roots associated with chronic AP lesions than PAR, indicating that the

<sup>1,3-6,9</sup>Department of Dentistry, School of Dentistry of Ribeirão Preto, University of São Paulo, Ribeirão Preto, São Paulo, Brazil

<sup>2,7</sup>Department of Dentistry, CEUMA University, São Luis Maranhão, Brazil

<sup>8</sup>Department of Integrated Dental Science, Faculty of Dentistry University of Cuiabá, Cuiabá, Mato Grosso, Brazil

**Corresponding Author:** Etevaldo M Maia-Filho, Professor Department of Dentistry, CEUMA University, São Luis, Maranhão Brazil, Phone: +55(98)981803085, e-mail: emmaiafilho@yahoo.com.br

tomographic imaging technique is consistently more sensitive for the detection of AP lesions.<sup>6,7,13,14</sup>

Experimentally, the root canal treatment of teeth with chronic AP lesion has been performed in two or more sessions in order to control root canal system infection,<sup>15,16</sup> using a calcium hydroxide (CH)-based intracanal medication between visits.<sup>17-19</sup> While clinical studies in humans have demonstrated the efficacy of using a CH interappointment intracanal dressing,<sup>19,20</sup> others have not find a higher success rate in medicating teeth with AP with CH in a multiple-visit root canal treatment protocol compared with single-visit treatment.<sup>21,22</sup> Systematic reviews with meta-analysis were also inconclusive.<sup>23-26</sup> However, the postendodontic treatment success of these treatment modalities has been evaluated based on PAR. Due to the reportedly low sensitivity of PAR,<sup>6</sup> it is possible that the use of high-resolution imaging techniques, such as, CBCT, could provide more accurate results.

Adherence to the “as low as reasonably achievable” (ALARA) concept is strongly recommended when selecting the appropriate imaging technique for each situation, which means that every radiation exposure should be justified clinically, and principles should be followed to minimize patient exposure to ionizing radiation while maximizing the diagnostic benefit.<sup>27</sup> Although CBCT scanning of AP lesions is not indicated as a routine preoperative procedure in endodontic clinic, this imaging resource has been used in endodontic research as a diagnostic tool to provide a more reliable observation of the AP status in order to substantiate the choice for the most adequate root canal treatment strategies.<sup>12</sup> According to European Society of Endodontology (2014),<sup>28</sup> CBCT with a limited field of view (FOV) may be considered for the diagnosis of nonspecific signs and/or symptoms of AP pathosis, assessment and/or management of complex dentoalveolar trauma, appreciation of extremely complex root canal systems prior to endodontic management or nonsurgical endodontic retreatment, treatment planning purposes and assessment, and/or management of root resorption.

The aim of this study was to conduct a comparative evaluation after root canal treatment of permanent teeth with chronic AP lesion completed in a single session or in two sessions with 14-day CH interappointment intracanal medication, using CBCT imaging.

## MATERIALS AND METHODS

This randomized clinical study had the duration of 1 year and was carried out after approval from the Ethics committee of CEUMA University, São Luis, Maranhão, Brazil (29.058/2013). Research was conducted in full accordance with ethical principles, including the

Declaration of Helsinki. Patients ( $\geq 18$  and  $< 60$  years old) treated at the Endodontics Clinic of CEUMA University were invited to participate if they had two permanent mature single-rooted teeth (maxillary and mandibular incisors and canines, maxillary second premolars, or mandibular premolars) with confirmed diagnosis of pulp necrosis due to caries lesion and radiographically visible AP lesion detected on radiographic examination; no previous root canal treatment; and sufficient coronal structure for rubber dam isolation and placement of a direct restoration. Patients who used antibiotics or antimicrobial agents within 6 months prior to the study, smokers, pregnant women, diabetics, immunosuppressed patients, and those who underwent radiation therapy, or had severe periodontal disease, or periodontal pocket in the tooth to be treated were excluded from the study. Sample size calculation was performed based on the results of a previous study from our group<sup>29</sup> with 80% power and revealed a number of 13 teeth per group. We conducted this study with 14 patients aged 18 to 58 years old, who fulfilled the inclusion/exclusion criteria were enrolled in the study, and 28 teeth were examined clinically and radiographically.

## Operative Procedures

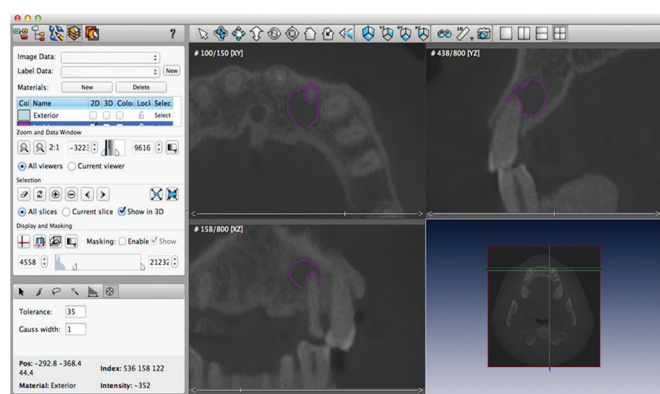
The same operator with 10 years of clinical experience carried out all endodontic procedures. After coronal opening, immediate and progressive neutralization of the septic/toxic root canal content was performed pressureless in a coronal direction with a K-file (Dentsply Maillefer, Ballaigues, Switzerland) alternating irrigation with 5.25% NaOCl and aspiration. After apical debridement, the root canal length measurement was determined 1 mm short of the apex using Root ZX II (J. Morita, Kyoto, Japan) and the canals were instrumented using ProTaper Universal® System (Dentsply Maillefer, Ballaigues, Switzerland) (SX, S1, and S2 shaping files and F1, F2, F3, F4, and F5 finishing files). In large canals, instrumentation was complemented with size 60, 70, and 80 hand K-files (Dentsply Maillefer), according to canal diameter. At each change of file during instrumentation, the canals were irrigated with 5.25% NaOCl. At the end of instrumentation, the canals were filled with 17% ethylenediaminetetraacetic acid for 3 minutes under manual agitation using a K-file to remove the smear layer, flushed with 5.25% NaOCl, and dried with absorbent paper points.

The teeth were randomly assigned to two groups ( $n = 14/\text{group}$ ) by simple random sampling (draw), in such a way that each patient received both root canal treatment modalities: Group single-session (GSS) and group two-session (GTS). In GSS, the canals were filled by lateral condensation of gutta-percha and an

epoxy resin-based sealer (AH-Plus, Dentsply Maillefer, Ballaigues, Switzerland), a glass ionomer cement base was prepared onto the canal entrance, and the coronal access was restored with composite resin. In GTS, the canals were filled with a commercial CH-based paste (Calen<sup>®</sup>, SS White Artigos Dentários Ltda., Rio de Janeiro, RJ, Brazil), a cotton pellet was placed in the pulp chamber, and the coronal access received a temporary glass ionomer cement restoration. The intracanal medication was removed by means of irrigation with sodium hypochlorite and manual K-file after 14 days and the definitive root canal filling and restoration were performed as described for GSS.

### Cone beam Computed Tomography Imaging

In both groups, CBCT scans were obtained at two moments: (1) Before endodontic treatment and (2) 12 months after treatment. The teeth were scanned pre- and post-operatively using the i-CAT Next Generation device (Imaging Sciences International, Hatfield, PA, USA) set with the following parameters: 8 cm diameter × 8 cm high scan dimensions, 0.2 mm voxel size, and 8.9 seconds scan time. Cone beam computed tomography imaging was made with 0.2 mm slice thickness in three planes (axial, coronal, and sagittal). After three-dimensional reconstruction with iCATVision 1.9.3 software, the images (DICOM format) were exported to Amira software (v.5.3.3, Visage Imaging Inc., Carlsbad, Canada) and the AP lesion volume was calculated in mm<sup>3</sup> using the segmentation procedure. Using the blow tool (Gaussian 1, tolerance 35), the lesion was outlined in the axial, coronal, and sagittal planes (Fig. 1) for each slice and then the volume was automatically calculated using the Measure/Material Statistics tool. The volume of each lesion was measured twice with a 2-week interval between the 1st and 2nd measurements and a mean value was obtained. An experienced, blind, calibrated (intraclass correlation (ICC) = 0.982) radiologist evaluated the pre- and postoperative volumes of the PA lesions.



**Fig. 1:** Representative tomographic image of a AP lesion outlined in the axial, coronal, and sagittal planes to calculate lesion volume in mm<sup>3</sup>

The groups, GSS and GTS, were compared to evaluate the volumetric images of AP (primary outcome), considering two criteria: (1) Variation in PA lesion volume after root canal treatment. The percentage of tomographic AP lesion volume reduction (%LVR) was obtained from the difference between the preoperative and postoperative volumes; (2) %LVR results were dichotomized in two intervals: 0 to ≤50 and >50%.

As secondary outcomes, intraoral clinical examination was performed for the presence of defective restorations, fistulas, or pain on mastication, 12 months after root canal treatment.

### Statistical Analysis

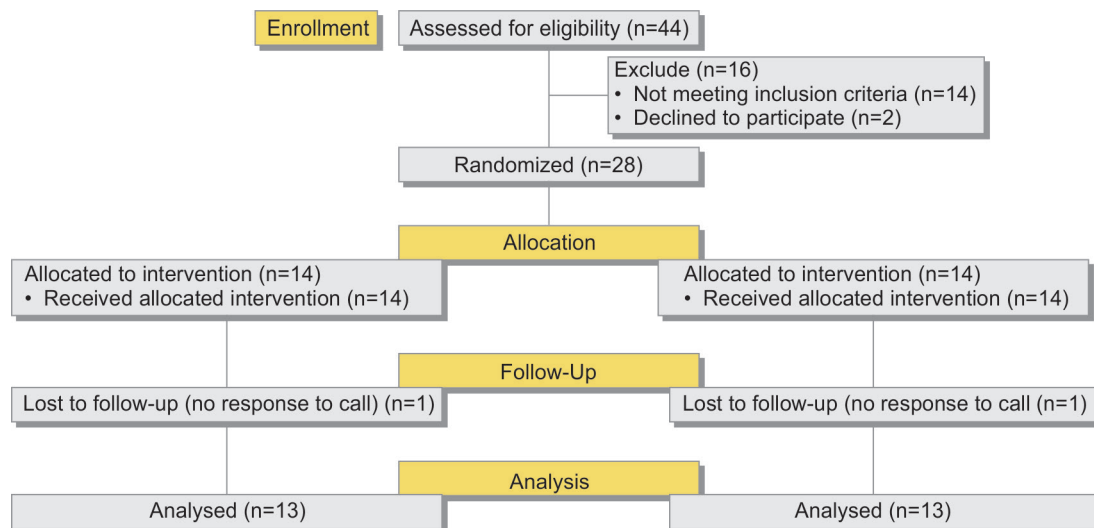
The difference of the mean preoperative tomographic lesion volumes between the groups was evaluated by the Mann-Whitney test. The %LVR data of the groups were compared by the Student's t-test for paired samples. The existence of statistically significant difference in the frequency of cases with >50% LVR between the groups was also assessed using the chi-squared test ratio likelihood test. The influence of treatment modality on %LVR (quantification of influence) was determined with the Cramer's V test. All tests were performed using the Statistical Package for the Social Sciences 21.0 (IBM, Armonk, NY, USA) statistical software and the significance level was set at 5%.

### RESULTS

One patient was lost to follow-up, resulting in the loss of two teeth (7.1% loss, approximately) and reducing the sample size in the postoperative evaluation to 26 teeth (n = 13/group). The flow chart of the study design is shown in Flow Chart 1. Among the 13 patients, 4 were men and 9 were women, with mean age of 36.92 (±12.35) years. The GSS comprised 12 maxillary teeth and 1 mandibular tooth, while the GTS had 10 maxillary and 3 mandibular teeth (Table 1). No restoration failure (fractures, gaps, infiltrations, or secondary caries), fistula, or pain on mastication was observed in the 12-month postoperative intraoral clinical examination.

The mean preoperative tomographic volumes of the AP lesions were respectively, 73.47 mm<sup>3</sup> (11.19–182.48 mm<sup>3</sup>) in GSS and 65.94 mm<sup>3</sup> (8.27–238.01 mm<sup>3</sup>), with no statistically significant difference (p > 0.05). The mean postoperative (12 months) tomographic volumes of the AP lesions were respectively, 27.73 mm<sup>3</sup> (1.07–101.16 mm<sup>3</sup>) in GSS and 12.84 mm<sup>3</sup> (0.11–29.53 mm<sup>3</sup>) in GTS. The mean %LVR after 12 months was 68.35 and 79.25% in GSS and GTS respectively, with no significant difference (p > 0.05), although the mean %LVR in GTS was 10.9% greater than in GSS and data distribution in GTS was closer to the mean

**Flow Chart 1: The study design**



**Table 1: Sample size distribution according to the type and number of teeth assigned to the groups GSS (single-session) and GTS (two-session)**

Dental arch	Dental type	Groups		Total
		GSS	GTS	
Upper jaw	Central incisor	6	4	10
	Lateral incisor	5	5	10
	Canine	1	0	1
	Second premolar	0	1	1
Lower jaw	Central incisor	0	1	1
	First premolar	1	0	1
	Second premolar	0	2	2
Total		13	13	26

(standard deviation = ± 13.04) than in GSS (standard deviation = ± 23.91). The tomographic results showed absence of complete AP repair posttreatment in both groups.

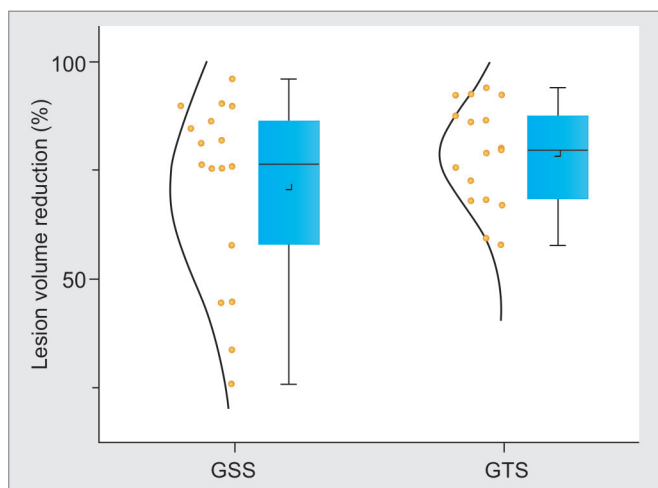
Flow Chart 1 presents the distribution of the teeth in the groups according to the preoperative tomographic

lesion volumes and %LVR after root canal treatment. Considering that the preoperative lesion volume varied from 8.27 to 238.01 mm<sup>3</sup>, the volumes were grouped in 50 mm<sup>3</sup> intervals from 0 to 250 mm<sup>3</sup>. The %LVR results were grouped in 20% intervals, from 0 to 100%. The analysis of data shows that 60 to 100% volume reduction occurred in 84.6% of the teeth filled in two sessions and in 61.6% of the teeth filled in a single session (Table 2).

The results of AP-LVR dichotomized in two intervals (≤50 and >50%) showed >50% LVR in all of GTS and only teeth of GSS presented lesions with ≤50% LVR (n=4 teeth) (Graph 1). Therefore, dichotomization of %LVR data in two intervals showed a statistically significant difference between the groups (p=0.012). The chi-squared likelihood ratio test revealed an association between the treatment modality (single session or two sessions) and the mean %LVR. Cramer’s V was 0.426, which indicates a strong association and means that approximately 18% (obtained from 0.426 squared) of AP-LVR could be explained by the choice for one of the two treatment modalities.

**DISCUSSION**

In this randomized clinical study, CBCT was used during follow-up of root canal treatment in human teeth with pulp necrosis and apical periodontitis in a single session or using a CH intracanal dressing between sessions. No previous study has used CBCT imaging to compare the repair after single- or multivisit root canal treatment. Because CBCT provides a higher diagnostic accuracy and more reliable volume measurements of AP lesions,<sup>6,10-13</sup> we investigated the effects of single- vs two-session root canal therapy on the outcome by means of CBCT as the most accurate tool for this purpose. Other studies performed similar evaluations, but using PAR as the evaluation method.<sup>20-22,30</sup>



**Graph 1: Boxplot of the percentage of tomographic AP-LVR 12 months after single-session root canal treatment (GSS) or two sessions with a calcium hydroxide intracanal dressing (GTS)**

## Single vs Two-session Root Canal Treatment: A Preliminary Randomized Clinical Study using CBCT

**Table 2:** Distribution of the teeth in the groups, GSS (single-session) and GTS (two-session), according to the percentages of AP lesion volume reduction (%LVR) recorded after root canal treatment considering the preoperative tomographic lesion volumes

Root canal treatment	Preoperative lesion volume (mm <sup>3</sup> )*	Preoperative lesion volume (mm <sup>3</sup> )				Total
		20–40% LVR	41–60% LVR	61–80% LVR	81–100% LVR	
Single-session	≤50	1 (16.7)	–	2 (33.3)	3 (50.0)	6 (100.0)
	>50/≤100	1 (25.0)	1 (25.0)	–	2 (50.0)	4 (100.0)
	>100/≤150	–	–	–	1 (100.0)	4 (100.0)
	>150/≤200	–	2 (100.0)	–	–	2 (100.0)
	Total	2 (15.4)	3 (23.0)	2 (15.4)	6 (46.2)	13 (100.0)
Two-sessions	≤50	–	1 (16.7)	–	5 (83.3)	6 (100.0)
	>50/≤100	–	1 (20.0)	4 (80.0)	–	5 (100.0)
	>100/≤150	–	–	–	–	–
	>150/≤200	–	–	–	1 (100.0)	1 (100.0)
	>200/≤250	–	–	–	1 (100.0)	1 (100.0)
Total	–	2 (15.4)	4 (30.8)	7 (53.8)	13 (100.0)	

\*The preoperative tomographic lesion volumes were grouped in 50 mm<sup>3</sup>

Only teeth with radiographically visible chronic AP lesions were selected for this study but the preoperative volume of the lesions was not used as an inclusion criterion in order to avoid hindering baseline standardization, which is a problem, i.e., is inherent to randomized clinical studies with a small number of samples. However, despite the difference of the initial mean tomographic volumes among the groups, the absence of statistically significant difference demonstrates that the baseline was adjusted.

The present study considered %LVR 1 year after completion of the root canal treatment, although it has been suggested that evaluation of treatment success should be made after 4 or 5 years.<sup>30</sup> Notwithstanding, possible dropouts and the difficulty of following patients for long periods have led most professionals to establish a 1-year follow-up period.<sup>22,31,32</sup> In this study, 73.8% LVR was observed after 12 months for both groups (single session and two sessions with intracanal medicament), but no case presented complete PA lesion repair, which suggests that this follow-up period could be insufficient. Previously, it has been reported that after 5 years, the success outcome of endodontic treatment in teeth with vital pulps varied with each radiographic method, from 94.3% for PAR to 81.3% for CBCT.<sup>33</sup>

It is well known that AP lesion volume measurements by CBCT imaging rely on the criteria employed for definition of areas with similar radiolucency values. Therefore, the CBCT scans of the AP lesions were analyzed using Amira software, which has a high measuring reproducibility.<sup>9</sup> In addition, similar methodology has been described in previous studies.<sup>18,32,34</sup>

Although no case of complete AP repair was observed within 1 year of follow-up, all cases presented reduction in lesion size. Differently from these results, Metska et al<sup>32</sup> found lesion size reduction in 57% of the cases, but these authors evaluated only teeth subjected to root canal retreatment performed by different postgraduate dental

students and not by a single, experienced endodontist as in the present study.

In a recent study in human patients<sup>34</sup> that compared the changes in AP lesion size, 10 to 37 months after root canal treatment using CBCT imaging, 77.5% of the cases presented lesion reduction or absence in the follow-up period. However, it should be mentioned that retreatment cases were included and the authors considered “lesion reduction” only in the cases that achieved over 20% reduction.

Although in the present study no statistically significant difference was observed between GTS and GSS with respect to the mean %LVR, a 10.9% greater reduction occurred in the teeth medicated with CH and filled in a second session (group GTS). Evaluation of the numerical values suggests that more patients benefited from higher percentages of AP lesion repair when an interappointment intracanal dressing was used. It should also be emphasized that the reduction values were more uniform (lower standard deviation) in GTS, showing a more predictable %LVR. This was corroborated by the fact that 84.6% of GTS cases had >60% LVR, while only 61.6% of GSS cases reached the same reduction rate. However, when the values were dichotomized in 50% intervals, a significant difference ( $p=0.012$ ) was observed between the groups, indicating that there is greater chances of reaching >50% LVR when teeth with chronic apical periodontitis receive a CH intracanal dressing for 14 days before definitive root canal filling.

During the root canal treatment of teeth with pulp necrosis and apical periodontitis, successful outcome determination might be detrimental depending on the method used for evaluation. From the discussion above, clinical verification of treatment efficacy should be performed by tomographic evaluation or histopathology in animal research studies. After this preliminary evaluation, successful treatment techniques should be the ones to be chosen for clinical practice. Histopathological studies have shown that a successful root canal treatment performed

with CH interappointment intracanal dressing achieves better outcomes than a single-session treatment.<sup>8,15</sup> In a study with animals,<sup>8</sup> evaluation of post root canal treatment AP repair by CBCT imaging provided results similar to those obtained by histopathological analysis (gold standard), while the radiographic analysis underestimated the detection of AP. The lack of clinical studies in patients comparing the AP response after single-session root canal treatment or the use of intracanal dressing between sessions, by tomographic evaluation, hinders comparisons of the results of the present study.

## CONCLUSION

Cone beam computed tomography imaging made 12 months posttreatment did not show complete repair in any of the teeth, suggesting that this follow-up period is not sufficient for the occurrence of complete lesion regression. In both groups, similar AP-LVR was observed after 12 months, with a more advanced AP lesion reduction (>50%) in the teeth medicated with CH intracanal dressing for 14 days.

## ACKNOWLEDGMENT

Authors would like to thank FAPEMA (Fundação de Amparo à Pesquisa do Maranhão) for financial support (process APP-UNIVERSAL # 00865/13).

## REFERENCES

1. Lee JS, Messer HH. Radiographic appearance of artificially prepared periapical lesions confined to cancellous bone. *Int Endod J* 1986 Mar;19(2):64-72.
2. Lofthag-Hansen S, Huuononen S, Grondahl K, Grondahl HG. Limited cone-beam CT and intraoral radiography for the diagnosis of periapical pathology. *Oral Surg Oral Med Oral Pathol Oral Radiol Endod* 2007 Jan;103(1):114-119.
3. Estrela C, Bueno MR, Leles CR, Azevedo B, Azevedo JR. Accuracy of cone beam computed tomography and panoramic and periapical radiography for detection of apical periodontitis. *J Endod* 2008 Mar;34(3):273-279.
4. Bornstein MM, Bingisser AC, Reichart PA, Sendi P, Bosshardt DD, von Arx T. Comparison between radiographic (2-dimensional and 3-dimensional) and histologic findings of periapical lesions treated with apical surgery. *J Endod* 2015 Jun;41(6):804-811.
5. Huuononen S, Kvist T, Grondahl K, Molander A. Diagnostic value of computed tomography in re-treatment of root fillings in maxillary molars. *Int Endod J* 2006 Oct;39(10):827-833.
6. Stavropoulos A, Wenzel A. Accuracy of cone beam dental CT, intraoral digital and conventional film radiography for the detection of periapical lesions. An ex vivo study in pig jaws. *Clin Oral Investig* 2007 Mar;11(1):101-106.
7. Aggarwal V, Logani A, Shah N. The evaluation of computed tomography scans and ultrasounds in the differential diagnosis of periapical lesions. *J Endod* 2008 Nov;34(11):1312-1315.
8. de Paula-Silva FW, Wu MK, Leonardo MR, da Silva LA, Wesselink PR. Accuracy of periapical radiography and cone-beam computed tomography scans in diagnosing apical periodontitis using histopathological findings as a gold standard. *J Endod* 2009 Jul;35(7):1009-1012.
9. Liang YH, Jiang L, Gao XJ, Shemesh H, Wesselink PR, Wu MK. Detection and measurement of artificial periapical lesions by cone-beam computed tomography. *Int Endod J* 2014 Apr;47(4):332-338.
10. Patel S, Wilson R, Dawood A, Foschi F, Mannocci F. The detection of periapical pathosis using digital periapical radiography and cone beam computed tomography – part 2: a 1-year post-treatment follow-up. *Int Endod J* 2012 Aug;45(8):711-723.
11. Tsai P, Torabinejad M, Rice D, Azevedo B. Accuracy of cone-beam computed tomography and periapical radiography in detecting small periapical lesions. *J Endod* 2012 Jul;38(7):965-970.
12. Ee J, Fayad MI, Johnson BR. Comparison of endodontic diagnosis and treatment planning decisions using cone-beam volumetric tomography versus periapical radiography. *J Endod* 2014 Jul;40(7):910-916.
13. Ahlowalia MS, Patel S, Anwar HM, Cama G, Austin RS, Wilson R, Mannocci F. Accuracy of CBCT for volumetric measurement of simulated periapical lesions. *Int Endod J* 2013 Jun;46(6):538-546.
14. Liang YH, Jiang LM, Jiang L, Chen XB, Liu YY, Tian FC, Bao XD, Gao XJ, Versluis M, Wu MK, et al. Radiographic healing after a root canal treatment performed in single-rooted teeth with and without ultrasonic activation of the irrigant: a randomized controlled trial. *J Endod* 2013 Oct;39(10):1218-1225.
15. Leonardo MR, Hernandez ME, Silva LA, Tanomaru-Filho M. Effect of a calcium hydroxide-based root canal dressing on periapical repair in dogs: a histological study. *Oral Surg Oral Med Oral Pathol Oral Radiol Endod* 2006 Nov;102(5):680-685.
16. Sathorn C, Parashos P, Messer H. Australian endodontists' perceptions of single and multiple visit root canal treatment. *Int Endod J* 2009 Sep;42(9):811-818.
17. Leonardo MR, Silveira FF, Silva LA, Tanomaru Filho M, Utrilla LS. Calcium hydroxide root canal dressing. Histopathological evaluation of periapical repair at different time periods. *Braz Dent J* 2002;13(1):17-22.
18. Garcia de Paula-Silva FW, Hassan B, Bezerra da Silva LA, Leonardo MR, Wu MK. Outcome of root canal treatment in dogs determined by periapical radiography and cone-beam computed tomography scans. *J Endod* 2009 May;35(5):723-726.
19. Vera J, Siqueira JF Jr, Ricucci D, Loghin S, Fernandez N, Flores B, Cruz AG. One- versus two-visit endodontic treatment of teeth with apical periodontitis: a histobacteriologic study. *J Endod* 2012 Aug;38(8):1040-1052.
20. Trope M, Delano EO, Orstavik D. Endodontic treatment of teeth with apical periodontitis: single vs multivisit treatment. *J Endod* 1999 May;25(5):345-350.
21. Molander A, Warfvinge J, Reit C, Kvist T. Clinical and radiographic evaluation of one- and two-visit endodontic treatment of asymptomatic necrotic teeth with apical periodontitis: a randomized clinical trial. *J Endod* 2007 Oct;33(10):1145-1148.
22. Penesis VA, Fitzgerald PI, Fayad MI, Wenckus CS, BeGole EA, Johnson BR. Outcome of one-visit and two-visit endodontic treatment of necrotic teeth with apical periodontitis: a randomized controlled trial with one-year evaluation. *J Endod* 2008 Mar;34(3):251-257.

23. Sathorn C, Parashos P, Messer HH. Effectiveness of single- versus multiple-visit endodontic treatment of teeth with apical periodontitis: a systematic review and meta-analysis. *Int Endod J* 2005 Jun;38(6):347-355.
24. Figini L, Lodi G, Gorni F, Gagliani M. Single versus multiple visits for endodontic treatment of permanent teeth: a Cochrane systematic review. *J Endod* 2008 Sep;34(9):1041-1047.
25. Sathorn C, Parashos P, Messer H. The prevalence of postoperative pain and flare-up in single- and multiple-visit endodontic treatment: a systematic review. *Int Endod J* 2008 Feb;41(2):91-99.
26. Su Y, Wang C, Ye L. Healing rate and post-obturation pain of single- versus multiple-visit endodontic treatment for infected root canals: a systematic review. *J Endod* 2011 Feb;37(2):125-132.
27. Souza-Flamini LE, Leoni GB, Chaves JF, Versiani MA, Cruz-Filho AM, Pecora JD, Sousa-Neto MD. The radix entomolaris and paramolaris: a micro-computed tomographic study of 3-rooted mandibular first molars. *J Endod* 2014 Oct;40(10):1616-1621.
28. European Society of Endodontology. Quality guidelines for endodontic treatment: consensus report of the European Society of Endodontology. *Int Endod J* 2006 Dec;39(12):921-930.
29. dePaula-Silva FW, Santamaria MJr, Leonardo MR, Consolaro A, da Silva LA. Cone-beam computerized tomographic, radiographic, and histologic evaluation of periapical repair in dogs' post-endodontic treatment. *Oral Surg Oral Med Oral Pathol Oral Radiol Endod* 2009 Nov;108(5):796-805.
30. Weiger R, Rosendahl R, Lost C. Influence of calcium hydroxide intracanal dressings on the prognosis of teeth with endodontically induced periapical lesions. *Int Endod J* 2000 May;33(3):219-226.
31. Patel S, Wilson R, Dawood A, Mannocci F. The detection of periapical pathosis using periapical radiography and cone beam computed tomography – part 1: pre-operative status. *Int Endod J* 2012 Aug;45(8):702-710.
32. Metska ME, Parsa A, Aartman IH, Wesselink PR, Ozok AR. Volumetric changes in apical radiolucencies of endodontically treated teeth assessed by cone-beam computed tomography 1 year after orthograde retreatment. *J Endod* 2013 Dec;39(12):1504-1509.
33. Fernandez R, Cadavid D, Zapata SM, Alvarez LG, Restrepo FA. Impact of three radiographic methods in the outcome of non-surgical endodontic treatment: a five-year follow-up. *J Endod* 2013 Sep;39(9):1097-1103.
34. van der Borden WG, Wang X, Wu MK, Shemesh H. Area and 3-dimensional volumetric changes of periapical lesions after root canal treatments. *J Endod* 2013 Oct;39(10):1245-1249.