

CASE REPORT

Primary Hyperaldosteronism: Typical Clinical Manifestations

¹Amit A Bharadiya, ²GS Karthik, ³DVSNL Sharma, ⁴V Shanta Ram

ABSTRACT

A 34-year-old lady presented to the hospital with symptoms of headache and exertional dyspnea. On examination, she was found to have blood pressure of 180/120 mm Hg, which was confirmed and her blood pressure was unresponsive to standard antihypertensive therapy. She had easily inducible and unprovoked hypokalemia even on small doses of diuretic. The possibility of primary hyperaldosteronism was considered. Her plasma aldosterone was high with low plasma renin activity, confirming the biochemical diagnosis of hyperaldosteronism. She underwent workup with computed tomography of the abdomen that showed left adrenal mass, likely an adenoma. After proper medical preparation, she underwent laparoscopic adrenalectomy. Upon successful removal of the adrenal mass, her aldosterone, renin, potassium, and blood pressure levels were normalized. This case illustrates classical features of primary hyperaldosteronism with clinical diagnostic and therapeutic considerations.

Keywords: Hypokalemia, Primary hyperaldosteronism, Secondary hypertension.

How to cite this article: Bharadiya AA, Karthik GS, Sharma DVSNL, Ram VS. Primary Hyperaldosteronism: Typical Clinical Manifestations. *Hypertens J* 2016;2(2):105-107.

Source of support: Nil

Conflict of interest: None

INTRODUCTION

Systemic hypertension is a common risk factor for cardiovascular disease (CVD), premature morbidity, disability, and excessive mortality. Of all the contributing factors for CVD in India (and globally), hypertension is widely prevalent. Despite the decades of professional and public education, hypertension is vastly underdiagnosed and often undertreated. Therefore, in a large proportion

Table 1: Features of primary aldosteronism

Sl. no.	Features of PA
1	Hypertension
2	Unprovoked, unexplained hypokalemia
3	High normal serum sodium, metabolic alkalosis
4	↑ Aldosterone level
5	↓ Renin activity

of patients, blood pressure level is not under control. An overwhelming majority of patients with hypertension have “primary” type, wherein a specific underlying cause is not identified. A small percentage (about 5%) has “secondary” hypertension, wherein an underlying cause for blood pressure elevation exists. In secondary forms of hypertension, some are curable by correcting the underlying cause, while in others, blood pressure level improves with “specific” medical treatment to counter the causative mechanisms. Primary aldosteronism (PA), also called hyperaldosteronism, is an uncommon cause of secondary hypertension occurring in about 1% of all patients. Primary aldosteronism is a result of spontaneous autonomous excessive production of aldosterone by the glomerular zone of the adrenal glands. Some believe that the incidence is much higher than the reported figures due to improved diagnostic methods. The manifestations of PA comprise hypertension, (inappropriate) hypokalemia, low plasma renin activity, and high aldosterone levels¹⁻⁵ (Table 1). The specific treatment of PA depends on the pathological subtype responsible for the disease. We present a case of PA detected during the course of managing new-onset hypertension in a young patient.

CASE REPORT

A 34-year-old lady presented to our hospital with chronic bifrontal headache and exertional dyspnea of 6 months duration. Three months prior to the hospital visit, she was examined by a physician and diagnosed to have high blood pressure of 180/120 mm Hg for which she was prescribed tablet olmesartan and hydrochlorothiazide once a day (40/12.5 mg). On follow-up, she was found to have persistently high blood pressure of > 160/100 mm Hg for which she was further evaluated. Her complete reports on blood, blood urea, serum creatinine, and urine examinations were normal. However, two-dimensional (2D) echo showed concentric left ventricular hypertrophy with

¹Registrar, ²Resident, ³Consultant, ⁴Professor

¹Department of Cardiology, Apollo Hospital, Hyderabad Telangana, India

²Department of Internal Medicine, Apollo Hospital, Hyderabad Telangana, India

³Department of Urology, Apollo Hospital, Hyderabad, Telangana India

⁴Department of Medicine, Nizams Institute of Medical Sciences Hyderabad, Telangana, India

Corresponding Author: Amit A Bharadiya, Registrar, Department of Cardiology, Apollo Hospital, Hyderabad, Telangana, India
 Phone: +919000090339, e-mail: dr.aabharadiya@gmail.com

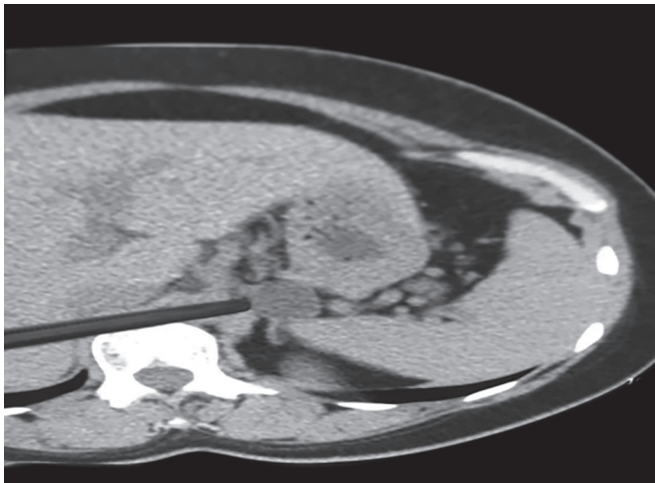


Fig. 1: Computed tomography scan showing left adrenal mass and normal right adrenal gland

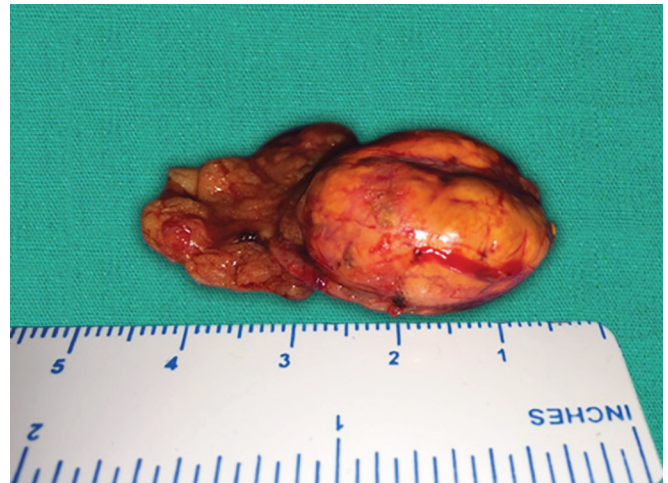

Fig. 2: Gross appearance of left adrenal gland with the mass after surgical removal

normal ejection fraction. Due to the persistent high blood pressure, the patient was referred to us for further evaluation. Based on her past history of hypokalemia, blood samples were sent for serum electrolytes, which showed serum sodium as 143 mEq/L and serum potassium as 2.3 mEq/L. Plasma aldosterone was high (582 pmol/mL) and plasma renin activity was low (0.17 ng/mL/hour). Due to the high aldosterone to renin ratio (3423 pmol/L:ng/mL/hour), primary hyperaldosteronism was suspected. Computed tomography (CT) of the abdomen revealed a well-defined hypodense lesion of size 25×16 mm in the left adrenal gland, which was most likely to be an adenoma (Fig. 1). After 3 to 4 weeks of medical treatment with spironolactone to normalize her potassium level, she underwent laparoscopic left adrenalectomy, which was successfully accomplished with an uneventful recovery (Fig. 2). After the 3rd postoperative day, plasma aldosterone levels were measured again and were 29.39 pmol/mL; further, plasma renin activity was 0.46 ng/mL/hour, sodium levels were normal, potassium levels were 3.8 mEq/L, and blood pressure was 110/80 mm Hg without any antihypertensive drugs. Adrenal specimen was proved to be adenoma by histopathology. She was normotensive without any antihypertensive drugs even at her follow-up visit after a month (Table 2).

DISCUSSION

Secondary forms of hypertension constitute only a small number in the vast ocean of patients with hypertension.

Table 2: Blood pressure and potassium levels after removal of adrenal mass

	Prior to surgery	After surgery follow-up
Blood pressure (mmHg)	180/120 (on 3 anti-hypertensive drugs)	110/80 (on no medications)
Potassium level (mEq/L)	2.3	4.5

Although unusual, secondary causes of hypertension by no means are rare in clinical practice. It is important to recognize secondary forms of hypertension because specific medical or corrective treatment may reverse the disorder. When the pathophysiology of a secondary cause is offset by “specific” therapy, blood pressure shows remarkable improvement, and in some patients, it can be curative. The suspicion of a PA depends on the presenting clinical features and laboratory findings. This case report represents a typical patient with manifestations of PA comprising hypertension, hypokalemia, metabolic alkalosis, low plasma renin activity, and high aldosterone level. Whenever a patient with hypertension demonstrates unexplained and inappropriate hypokalemia, PA should be considered in the differential diagnosis. Upon confirmation of hypokalemia (by repeat testing), the possibility of PA should be pursued. The biochemical hallmarks of PA are suppressed renin and elevated aldosterone levels.⁶⁻⁸ One should remember that increased renin with elevated aldosterone level is symbolic of “secondary” aldosteronism comprising diuretic use, volume depletion, vasodilatory drugs, and renal ischemia. However, suppressed renin and high aldosterone level are pathognomonic of PA in a patient with hypertension and unexplained hypokalemia. Once the biochemical diagnosis of PA is made, the next diagnostic step is to determine if the adrenal disease is unilateral (adenoma) or bilateral (hyperplasia). The former is best managed by surgical removal of affected gland, whereas the latter is best managed by chronic medical therapy inclusive of an aldosterone antagonist (spironolactone).⁹⁻¹¹ It should be kept in mind that an aldosterone producing adenoma can be treated medically if surgery is not possible but a bilateral adrenal hyperplasia should always be managed with medical therapy only; surgery is not recommended. A properly done CT scan of the adrenal glands (with

small thin cuts) and/or magnetic resonance imaging (MRI) should suffice in the radiological localization of PA. Due to technical difficulties and challenges in locating the right adrenal vein, we do not recommend adrenal vein catheterization for diagnostic purpose. It is best to make therapeutic plans and follow-up on the basis of well-performed CT or MRI of adrenal glands. Similarly, adrenal gland scintigraphy is not generally required to localize PA.¹² In summary, PA is an unusual cause of hypertension. However, it is amenable to specific surgical or medical therapy that ameliorates hypokalemia and improves the blood pressure control as was demonstrated in our patient. Hypertension can be severe in patients with PA and can cause target organ damage.^{13,14} The clinical diagnosis is suspected on the basis of unexplained hypokalemia in a patient with hypertension and high aldosterone; further, it can be confirmed by aldosterone - renin ratio (ARR) and radiological findings on a CT scan (thin slice) or MRI of the adrenal glands. Depending on the unilaterality or bilaterality of the adrenal gland abnormality, specific medical or surgical therapy is planned, which cures hypokalemia and often improves or cures hypertension as well.

REFERENCES

1. Ram CVS. Primary aldosteronism – recognition and management. *Rhode Island Med J* 1977 Jun;60(6):301-305.
2. Ram CVS. Primary aldosteronism – its role in hypertension. *Consultant* 1981;21:2-11.
3. Ram CVS. Hypertension: when to suspect underlying pheochromocytoma or aldosteronism. *Consultant* 1996;33:147-153.
4. Lim PO, Rodgers P, Cardale K, Watson AD, MacDonald TM. Potentially high prevalence of primary aldosteronism in a primary-care population. *Lancet* 1999 Jan 2;353(9146):40.
5. Loh KC, Koay ES, Khaw MC, Emmanuel SC, Young WF Jr. Prevalence of primary aldosteronism among Asian hypertensive patients in Singapore. *J Clin Endocrinol Metab* 2000 Aug;85(8):2854-2859.
6. Stowasser M, Gordon RD. The aldosterone-renin ratio for screening for primary aldosteronism. *Endocrinologist* 2004;14:267-276.
7. Stowasser M, Gordon RD. Primary aldosteronism: careful investigation is essential and rewarding. *Mol Cell Endocrinol* 2004 Mar 31;217(1-2):33-39.
8. Oliveri O, Ciacciarelli A, Signorelli D, Pizzolo F, Guarini P, Pavan C, Corgnati A, Falcone S, Corrocher R, Micchi A, et al. Aldosterone to renin ratio in a primary care setting. The Bussolengo study. *J Clin Endocrinol Metab* 2004 Sep;89(9):4221-4226.
9. Rutherford JC, Taylor WL, Stowasser M, Gordon RD. Success of surgery in primary aldosteronism judged by residual autonomous aldosterone production. *World J Surg* 1998 Dec;22(12):1243-1245.
10. Rutherford JC, Stowasser M, Tunny TJ, Klemm SA, Gordon RD. Laparoscopic adrenalectomy. *World J Surg* 1996;20(7):758-760.
11. Parthasarathy HK, Ménard J, White WB, Young WF Jr, Williams GH, Williams B, Ruilope LM, McInnes GT, Connell JM, MacDonald TM. A double-blind, randomized study comparing the antihypertensive effect of eplerenone and spironolactone in patients with hypertension and evidence of primary aldosteronism. *J Hypertens* 2011 May;29(5):980-990.
12. Stowasser M, Gordon RD, Rutherford JC, Nikwan NZ, Daunt N, Slater GJ. Diagnosis and management of primary aldosteronism. *J Renin Angiotensin Aldosterone Syst* 2001 Sep;2(3):156-169.
13. Rossi GP, Sacchetto A, Visentin P, Canali C, Graniero GR, Palatini P, Pessina AC. Changes in left ventricular anatomy and function in hypertension and primary aldosteronism. *Hypertension* 1996 May;27(5):1039-1045.
14. Rossi GP, Bernini G, Desideri G, Fabris B, Ferri C, Giacchetti G, Letizia C, Maccario M, Mannelli M, Matterello MJ. Renal damage in primary aldosteronism: results of the PAPY study. *Hypertension* 2006 Aug;48(2):232-238.

