

Subglottic Carcinoma: Treatments and Outcomes

Nirupoma Moran

ABSTRACT

Background and objective: Subglottic malignancies are rare. Most of these are predominantly squamous cell carcinoma and common in male. It is usually advanced when initially presented. This study was to analyze the clinical presentation, treatments, and outcomes of subglottic carcinoma.

Materials and methods: The study was conducted in the Department of Otorhinolaryngology and Head Neck Surgery, Assam Medical College, Dibrugarh, Assam, India, between March 2014 and September 2015.

Results: Of the three patients, two had lymph node metastasis and intralaryngeal involvements. The patients have been followed up till date. All the patients were tracheostomized and received radiotherapy and chemotherapy.

Conclusion: Subglottic carcinoma is relatively rare in comparison with supraglottic and glottic carcinoma. It is presented at advance stage and tend to spread larynx and other organs too.

Keywords: Chemotherapy and radiotherapy, Malignancies, Squamous cell carcinoma, Subglottic, Tracheostomized.

How to cite this article: Moran N. Subglottic Carcinoma: Treatments and Outcomes. *Int J Phonosurg Laryngol* 2016;6(1):14-16.

Source of support: Nil

Conflict of interest: None

INTRODUCTION

Subglottic region extending from the lower border of the cricoids to the under surface of the vocal cords. The subglottis is the rarest region to be affected by laryngeal cancer. They constitute about 1% of laryngeal cancer. Most of these are squamous cell carcinoma. Cancer of the thyroid gland and the trachea can spread to involve the subglottis, and cancers of the subglottis spread to the thyroid gland, in 20% of cases, and to the trachea. Twenty percent cases also involve the strap muscles of the neck, and same percentage gives rise to cervical node metastases.¹ It commonly affects the male and main prevailing factor is smoking.

The origin of most cancers in this area is the glottis cancer that extends into the subglottic region. The delayed

diagnosis is due to the lack of symptoms in the early stage of the disease and the hidden location of the tumor.²

Early presentations may be vague, with a feeling of "Globus" or foreign body sensation in the throat. If the vocal cord is involved early, the presenting symptom is hoarseness. Circumferential progression leads to progressive dyspnea and stridor. Direct extension into the thyroid may mimic a thyroid isthmus lesion.³

Staging of the subglottic cancer:⁴

Tx	Primary tumor cannot be assessed
T0	No evidence of primary tumor
Tis	Carcinoma <i>in situ</i>
T1	Tumor limited to the subglottis
T2	Tumor extends to vocal cord(s), with normal or impaired mobility
T3	Tumor limited to the larynx, with vocal cord fixation
T4a	Moderately advanced, local disease Tumor invades cricoids or thyroid cartilage and/or invades tissues beyond the larynx (e.g., trachea, soft tissues of the neck, including deep extrinsic muscle of the tongue, strap muscles, thyroid, or esophagus)
T4b	Very advanced, local disease Tumor invades prevertebral space, encases carotid artery or invades mediastinal structures

Regional lymph nodes (N)

Nx	Regional nodes cannot be assessed
N0	No regional lymph node metastasis
N1	Metastasis in a single ipsilateral lymph node = 3 cm in greatest dimension
N2	Metastasis in a single ipsilateral lymph node > 3 cm but not more than 6 cm in greatest dimension; or in multiple ipsilateral lymph nodes; none > 6 cm in greatest dimension; or in bilateral or contralateral lymph nodes, none > 6 cm in greatest dimension
N2a	Metastasis in a single ipsilateral lymph node > 3 cm but not more than 6 cm in greatest dimension
N2b	Metastasis in multiple ipsilateral lymph nodes, none > 6 cm in greatest dimension
N2c	Metastasis in bilateral or contralateral lymph nodes, none > 6 cm in greatest dimension
N3	Metastasis in a lymph node > 6 cm in greatest dimension

Distant metastasis (M)

M0	No distant metastasis
M1	Distant metastasis

Histological grades (G)

GX	Grade cannot be assessed
G1	Well differentiated
G2	Moderately differentiated
G3	Poorly differentiated
G4	Undifferentiated

Postgraduate

Department of ENT, Assam Medical College, Dibrugarh, Assam India

Corresponding Author: Nirupoma Moran, Postgraduate Department of ENT, Assam Medical College, Dibrugarh, Assam India, Phone: +919706449377, e-mail: nirupamamoran50@gmail.com

Prognostic groups			
Stage	T	N	M
O	Tis	N0	M0
I	T1	N0	M0
II	T2	N0	M0
III	T3	N0	M0
	T1	N1	M0
	T2	N1	M0
	T3	N1	M0
IVA	T4a	N0	M0
	T4a	N0	M0
	T1	N2	M0
	T2	N2	M0
	T3	N2	M0
	T4a	N2	M0
IVB	T Any	N3	M0
	T4b	N Any	M0
IVC	T Any	N Any	M1

Grades I and II are early stage and III and IV are treated as late-stage tumor. Prognosis of the subglottic carcinoma is very poor.

Our current aim of the study was to analyze the clinical presentation, treatments, and outcomes of subglottic carcinoma.

MATERIALS AND METHODS

The study was conducted in the Department of Otorhinolaryngology and Head and Neck Surgery, Assam Medical College, Dibrugarh, Assam, India, between March 2014 and September 2015. Total three cases were included in this study. During this period we found three patients. History, clinical assessment, and histopathological examination (HPE) were done in all cases supplemented by radiological examination investigations, such as X-ray, posteroanterior view, computed tomography (CT) scan as per requirement. History details of the patients were obtained, including age,

sex, and socioeconomic status, and duration of the disease, followed by thorough clinical examination, necessary radiological, and hematological investigations.

All the patients were referred for external beam radiation with cobalt therapy and chemotherapy.

RESULTS AND OBSERVATIONS

In the present study, three patients were analyzed. All the patients were above 60 years male. They had history of smoking more than 30 years. Two patients presenting to the outpatients department were treated with hoarseness and one patient with stridor. Out of the three patients, two had right-sided cervical level-II lymph node at the time of presentation. Size of the neck node was approximately 3 cm. It was hard and fixed to the underlying structures. Indirect laryngoscopy was done paresis of the vocal cords were seen at the right side of the patients. Fine needle cytology was advised for the right-side cervical lymph node level II. Direct laryngoscopy was done and growth was noted. The mass was biopsied, and it came to be squamous cell carcinoma. Computed tomography scan report showed involvement of vocal cords, but no thyroid or cricoid cartilage involvement. The patients were graded as stage III – T2N1M0. They were referred to radiotherapy department for external beam radiation. The patients did not attend the radiotherapy department and lost follow-up for 2 months. After 2 to 3 months gap of initial examination, they attended the emergency department with stridor. Emergency tracheostomy was done (Fig. 1).

Another patient attended emergency department of ENT with stridor, and this was his first visit. Emergency tracheostomy was done and biopsy was taken at the time of surgery (Fig. 2).

The patient was graded as stage I – T1NOMO. This patient's general condition was not good, so surgical option was not offered.

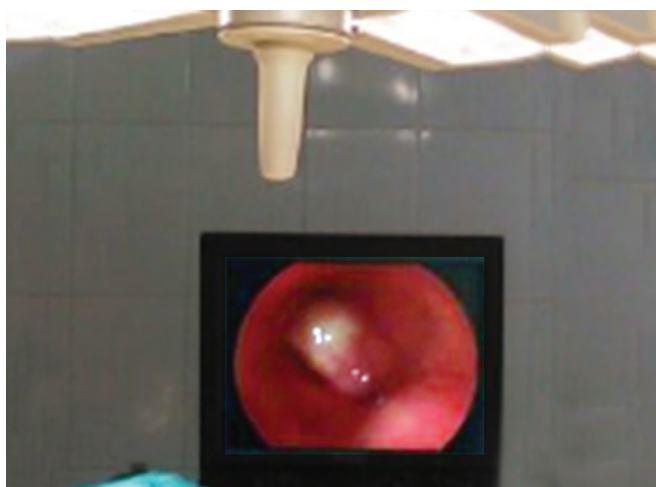


Fig. 1: Subglottic growth



Fig. 2: Subglottic growth obstructing the lumen

Subsequently, all the three patients were completed 30 cycle of external beam radiation and six cycle of chemotherapy. They were apparently normal in their regular follow-up for last 6 months.

DISCUSSION

Laryngeal cancer is the eleventh most common cancer in men worldwide, but it is relatively uncommon in women. Squamous cell carcinoma is by far the most common type of tumor, comprising 90% or more of all laryngeal malignancies.¹

Subglottic carcinoma accounts for less for all laryngeal cancers. Cancers of the subglottic region tend to invade adjacent structures early in the course of their disease and are often quite extensive by the time symptoms appear. Presenting symptoms include hoarseness from laryngeal invasion and stridor from airway obstruction. Clinically detectable nodal metastasis is rare, but the paratracheal and mediastinal nodes may be involved.

Due to the rarity of subglottic carcinomas, treatment has been based on institutional and physician preference.

Paisley et al⁵ found primary radiotherapy in the treatment of patients with primary squamous cell carcinoma of the subglottis as an appropriate treatment approach providing an option for laryngeal conservation.

In a study by Guedea et al,⁶ six patients with primary squamous cell carcinoma of the subglottis were treated with radical radiation therapy at the University of Florida. The disease was staged as Tis (one patient), T2N0 (two patients), and T4N0 (three patients). Local control was achieved with irradiation in four patients (66%) who were observed for 3.5, 4, 4, and 5 years after radiation therapy.

In a retrospective study by Garas et al⁷ over a 25-year period, patients with laryngeal carcinoma were treated by the Department of Otolaryngology at Wake Forest University. The patients were grouped by treatment modality of surgery alone, surgery and radiotherapy, radiotherapy alone, and radiotherapy with surgical salvage. All patients had squamous cell carcinoma of the subglottis of which 20% (3/15) had early-stage disease (T1-T2) and 80% (12/15) had late-stage disease (T3-T4). Overall 3-year survival was low (25%) and is attributed to a high incidence of advanced-stage disease with a high rate of extralaryngeal spread and/or metastasis, especially to the lungs and paratracheal nodes.

Department of Veterans Affairs Laryngeal Cancer Study Group⁸ offered potential value of induction

chemotherapy plus radiation in achieving laryngeal preservation with survival rates comparable to surgery as the primary treatment for advanced laryngeal cancer.

Megwalu et al⁹ and Misono et al¹⁰ showed surgery might be better therapy for better survival outcomes than nonsurgical therapy for patients with advanced laryngeal cancer.

However, in our study all the three patients we offered chemoradiation and afferently normal till date.

CONCLUSION

This study has shown that of smoking was the main causative factor for subglottic carcinoma. In case of laryngeal conservation, chemoradiation for primary squamous cell glottic carcinoma is an appropriate treatment.

REFERENCES

1. Maran AGD. Cancer of the larynx. In: Hussain SM, editor. Logan Turner's Diseases of the nose, throat and ear: Head neck surgery. 11th ed. Vol. 17. CRC Press; 2015. p. 172-175.
2. Bahar G, Nageris BL, Spitzer T, Popovtzer A, Mharshak G, Feinmesser R. Subglottic carcinoma. Harefuah 2002 Oct;141(10): 914-918, 929.
3. Birchall MA, Pope L. Tumors of the larynx. In: Gleeson M, Browning GG, Burton MJ, Clarke R, editors. Scott-Brown's otorhinolaryngology, head and neck surgery. 7th ed. Vol. 2. London: Hodder Arnold; 2008. p. 2598-2608.
4. National Comprehensive Cancer Network. NCCN Clinical practice guidelines in oncology: head and neck cancers. Vol. 1. 2012.
5. Paisley S, Warde PR, O'Sullivan B, Waldron J, Gullane PJ, Payne D, Liu FF, Bayley A, Ringash J, Cummings BJ. Results of radiotherapy for primary subglottic squamous cell carcinoma. Int J Radiat Oncol Biol Phys 2002 Apr1;52(5):1245-1250.
6. Guedea F, Parsons JT, Mendenhall WM, Million RR, Stringer SP, Cassisi NJ. Primary subglottic cancer: results of radical radiation therapy. Int J Radiat Oncol Biol Phys 1991 Nov;21(6):1607-1611.
7. Garas J, McGuirt WF Sr. Squamous cell carcinoma of the subglottis. Am J Otolaryngol 2006 Jan-Feb;27(1):1-4.
8. The Department of Veterans Affairs Laryngeal Cancer Study Group. Induction chemotherapy plus radiation compared with surgery plus radiation in patients with advanced laryngeal cancer. N Engl J Med 1991;324:1685-1690.
9. Megwalu UC, Sikora AG. Survival outcomes in advanced laryngeal cancer. JAMA Otolaryngol Head Neck Surg 2014 Sep;140(9):855-860.
10. Misono S, Marmor S, Yueh B, Virnig BA. Cancer treatment and survival in 10,429 patients with localized laryngeal cancer: a population-based analysis. Cancer 2014 Jun15;120(12): 1810-1817.