



Outcome Analysis in Patients with Benign Vocal Fold Lesions

¹Nitish Virmani, ²Arpit Sharma, ³Jyoti Dabholkar

ABSTRACT

Introduction: Benign vocal cord lesions cause significant dysphonia by disrupting the normal vibratory function of the vocal fold mucosa. Multidimensional assessment of voice characteristics allows for an accurate analysis of voice impairment and can be used to assess the outcome of different treatment modalities.

Aims: To evaluate the outcome in patients treated for benign vocal fold lesions using multidimensional voice assessment.

Materials and methods: Thirty adult patients with benign vocal fold lesions were treated according to standard protocols and followed up for 6 months. Voice was evaluated by visual analog scale (VAS), GRBAS (grade, roughness, breathiness, asthenia, strain) scale, maximum phonation time (MPT), S/Z ratio, and acoustic parameters using PRAAT. Pre- and posttreatment voice was compared.

Results: Benign lesions observed were vocal polyps (16), vocal nodules (7), vocal fold cysts (5), vocal cord papilloma (1), and sulcus vocalis (1). Mean VAS rating improved from 7.5 to 2 at 3 months and 1.6 at 6 months. Mean GRBAS score improved from 7.5 to 2.96 at 3 months and 2.3 at 6 months. Maximum phonation time increased from 9.43 seconds to 14.16 seconds at 3 months and 14.46 seconds at 6 months. S/Z ratio reduced from 1.37 to 1.16 at 3 months and 1.15 at 6 months. Jitter reduced from 1.81 to 1% at 3 months and 0.97% at 6 months; shimmer decreased from 6.07 to 2.19% at 3 months and to 2.03% at 6 months. Harmonic-to-noise ratio values improved from 8.01 to 10.78 dB at 3 months and 10.96 dB at 6 months; mean F₀ increased from 207.27 to 217.89 Hz at 3 months and 219.65 Hz at 6 months.

Conclusion: A single measurement of voice cannot be used as a reliable outcome measure. Perceptual, aerodynamic, acoustic, and self-analysis together allow a multidimensional assessment of voice characteristics.

Keywords: Benign vocal fold lesions, Dysphonias, Outcome analysis, Phonosurgery, Speech therapy, Voice assessment.

How to cite this article: Virmani N, Sharma A, Dabholkar J. Outcome Analysis in Patients with Benign Vocal Fold Lesions. *Int J Phonosurg Laryngol* 2016;6(1):8-13.

Source of support: Nil

Conflict of interest: None

INTRODUCTION

Dysphonia refers to any impairment of the voice or difficulty in speaking. It has been defined as a speech disorder resulting in impaired utterance of sounds by the vocal folds or any speech disorder involving problems of voice quality, pitch, or intensity under the diagnosis code 784.42 in ICD-9 (International Classification of Diseases, Ninth Revision). More than 50% of patients seeking medical attention because of voice change have a benign mucosal disorder.¹

Benign vocal fold lesions mostly consist of vocal nodule, vocal polyp, vocal cord cyst, sulcus vocalis, and vocal papilloma. These lesions are pathological tissue changes in the microstructure of the vocal fold mucosa in response to phonotrauma, either abuse or functional misuse of normal or compromised tissue. The lesions cause varying degrees of disturbance to vocal fold oscillation and glottic closure, rendering the voice rough, breathy, inefficient, and subject to vocal fatigue. Cigarette smoking, infections, allergy, and acid reflux increase the mucosa's vulnerability to vibratory trauma leading to injury. In vocal cord lesions, multidimensional assessment of voice characteristics allows for an accurate analysis of voice impairment. Perceptual analysis by a speech-language pathologist (SLP) provides a subjective assessment of disturbance in the different qualities of voice. Distortion of voice signal can be objectively demonstrated by acoustic analysis using a variety of softwares. PRAAT is one such freeware program which can be used for acoustic analysis.² Self-analysis by a patient allows measurement of handicap resulting from a vocal fold lesion. The aim of this prospective study was to assess the voice in different dimensions using aerodynamic analysis, GRBAS (grade, roughness, breathiness, asthenia, strain), acoustic analysis, and self-analysis before and after treatment in patients with benign vocal cord lesions.

¹Speciality Medical Officer, ²Assistant Professor, ³Professor and Head

¹⁻³Department of ENT and Head-Neck Surgery, Seth GS Medical College and King Edward Memorial Hospital, Mumbai Maharashtra, India

Corresponding Author: Nitish Virmani, Speciality Medical Officer, Department of ENT and Head-Neck Surgery, Seth GS Medical College and King Edward Memorial Hospital Mumbai, Maharashtra, India, Phone: +919702980431, e-mail: nitish_virmani@yahoo.com

MATERIALS AND METHODS

The study was conducted as a prospective study between January 2013 and August 2014 in the ENT division of our hospital, a tertiary-care referral center. A total of 30 adult patients, presenting to the outpatient department with complaints of change in voice and found to have clinical evidence of a benign vocal fold lesion, were enrolled into this study. Laryngeal examination was done using a 70° rigid endoscope. Voice assessment was carried out using self-analysis scale, aerodynamic analysis, perceptual evaluation, and acoustic analysis.

The patients underwent treatment according to standard protocols. Patients with vocal polyps, vocal cord cysts, and vocal cord papilloma underwent microlaryngeal excision as the definitive treatment. Injection laryngoplasty with hyaluronic acid was used for sulcus vocalis. A policy of 2 weeks of complete voice rest after surgery was adopted. Postoperative speech therapy was provided for all patients by a certified SLP. The patients with vocal nodules underwent speech therapy as the primary treatment modality. If vocal nodules failed to regress in size and/or the patient's voice failed to improve after 3 months of conservative treatment, patients were offered microlaryngeal surgery for excision of nodules.

The patients were followed up for 6 months. Indirect laryngoscopy using 70° rigid endoscope was done to look for recurrences or scarring in the surgical group. Change in the size of nodules was noted. Voice was reassessed using the same parameters. The parameters were assessed as follows:

- Self-analysis: Patient's own acceptability of his/her voice was assessed by asking the patient to rate his/her quality of voice on a visual analog scale (VAS) of 1 to 10, ranging from totally normal/acceptable (1) to totally abnormal/unacceptable (10).
- Perceptual voice evaluation: This was done by a trained SLP, using GRBAS scale that consists of five parameters: Overall grade of hoarseness, roughness, breathiness, asthenia, and strain. Each parameter was rated by the SLP on a scale of 0 to 3.
- Aerodynamic analysis: This was done to evaluate glottic efficiency using two parameters: S/Z ratio and maximum phonation time (MPT).
 - S/Z ratio: A patient was asked to take a deep breath and then to sustain the sound "s" for as long as possible at a comfortable pitch and loudness on one exhalation, without straining. The time was recorded as first "s". The procedure was repeated for the sound "z", and the duration recorded as first "z". The procedure was repeated for a total of three attempts, and the S/Z ratio was calculated by dividing the longest duration of "s" by the longest

duration of "z". A ratio of 1.4 was considered as abnormal or indicating a degree of vocal cord dysfunction.

- Maximum phonation time (MPT): A patient was asked to take a deep breath and then to sustain the vowel sound "a" for as long as possible at a comfortable pitch and loudness on one exhalation, and without straining. The time was recorded. The procedure was repeated for a total of three attempts, and MPT was calculated as the average of these three phonation times.
- Acoustic analysis: The patient's voice sample was recorded during sustained phonation of a steady vowel /a/. A microphone (attached to a computer) was placed off-axis at a distance of 5 cm from the speaker's lips was used to record and store the voice sample. Acoustic analysis of these voice samples was done using PRAAT software version 5.3.68.³ Acoustic voice signal data was measured for mean fundamental frequency, frequency perturbation called jitter, amplitude perturbation called shimmer, and harmonics-to-noise ratio (HNR).

STATISTICAL ANALYSIS

The data were entered into Microsoft Excel Worksheet to create the master chart. Statistical analysis was done using IBM Statistical Package for the Social Sciences (SPSS) Statistics version 22. Friedman test was used to analyze parameters with ordinal scales: VAS rating and GRBAS score. Repeated measures ANOVA was used to analyze parameters: Jitter, shimmer, fundamental frequency (F_0), HNR, MPT, and S/Z ratio.

OBSERVATIONS AND RESULTS

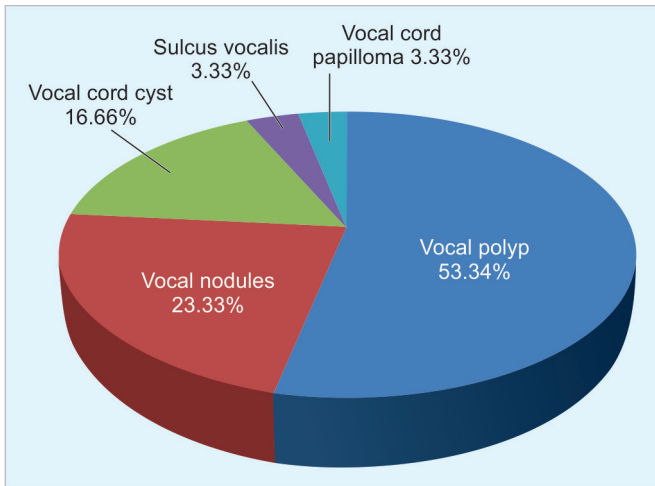
Of the 30 patients recruited into this study, 19 were males and 11 were females. The age range of the study group was 20 to 62 years while the mean was 42.23 years. The benign lesions observed in our study were (in decreasing frequency) vocal polyps (16), vocal nodules (7), vocal fold cysts (5), vocal cord papilloma (1), and sulcus vocalis (1) (Graph 1).

70° Laryngoscopy

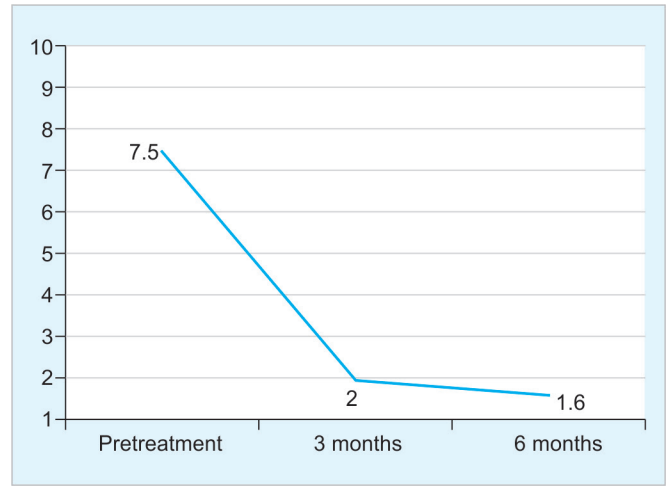
In the operative group, none of the patients revealed any recurrence or postoperative scar. All the patients with vocal nodules showed regression in the size of nodules, although in none of them did the nodules completely disappear.

Self-analysis by VAS

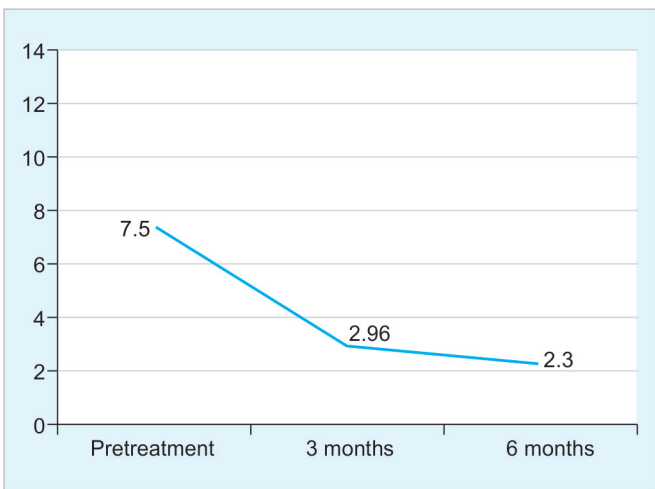
Graph 2 shows a significant improvement in the mean VAS rating from 7.5 ± 1.2 to 1.6 ± 0.7 at 6 months ($p < 0.05$).



Graph 1: Incidence of various benign lesions in our study



Graph 2: Improvement in mean VAS rating with treatment



Graph 3: Improvement in mean GRBAS (grade, roughness, breathiness, asthenia, strain) score of patients with treatment

Table 2: Improvement in mean values of acoustic parameters with treatment

	Pretreatment	3 months	6 months
Jitter (in %)	1.81±0.34	1±0.21	0.97±0.2
Shimmer (in %)	6.07±1.02	2.19±0.54	2.03±0.31
Mean F ₀ (in Hz)	207.27±14.02	217.89±10.28	219.65±9.05
HNR (in dB)	8.01±2.01	10.78±2.61	10.96±2.55

HNR: Harmonic-to-noise ratio; F₀: Fundamental frequency

Acoustic Analysis

As seen in Table 2, there was a statistically significant reduction in the mean jitter and shimmer values at 3 months after treatment. Harmonic-to-noise ratio values showed an increasing trend toward normalcy with treatment. The increase in HNR was statistically significant ($p < 0.05$). Mean fundamental frequency also showed a statistically significant increase in values with treatment ($p < 0.05$). Although, voice parameters showed a further improvement at 6 months with continued speech therapy, this difference was not statistically significant ($p > 0.05$).

Perceptual Analysis

Graph 3 highlights that mean GRBAS score significantly improved from 7.5 ± 0.82 in the pretreatment stage to 2.3 ± 1.17 at 6 months.

Aerodynamic Analysis

At 3 months, while MPT showed a statistically significant increase, the value of S/Z ratio demonstrated a significant decrease. Further improvement in these aerodynamic parameters at 6 months was not significant (Table 1).

Table 1: Improvement in mean values of aerodynamic parameters with treatment

	Pretreatment	3 months	6 months
MPT (seconds)	9.43±1.89	14.16±1.7	14.46±1.56
S/Z ratio	1.37±0.06	1.16±0.06	1.15±0.06

MPT: Maximum phonation time

DISCUSSION

Benign vocal fold lesions, such as vocal polyps, vocal nodules, vocal cord cyst, and vocal cord papilloma cause significant dysphonia by disrupting the normal vibratory function of the vocal fold mucosa. Various risk factors responsible for these lesions include chronic voice over-use/misuse, sudden phonotrauma, laryngopharyngeal reflux (LPR), allergy, smoking, and alcohol use.

While surgical intervention removes the offending lesion, speech therapy teaches patients to modify their faulty vocal behavior. By minimizing the detrimental vocal behaviors, speech therapy decreases the stress at mid-membranous vocal cords, thus optimizing the voice outcome in these patients and also preventing the

recurrences of these benign lesions.^{4,5} Speech therapy consists of five basic behaviorally based approaches: Vocal hygiene, direct facilitation of vocal production, respiratory support, muscle relaxation, and carryover.⁶ Vocal hygiene is the foundation of speech therapy. Patients are taught to take care of their vocal fold tissues by keeping them hydrated and limiting laryngeal irritants. Education regarding proper vocal hygiene and hydration and avoidance of vocal abuse, misuse, and overuse is a necessary baseline. Vocal abuse refers to phonation that is excessive in length or is produced in an overly loud manner. Loud phonation and excessive phonation lead to increased trauma in the mucosal membrane during voicing. Vocal misuse refers to dysphonia caused by inefficient methods of voice production. Inefficient vocal patterns occur when voice is produced with inappropriate laryngeal tension and/or poor respiratory support.⁷ The patient must comprehend how specific behaviors or patterns thereof may have contributed or may in the future contribute to vocal fold lesions. A course of speech therapy is often adequate in patients with vocal nodules, which are expected to resolve, regress, or at least stabilize under a regimen of improved voice hygiene and optimized voice production.⁷ Other benign lesions, such as polyps, cysts, papillomas, and sulcus vocalis require surgical intervention in addition to pre- and postoperative speech therapy. The fact that speech therapy forms an important component of treatment in addition to surgery is evident in our study where postoperative voice parameters show a further improvement after continued speech therapy. However, this further improvement was not statistically significant.

Both subjective and objective assessments of voice are critical to outcome analysis in these patients. A guideline was elaborated by the Committee on Phoniatrics of the European Laryngological Society on the basic protocol for functional assessment of voice pathology, especially for investigating the efficacy of phonosurgical treatments and evaluating new assessment techniques. It includes five different approaches: perception, videostroboscopy, acoustics, aerodynamics (phonation quotient), and subjective rating by the patient.⁸

Self-assessment measures of voice handicap provide important information regarding vocal function from the patient's perspective, particularly the effect on quality of life as produced by the voice disorder. Considering that the principle aim of treatment in benign lesions is to improve the patient's satisfaction with his own voice, it follows that assessment of voice handicap is critical to therapeutic decision-making in this group of patients. A VAS was used in our study for self-assessment. Visual analog scale rating showed a statistically significant

improvement with treatment. These results are in concordance with other studies that have assessed the voice handicap and quality of life in these patients using different scales. While Rosen⁹ and Thomas¹⁰ demonstrated a reduction in total scores on voice handicap index, Ragab¹¹ and Uloza¹² in their studies showed statistically significant improvement in VAS rating after treatment of benign lesions.

Clinicians use both formal and informal perceptual judgments to evaluate the voice quality of a patient. Various scales like GRBAS and CAPE-V are available for perceptual scoring of voice.^{13,14} We used GRBAS scale for our study, and the mean score on this scale showed a statistically significant improvement after treatment. Studies by Ragab,¹¹ Uloza,¹² and Phaniendra Kumar¹⁵ have also showed similar improvements in GRBAS score after treatment of such patients.

Intralistener as well as interlistener variations have been found in perceptual parameters in various studies which underscore the need for objective parameters of voice assessment or acoustic analysis. PRAAT is one such freeware program created by Paul Boersma and David Weenik of the Institute of Phonetics Sciences at the University of Amsterdam, available on the Web, which reliably measures the parameters of jitter, shimmer, HNR, and fundamental frequency.^{2,3} Jitter is a cycle-to-cycle variation in fundamental frequency of the voice.¹⁶ Even a subtle microinstability in the vocal fold vibration will show changes in the jitter, which is true in the cases of vocal polyps.¹⁷ Jones et al found a significant correlation between jitter and the subjective assessment of hoarseness, demonstrating that jitter is most effective for monitoring treatment responses.¹⁸ Shimmer refers to the small, rapid, cycle-to-cycle variation in the amplitude that occurs during phonation. Benign vocal fold lesions cause an increased vocal fold mass as well as poor contact between vocal fold edges during phonation. This would cause an increase in amplitude perturbation or shimmer. This explains why the values of shimmer decrease following successful treatment of benign vocal fold lesions.¹⁹ Harmonic-to-noise ratio is the ratio of the acoustic energy of the stable harmonic component to that of the noise. It was first reported in 1982 and has been successfully applied to evaluate the effectiveness of the treatments for hoarseness.²⁰ The prevention of complete glottal closure by the intrusion of an additional surface mass induces interharmonic noise into the vocal signal, and asymmetric structural changes in the vocal cords induce waveform perturbations. These factors contribute to an increase in jitter and shimmer, and a decrease in HNR and MPT. The use of the S/Z ratio as an indicator of laryngeal pathology was first proposed by Eckel and

Boone in 1981. It appeared from their data that when an additive mass developed along the glottal margin, vocal fold approximation was less efficient. They concluded that this decrement in efficiency resulted in a decrease in glottal resistance, increasing air flow, and a shortened phonatory duration time.²¹

The improvement in acoustic parameters is variably reported in literature. Ragab et al, in a randomized controlled trial on 50 patients with benign vocal fold lesions, observed that both "jitter" and "shimmer" decreased significantly after surgery in both cold knife and radiosurgical excision groups ($p < 0.001$), with no significant difference being noticed between the two groups ($p > 0.05$).¹¹ Uloza et al observed that while there was a statistically significant ($p < 0.001$) improvement in mean jitter, shimmer, and normalized noise energy (NNE) indices as measured from the preoperative to postoperative performance, the mean of F_0 of a sustained vowel (a) at a comfortable pitch level did not show any statistically significant changes from preoperative to postoperative samples.¹² Toran,²² Stajner-Katusić,²³ and Petrović-Lazić²⁴ showed significant improvement in jitter, shimmer, HNR, and F_0 investigated after the surgery. Thomas in his study on 30 patients with benign vocal fold lesions concluded that while jitter, shimmer, and HNR showed improvement and a trend toward, statistically the values were not significant.¹⁰ Wang and Shi concluded that the values of jitter, shimmer, noise-to-harmonic ratio, and maximal phonation time showed a significant change after surgery.^{25,26}

Valadez and Tezcaner studied the effect of voice therapy in patients with vocal nodules. A significant improvement was found in the acoustic analysis parameters of jitter, shimmer, and noise-to-harmonic ratio.^{27,28} Treole found that there was no significant difference in maximum phonation duration or S/Z ratio before and after treatment. Results revealed that females with vocal nodules demonstrated measurements before therapy similar to measures considered to be normal in persons without vocal nodules.²⁹

With the removal of a mass lesion, several mechanisms can improve vibratory function. Vocal fold modulation of the air flow is restored, airflow leakage is improved, and glottal efficiency is increased. The symmetry of the vocal fold mass is restored, resulting in the stability and vibratory equivalence of each vocal fold. A smooth edge is created, facilitating improved vocal fold contact, and thereby allowing the normal generation of subglottic pressure and better amplitude of vocal fold vibrations. Although, the above has been postulated in literature to explain the alteration of acoustic variables in patients with vocal polyps, it would hold true for other benign vocal fold lesions as well.²⁶

CONCLUSION

A single measurement of voice cannot be used as a reliable outcome measure. Perceptual, aerodynamic, acoustic and self-analysis together allow a multidimensional assessment of voice characteristics. Such an assessment allows a researcher or a clinician to successfully measure voice outcome both subjectively and objectively. This outcome analysis can be used to assess the efficacy of a particular treatment for benign laryngeal lesions or to compare multiple treatments.

Microsurgical laryngeal surgery offers excellent results in patients with benign vocal fold lesions. The importance of vocal hygiene and speech therapy cannot be overstated and should be emphasized at the initial consultation and incorporated in the treatment plan.

REFERENCES

1. Bastian RW. Benign vocal fold mucosal disorders. In: Cummings otolaryngology head and neck surgery. 4th ed. Vol. 3. Philadelphia (PA): Mosby; 2005. p. 2150.
2. Boersma P. PRAAT, a system for doing phonetics by computer. *Glott Int* 2001 Nov-Dec;5(9/10):341-345.
3. Boersma P, Weenink D. PRAAT: doing phonetics by computer [Computer program]. Version 5.3.68 [retrieved 2014 Mar 20]. Available from: <http://www.praat.org/>.
4. Bergamini G, Casolino D, Schindler O. Inquadramento delle disfonie. In: Casolino D, editor. *Le disfonie: fisiopatologia clinica ed aspetti medico-legali*. Pisa: Pacini Editore; 2002. p. 97-116.
5. Morrison MD, Rammage LA. Muscle misuse voice disorders: Description and classification. *Acta Otolaryngol* 1993 May;113(3): 428-432.
6. Holmberg EB, Hillman RE, Hammarberg B, Södersten M, Doyle P. Efficacy of a behaviourally based voice therapy protocol for vocal nodules. *J Voice* 2001 Sep;15(3):395-412.
7. Bastian RW. Benign vocal fold mucosal disorders. In: Flint PW, Haughey BH, Lund VJ, Niparko JK, Richardson MA, Robbins KT, Thomas JR, editors *Cummings Otolaryngology: Head and neck surgery*. 5th ed. Vol. 1. Philadelphia, PA: Mosby/Elsevier; 2010. p. 859-882.
8. Dejonckere PH, Bradley P, Clemente P, Cornut G, Crevier-Buchman L, Friedrich G, Van De Heyning P, Remacle M, Woisard V. Committee on Phoniatrics of the European Laryngological Society (ELS). A basic protocol for functional assessment of voice pathology, especially for investigating the efficacy of (phonosurgical) treatments and evaluating new assessment techniques. Guideline elaborated by the Committee on Phoniatrics of the European Laryngological Society (ELS). *Eur Arch Otorhinolaryngol* 2001 Feb;258(2): 77-82.
9. Rosen CA, Murry T, Zinn A, Zullo T, Sonbolian M. Voice handicap index change following treatment of voice disorders. *J Voice* 2000 Dec;14(4):619-623.
10. Thomas G, Mathews SS, Chrysolyte SB, Rupa V. Outcome analysis of benign vocal cord lesions by videostroboscopy, acoustic analysis and voice handicap index. *Indian J Otolaryngol Head Neck Surg* 2007 Dec;59(4):336-340.

11. Ragab SM, Elsheitk MN, Saafan ME, Elsherief SG. Radiophonosurgery of benign superficial vocal fold lesions. *J Laryngol Otol* 2005 Dec;119(12):961-966.
12. Uloza V, Saferis V, Uloziene I. Perceptual and acoustic assessment of voice pathology and the efficacy of endolaryngeal phonomicrosurgery. *J Voice* 2005 Mar;19(1):138-145.
13. Saenz-Lechon N, Godino-Llorente JI, Osmá-Ruiz V, Blanco-Velasco M, Cruz-Roldán F. Automatic assessment of voice quality according to the GRBAS scale. *Conf Proc IEEE Eng Med Biol Soc* 2006;1:2478-2481.
14. Kempster GB, Gerratt BR, Abbott KV, Barkmeier-Kraemer J, Hillman RE. Consensus auditory-perceptual evaluation of voice: Development of a standardized clinical protocol. *Am J Speech Lang Pathol* 2009 May;18(2):124-132.
15. Phaniendra Kumar V, Srinivasa Murthy M, Ravikanth S, Kumar R. Phonomicrosurgery for benign vocal fold lesions – our experience. *Indian J Otolaryngol Head Neck Surg* 2003 Jul;55(3):184-186.
16. Key Elemetrics Corporation. MDVF manual version 2.7.0. Lincoln Park (NJ): Kay Elemetrics; 1993.
17. Wolfe V, Martin D. Acoustic correlates of dysphonia: Type and severity. *J Commun Disorder* 1997 Sep-Oct;30(5):403-415.
18. Jones TM, Trabold M, Plante F, Cheetham BM, Earis JE. Objective assessment of hoarseness by measuring jitter. *Clin Otolaryngol Allied Sci* 2001 Feb;26(1):29-32.
19. Colton RH, Casper JK. Understanding voice problems: a physiological perspective for diagnosis and treatment. 2nd ed. Baltimore (MD): Lippincott Williams & Wilkins; 1996.
20. Yumoto E, Gould WJ, Baer T. Harmonics-to-noise ratio as an index of the degree of hoarseness. *J Acoust Soc Am* 1982 Jun;71(6):1544-1549.
21. Eckel F, Boone DR. The s/z ratio as an indicator of laryngeal pathology. *J Speech Hear Disord* 1981 May;46(2):147-149.
22. Toran KC, Vaidhya BK. Objective voice analysis for vocal polyps following microlaryngeal phonosurgery. *Kathmandu Univ Med J (KUMJ)* 2010 Apr-Jun;8(30):185-189.
23. Stajner-Katusić S, Horga D, Zrinski KV. A longitudinal study of voice before and after phonosurgery for removal of a polyp. *Clin Linguist Phon* 2008 Oct-Nov;22(10-11):857-863.
24. Petrović-Lazić M, Babac S, Vuković M, Kosanović R, Ivanković Z. Acoustic voice analysis of patients with vocal fold polyp. *J Voice* 2011 Jan;25(1):94-97.
25. Wang JH, Park SK, Lee SK, Choi SH, Kim SY, Nam SY. Comparison of the results of voice handicap index and computer-assisted voice analysis in patients with benign vocal cord lesions before and after microlaryngeal surgery. *Korean J Otolaryngol Head Neck Surg* 2005 Mar;48(3):380-386.
26. Shi ZP, Wang HW. Objective analysis of voice after microlaryngoscopic surgery in patients with vocal Polyps at different anatomical sites. *J Med Sci* 2007;27(6):265-270.
27. Valadez V, Ysunza A, Ocharan-Hernandez E, Garrido-Bustamante N, Sanchez-Valerio A, Pamplona MC. Voice parameters and videonasalaryngoscopy in children with vocal nodules: A longitudinal study, before and after voice therapy. *Int J Pediatr Otorhinolaryngol* 2012 Sep;76(9):1361-1365.
28. Tezcaner CZ, Karatayli Ozgursoy S, Sati I, Dursun G. Changes after voice therapy in objective and subjective voice measurements of pediatric patients with vocal nodules. *Eur Arch Otorhinolaryngol* 2009 Dec;266(12):1923-1927.
29. Treole K, Trudeau MD. Changes in sustained production tasks among women with bilateral vocal nodules before and after voice therapy. *J Voice* 1997 Dec;11(4):462-469.