10.5005/jp-journals-10017-1071

CLINICAL STUDY

The Importance of the Palmar Lunate Facet in the Treatment of Distal Radius Fractures

[1]Marc J Richard MD, [2]Alexander J Lampley MD, [3]Priyesh D Patel MD, [4]Riikka EK Nomides MD
[5]Suhail K Mithani MD, [6]Fraser J Leversedge MD, [7]David S Ruch MD

ABSTRACT

Background: While there have been multiple studies published that have stressed the importance of restoring various different radiographic parameters to improve functional outcome scores, there is no consensus on the parameter that correlates most with patients' functional outcomes. We hypothesize that obtaining near anatomical reduction of the palmar lunate facet is critical to improving functional outcome scores. The purpose of this study is to determine the effects of reduction and stabilization of the palmar lunate facet on functional outcomes in patients with intra-articular distal radius fracture.

Materials and methods: We prospectively collected clinical examination data, radiographic measurements, and functional outcome scores on 157 patients who were treated operatively for multifragmentary intra-articular fractures of the distal radius (AO Type C3) between 1996 and 2006. Prospective data were acquired at 3, 6 months, and 1 year postsurgical intervention in clinical follow-up. Based on radiographic measurements, patients were designated into a nondisplaced palmar lunate facet group and a displaced palmar lunate facet group. Clinical and functional outcomes were then compared between the groups.

Results: Patients without displacement had a significantly higher value of wrist extension and forearm supination when compared with the patients with displacement. In addition, the Gartland and Werley score was significantly higher in patients with displacement of the palmar lunate facet.

Conclusion: This study demonstrates that patients with near anatomical reduction of the palmar lunate facet after surgical treatment of an intra-articular distal radius fracture had improved range of motion and better functional outcome scores compared with patients with residual displacement of the palmar lunate facet.

Keywords: Distal radius fracture, Lunate facet, Outcomes.

Richard MJ, Lampley AJ, Patel PD, Nomides REK, Mithani SK, Leversedge FJ, Ruch DS. The Importance of the Palmar Lunate Facet in the Treatment of Distal Radius Fractures. The Duke Orthop J 2016;6(1):56-60.

[1,3,5,6]Associate Professor, [2]Resident Physician, [4]Medical Student, [7]Professor

[1,2,4-7]Department of Orthopaedic Surgery, Duke University Medical Center, Durham, North Carolina, USA

[3]Department of Orthopaedic Surgery, Centegra Physician Care Crystal Lake, Illinois, USA

Corresponding Author: Alexander Lampley, Resident Physician, Department of Orthopaedic Surgery, Duke University Medical Center, Box 3000, Durham, North Carolina-22710 USA, Phone: +7324855355, e-mail: alexander.lampley@duke.edu

Source of support: Nil

Conflict of interest: None

INTRODUCTION

The management of distal radius fractures has evolved significantly in the past 20 years. The ultimate goal of treatment for distal radius fractures is to restore pain-free motion and provide stability to allow patients to return to their occupational and recreational activities, while minimizing degenerative changes. Though that goal is universally accepted, there is disagreement as to which radiographic parameters are the most critical in achieving that goal.

There have been numerous studies published that have emphasized the importance of restoring various radiographic parameters to improve functional outcome. Initially, multiple authors emphasized the importance of restoring palmar tilt to improve functional outcome.[1,2] Subsequently, there were reports that indicated a strong correlation between radial length and loss of strength.[3] Other authors demonstrated a correlation between decreased radial inclination and decreased grip strength.[4] In addition, long-term follow-up indicated that loss of radial inclination increases the risk of degenerative changes by 90%.[5] More recent studies have demonstrated that the presence of carpal malalignment after distal radius fractures correlates with poorer grip strength and rotation, and that the degree of carpal malalignment at 1 year after fracture was the most significant indicator of poor result.[6-8] Finally, studies have reported that the presence of radiocarpal articular congruity is the most clinically significant radiographic parameter in younger patients with regard to both functional outcome and future degenerative changes.[9,10]

Reviewing these aforementioned studies, there is no agreement as to the most important radiographic parameter on functional outcome. However, the palmar lunate facet appears to be the common denominator in these parameters. Residual depression of the lunate facet fragment correlates with incongruity of the radiocarpal and radioulnar joints, resulting in loss of motion and arthrosis. Up to this point, there has not been a study that evaluates the importance of the palmar lunate facet fragment, the "critical corner," on functional outcome.

The intermediate column consists of the lunate fossa and the sigmoid notch of the radius. The intermediate column may be considered the cornerstone of the radius because it is critical for articular congruity and distal radioulnar function. The purpose of this study was to determine the effects of reduction and stabilization of the "critical corner" on functional outcomes in patients with intra-articular distal radius fracture.

MATERIALS AND METHODS

The nature of the study and its design was explained to all patients that were treated operatively for multifragmentary intra-articular fractures of the distal radius (AO Type C3). Institutional Review Board approval was obtained from our institution prior to enrolling patients in the study. The authors prospectively acquired data on 185 patients from 1996 to 2006. The inclusion criteria included closed multifragmentary distal radius fracture in a skeletally mature individual age 18 to 60 years. The exclusion criteria consisted of open fractures, associated median nerve injuries, or ipsilateral upper extremity trauma. The patients were treated with either external fixation supplemented with allograft and wires or internal fixation using either a dorsal plate or a fixed angle volar plate. Implant selection was based on surgeon preference and experience and included hybrid fixation using nonlocking palmar plates neutralized with an external fixator. Multiple plates were used with no specific preponderance of implant choice.

Prospective data were acquired at 3, 6 months, and 1 year postsurgical intervention in clinical follow-up. Patients underwent radiographic evaluation, physical examination including range of motion, grip strength (Jamar level 2), Gartland and Werley scores,[1] and the Disabilities of the arm, shoulder and hand (DASH) outcome score.[11] A standard goniometer was used to measure flexion, extension, pronation, and supination at each visit. A total of 28 patients failed to achieve minimum 1 year follow-up resulting in a study group of 157 patients.

The study group consisted of 88 males and 69 females with a mean age of 45.5 years for the males and 53.6 years for the females. In 87 patients, the distal radius was the result of a fall from a height, while 59 fractures were secondary to a motor vehicle collision, and 11 injuries by other mechanisms. The injury occurred in the dominant extremity in 85 patients and the nondominant extremity in 72.

A total of 53 patients were treated by external fixation with supplemental pinning, 32 patients were treated with a dorsal nonlocking plate, 46 patients were treated with a volar plate, and 26 patients with a combination of dorsal and volar plate. The majority of the patients in the external fixator group were enrolled in the earlier stages of the study, whereas patients treated with fixed angle plates were prospectively enrolled after 2001.

Radiographic Evaluation

Each clinical follow-up included standard postero-anterior (PA), lateral, and inclined lateral radiographs. The radiographs were evaluated for the teardrop angle, volar tilt, radiolunate angle (RLA), carpal translation, articular step-off, and articular gap. The palmar lunate facet was determined to be displaced if (1) the PA radiograph demonstrated >2 mm of depression of the lunate facet relative to the radial styloid fragment, and relative to a line parallel to the head of the ulna combined with (2) evidence of depression of the volar lip of the distal radius on the inclined lateral view. If the radiographic parameters described above were not met, then the lunate facet was considered to be nondisplaced.

Based on the radiographic parameters, two groups were designated, with group I being patients with significant residual articular depression of the palmar lunate facet (>2 mm) and group II (nondisplaced) consisting of patients with less than 2 mm of articular depression. Group I consisted of 41 patients who were felt to have 2 mm or greater depression of the palmar lunate facet at final radiographs at 1 year follow-up. Of the 41 patients in this group, 17 patients had been treated with an external fixator, 17 patients were treated with a dorsal plate, and 7 were treated with a volar plate. Group II consisted of 116 patients with less than 2 mm of displacement of the palmar lunate facet relative to the remainder of the articular surface of the distal radius. Of the 116 patients in group II, 34 patients had been treated with an external fixator; 36 were treated with a dorsal plate; 46 were treated with a volar plate.

Patient radiographs were assessed for the following:
Teardrop angle: On the lateral view, the teardrop is identified easily and represents the volar rim of the lunate facet. This radiographic landmark is even more prominent on the inclined lateral view. Normally a line drawn down the central axis of the teardrop (parallel to the subchondral bone of the volar rim) creates an angle of 70° to a line extended from the central axis of the radial shaft (Fig. 1).
Volar tilt: Volar tilt is measured on the lateral view as the angle formed between a perpendicular to the longitudinal axis of the radial shaft and a line formed by connecting the apex of the volar and dorsal rim. In practice, the apices of the dorsal and volar rim are identified more clearly on the inclined lateral view (Fig. 1).

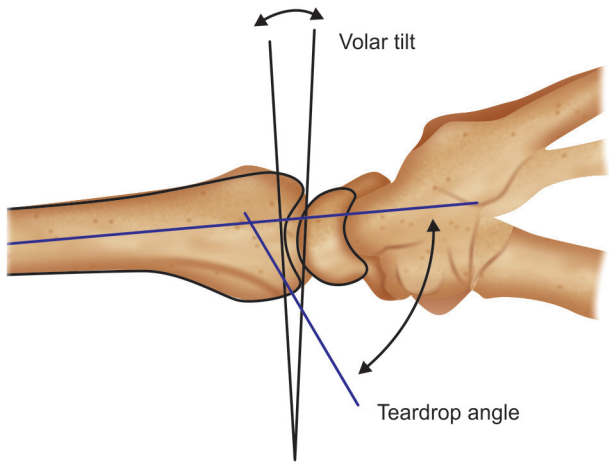

Fig. 1: Teardrop angle and volar tilt measurements

Radiolunate angle: The RLA is defined as the angle between the axis of the lunate and the axis of the radius in a neutral position. The axis of the lunate was determined by a line perpendicular to a line connecting the volar tip and dorsal tip of the capitate facet of the lunate in a lateral view. The axis of the radius was found by determining a line joining two midpoints of the radius shaft (Fig. 2).

Carpal translation: The distance between the point where the axis of the lunate meets the line connecting the volar tip and dorsal tip of the capitate facet of the lunate (ii) and the point where the axis of the radius meets the same line. Palmar translation was noticed as plus (+) and dorsal as minus (–).

Articular step-off: Represents a translational discontinuity or ledge in the articular surface. This abnormality usually is identified on the PA view, but may also be noted on the standard inclined lateral view.[12]

Articular gap: Articular separation is a second parameter that is useful to identify gaps in the articular surface caused by incomplete apposition of the articular elements.[12]

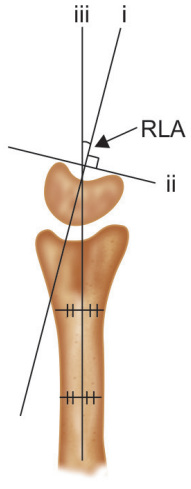

Fig. 2: Radiolunate angle measurement

Statistical Analysis

Means and descriptive statistics were computed for the continuous outcome variables of extension, flexion, pronation, supination, DASH, visual analog score, and Gartland and Werley score. In addition, means and descriptive statistics were computed for the predictor variables that included articular step-off on inclined lateral view, gap on inclined lateral view, carpal translation, teardrop angle, and age. Patients were divided into two groups, and means and descriptive statistics of the preceding variables were computed; group I were those patients with >2 mm residual displacement of the palmar lunate facet and group II were those patients with <2 mm residual displacement of the palmar lunate facet.

The relationship between the continuous outcome variables and treatment type was analyzed by box plots and the Wilcoxon rank sum test. Treatment type was categorized by closed reduction and cast, external fixation, open reduction and internal fixation (ORIF) with volar plate, ORIF with bridge plate.

RESULTS

The results of comparing patients with residual displacement (group I) and without displacement (group II) are shown in Table 1. Patients without displacement had a significantly higher median (65) value of extension than those with residual displacement (median = 45) ($p = 0.002$). Median supination for those without displacement (78) was significantly higher than median supination for those with displacement (67) ($p = 0.004$). In addition, Gartland and Werley scores for those with displacement were significantly higher (mean = 3.31, median = 2) ($p = 0.036$) than for those without displacement, mean (1.85) and median (0). Median carpal translation for those with displacement was significantly higher (17.15) than for those without displacement (4.5) ($p = 0.023$).

Type of Treatment

Patients treated with external fixation were more likely to have residual palmar displacement of the palmar lunate facet than those treated with internal fixation ($p < 0.05$).

DISCUSSION

The influence of radiographic parameters on patient-reported outcomes following fractures of the distal radius remain controversial. Knirk and Jupiter[9] are credited with recognizing the significance of a 2 mm step off in the articular surface following lunate impaction fractures.

Table 1: Comparison of patients with and without displacement of the lunate facet

Variable	*Statistic*	*No displacement*	*With displacement*	*p-value**
Flexion	Mean (SD)	65.17 (22.31)	55.8 (28.33)	
	Min/median/max	0, 67.5, 90	0, 60, 90	0.126
Extension	Mean (SD)	62.32 (19.58)	48.63 (23.07)	
	Min/median/max	10, 65, 90	0, 50, 90	0.002
Pronation	Mean (SD)	84.4 (13.87)	82.03 (18.86)	
	Min/median/max	20, 90, 90	10, 90, 90	0.884
Supination	Mean (SD)	78.18 (17.48)	68.85 (20.86)	
	Min/median/max	10, 85, 90	20, 80, 90	0.004
Gartland and Werley scores	Mean (SD)	1.85 (2.62)	3.31 (3.56)	
	Min/median/max	0, 0, 12	0, 2, 10	0.036
Palmar lunate facet lateral view	Mean (SD)	0.38 (0.65)	0.71 (0.97)	
	Min/median/max	0, 0, 2.5	0, 0, 2.7	0.234
Palmar lunate facet gap lateral	Mean (SD)	0.24 (0.5)	1.1 (1.88)	
	Min/median/max	0, 0, 2.2	0, 0, 5.4	0.115
Carpal translation	Mean (SD)	5.3 (23.37)	18.18 (27.64)	
	Min/median/max	–77.7, 4.5, 77.7	–48.4, 17.15, 72	0.023
Teardrop angle	Mean (SD)	55.88 (7.81)	60.09 (12.69)	
	Min/median/max	40, 57, 75	37, 61, 87	0.086

*p-value based on Wilcoxon rank sum test of difference in medians between groups; SD: standard deviation

Their conclusion that depression of the articular surface resulted in radiographic evidence of arthrosis in as little as 7 years following surgery focused attention on articular congruity as a predictor of outcome. Subsequent authors focused on the presence of as little as 1 mm of articular step off as predictive of poor functional outcome following these injuries.[10,13,14] Critical evaluation of these papers indicates that the authors are referring to residual depression of the lunate facet of the radius as being the cause of subsequent arthrosis. While these papers clearly demonstrate the significance of anatomic reduction of intra-articular fractures, there is growing evidence that the effect on patient's perception of outcome may diminish over time. Long-term outcome studies on the effect of residual articular incongruity on patient-reported outcome scores indicate that the significance of anatomic reduction may lessen over time. For example, Goldfarb et al[12] demonstrated that patients with a malunion after operatively stabilized distal radius fractures showed radiographic evidence of arthrosis; however, this finding of joint arthrosis did not directly correlate to patient dissatisfaction. Furthermore, Chung et al[15] corroborated these results and indicated that anatomic reduction of the articular surface enhanced short-term functional outcomes at 3 months postinjury, but only age and income were significantly associated with long-term functional outcomes.

Reduction of the palmar lunate facet has implications on functional outcomes both at the radiocarpal joint and at the distal radioulnar joint, and thus clearly impacts functional outcome as noted in the Gartland and Werley score at 1 year. Therefore, in order to improve functional outcome, the reduction of the lunate facet is critical and can be assessed at the time of surgical fixation by analyzing and determining the teardrop angle. If the teardrop angle is not restored, then the adequacy of surgical reduction of the critical palmar lunate facet, the "critical corner," must be questioned. This study demonstrates that those patients who underwent ORIF with critical attention to the reduction of the palmar lunate facet did significantly better in terms of range of motion and functional outcome when compared with those patients that underwent external fixation and did not have adequate restoration of the teardrop angle. Patients with residual depression of the palmar lunate facet will have loss of forearm rotation and wrist passive extension.

The strength of this study is the large cohort of patients identified and followed for functional outcomes with displaced lunate facet fractures. The weakness of this study is that the effect of the articular incongruity on the development of arthrosis, while having been previously documented in other studies, would not be evident during the follow-up time period of this study. Furthermore, this study includes a group of patients with multiple different surgical interventions in terms of volar and/or dorsal plating.

The loss of radial length relative to the ulna has been associated with an increasingly poor outcome in both intra-articular and extra-articular fractures.[16,17] The resultant incongruity of the distal radioulnar joint results in painful impaction and loss of rotation. Harness et al[18] emphasized the significance of the palmar component of the lunate facet by presenting a cohort of patients in whom the palmar lunate facet of the radius was not stabilized following palmar plate application. In this

deformity, the carpus appeared to follow the unreduced palmar facet with a severe functional loss of supination.

The results of this qualitative assessment of outcomes following operative management of the distal radius provide clear documentation regarding the significance of what has become known as the "critical corner" of the distal radius. While there have been suggestions on the importance of this unique anatomic feature of the distal radius in the literature, there have not been published results which clearly indicate the significance of the palmar lunate facet in clinical outcomes. This study demonstrates that patients who had open reduction of the displaced palmar lunate facet as opposed to external fixation had improved range of motion in terms of flexion, extension, pronation, and supination, and ultimately better functional outcomes as indicated by better Gartland and Werley scores.

REFERENCES

1. Gartland JJ Jr, Werley CW. Evaluation of healed Colles' fractures. J Bone Joint Surg Am 1951 Oct;33-A(4):895-907.
2. Porter M, Stockley I. Fractures of the distal radius. Intermediate and end results in relation to radiologic parameters. Clin Orthop Relat Res 1987 Jul;(220):241-252.
3. McQueen M, Caspers J. Colles fracture: does the anatomical result affect the final function? J Bone Joint Surg Br 1988 Aug;70(4):649-651.
4. Jenkins NH, Mintowt-Czyz WJ. Malunion and dysfunction in Colles' fracture. J Hand Surg Br 1988 Aug;13(3):291-293.
5. Kopylov P, Johnell O, Redlund-Johnell I, Bengner U. Fractures of the distal end of the radius in young adults: a 30-year follow-up. J Hand Surg Br 1993 Feb;18(1):45-49.
6. McQueen MM, Hajducka C, Court-Brown CM. Redisplaced unstable fractures of the distal radius: a prospective randomised comparison of four methods of treatment. J Bone Joint Surg Br 1996 May;78(3):404-409.
7. Batra S, Gupta A. The effect of fracture-related factors on the functional outcome at 1 year in distal radius fractures. Injury 2002 Jul;33(6):499-502.
8. Bickerstaff DR, Bell MJ. Carpal malalignment in Colles' fractures. J Hand Surg Br 1989 May;14(2):155-160.
9. Knirk JL, Jupiter JB. Intra-articular fractures of the distal end of the radius in young adults. J Bone Joint Surg Am 1986 Jun;68(5):647-659.
10. Trumble TE, Schmitt SR, Vedder NB. Factors affecting functional outcome of displaced intra-articular distal radius fractures. J Hand Surg Am 1994 Mar;19(2):325-340.
11. Hudak PL, Amadio PC, Bombardier C. Development of an upper extremity outcome measure: the DASH (disabilities of the arm, shoulder and hand) [corrected]. The Upper Extremity Collaborative Group (UECG). Am J Ind Med 1996 Jun;29(6):602-608.
12. Goldfarb CA, Rudzki JR, Catalano LW, Hughes M, Borrelli J Jr. Fifteen-year outcome of displaced intra-articular fractures of the distal radius. J Hand Surg Am 2006 Apr;31(4): 633-639.
13. Fernandez DL. Should anatomic reduction be pursued in distal radial fractures? J Hand Surg Br 2000 Dec;25(6): 523-527.
14. Geissler WB, Fernandes D. Percutaneous and limited open reduction of intra-articular distal radial fractures. Hand Surg 2000 Dec;5(2):85-92.
15. Chung KC, Kotsis SV, Kim HM. Predictors of functional outcomes after surgical treatment of distal radius fractures. J Hand Surg Am 2007 Jan;32(1):76-83.
16. Dario P, Matteo G, Carolina C, Marco G, Cristina D, Daniele F, Andrea F. Is it really necessary to restore radial anatomic parameters after distal radius fractures? Injury 2014 Dec;45 Suppl 6:S21-S26.
17. Hollevoet N, Verdonk R. The functional importance of malunion in distal radius fractures. Acta Orthop Belg 2003 Jun;69(3):239-245.
18. Harness NG, Jupiter JB, Orbay JL, Raskin KB, Fernandez DL. Loss of fixation of the volar lunate facet fragment in fractures of the distal part of the radius. J Bone Joint Surg Am 2004 Sep;86-A(9):1900-1908.