

# Microscopic Lumbar Discectomy vs Endoscopic Discectomy

S Balaji Pai

**How to cite this article:** Pai SB. Microscopic Lumbar Discectomy vs Endoscopic Discectomy. *J Spinal Surg* 2016;3(1):5-7.

**Source of support:** Nil

**Conflict of interest:** None

## INTRODUCTION

Lumbar discectomy is a routinely performed surgery by neurosurgeons, orthopedic surgeons and lately by the spinal surgeons. The focus in this procedure has shifted over the decades to more minimally invasive techniques. Among these, microscopic lumbar discectomy (MLD) is one of the earliest developments and having withstood the test of time, is considered the standard against which other minimally invasive techniques are compared. Endoscopic discectomy (ED) is comparatively a new kid in the block. It is but natural that ED has been compared with MLD. The author has compared these two surgical procedures and their utility and results and also mentioned their personal preference.

## HISTORY

Between the 1930s and 1950s, both orthopedic and neurological surgeons followed the traditional surgical teaching of Mixter and Barr consisting of wide bilateral muscular dissection and exposure, wide laminectomy, extensive epidural hemostasis and coagulation in the course of discectomy. It was Yasargil who revolutionized neurosurgery with the introduction of the operating microscope and was aptly called the "father of microneurosurgery". Neurosurgeons world over embraced the operating microscope in all fields-lumbar discectomy being no exception. Microscopic lumbar discectomy was first performed by Yasargil in 1968 and was pioneered by Caspar and Iwa and Williams from 1977 to 1979. Goald,

Ebling et al, Wilson and Harbaugh, Maroon and Abla and many others have published their results with MLD. The Williams retractor was an interesting introduction which helped the paraspinal muscle dissection on one side only, decreasing muscle trauma and postoperative pain. Microscopic lumbar discectomy has now been accepted as the standard with which all other procedures are compared.

In 1931, Burman introduced the concept of myelotomy for direct spinal canal visualization. Mixter and Barr demonstrated intraoperative diskotomy after open hemilaminectomy. In 1938, Pool introduced the concept of intrathecal endoscopy and published his results on 400 myeloscopic procedures. Using improved technology, Ooi et al used an endoscope to examine the intrathecal space before surgery. Introduction of video assisted endoscopic surgery in 1970s and 1980s gave birth to and firmly established laparoscopic general surgery as a speciality. In 1983, Kambin and Gellman used the modified arthroscopic approach to lumbar discectomy. Schreiber and Suizana in 1986 used a biportal approach (working instruments on one side and endoscope on the other). microendoscopic discectomy (MED) was first described by Smith and Foley in 1998. Khoo and Fessler described the microendoscopic decompressive laminotomy (MEDL). The applications of endoscopy in spinal surgery have widened to include lumbar canal decompression, lumbar fusion both anterior and posterior and thoracoscopic decompression and fusion procedures.

## SURGICAL PROCEDURE

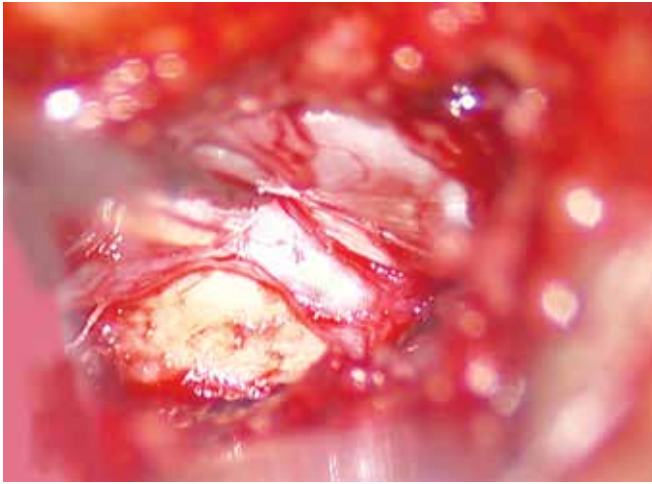
### Microscopic Lumbar Discectomy

The procedure is carried out under general or spinal anesthesia. In the prone or lateral position, an incision 15 to 25 mm is made in the midline or just lateral to the spinous process. The paraspinal muscles are separated and retracted using the William's retractor. After confirming the level; the operating microscope is brought into the field. If the interlaminar space is large, no bone removal is required. If, however, this space is narrow then lower border of the superior lamina is nibbled or drilled. This is followed by excision of the ligamentum flavum thus, creating a window. The dura and the nerve root are identified and retracted. The disk bulge or the sequest-

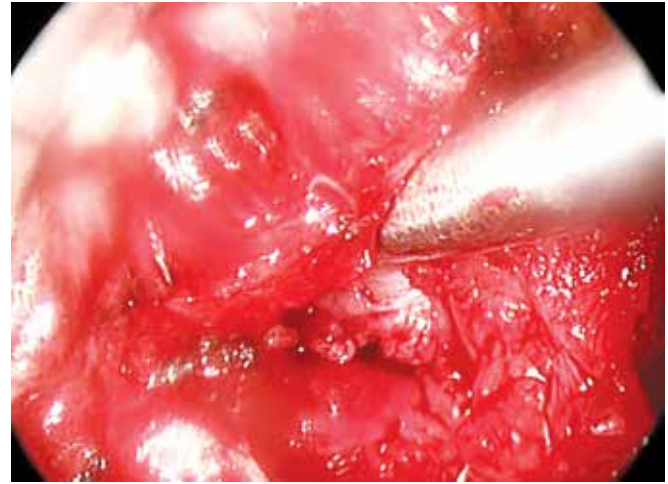
Professor and Head

Department of Neurosurgery, Bangalore Medical College and Research Institute, Bengaluru, Karnataka, India

**Corresponding Author:** S Balaji Pai, Professor and Head Department of Neurosurgery, 737, 14th Cross, Girinagar II Phase, Bengaluru-560085, Karnataka, India, Phone: 919341250084, e-mail: balajipai65@yahoo.co.in



**Fig. 1:** Microscopic lumbar discectomy



**Fig. 2:** Endoscopic lumbar discectomy (ELD)

rated disk is now identified. The sequestered portion is now removed followed by incision of the annulus and removal of the degenerated portions of the disk. After adequate decompression of the nerve root, hemostasis is achieved followed by closure (Fig. 1).

### Endoscopic Lumbar Discectomy

This is done under general or spinal anesthesia with the patient in prone position. A 15 mm paramedian incision is made lateral to the midline. A guide wire is placed toward the inferior border of the superior lamina and medial to the facet joint under fluoroscopic guidance. With repeated dilatation with increasing size of dilators a tract is created and the working channel is placed over the final dilator as in the Metrix system. The author, however, has used the Destendau system which lacks the dilators but instead has an obturator which is oblong and once the trocar is removed, the soft tissue over the interlaminar space is removed. The endoscope is then introduced. The lower border of the superior lamina is nibbled with a Kerrison's punch. The ligamentum flavum is then excised. After identifying the nerve root, it is retracted using a nerve root retractor. Discectomy is then carried out in the usual way and the nerve root decompressed. Hemostasis is achieved using the endoscopic bipolar forceps and surgical (Fig. 2).

### RESULTS

The results of MLD and ELD/MED are matched with no statistically significant differences between the two groups in various studies. The various parameters considered were visual analog scale, Oswestry disability index and short Form-36. However, short-term benefits like decreased blood loss, lesser postoperative pain and paraspinal musculature injury has been reported.

The complications of MLD and ELD or MED are similar and their incidences are comparable. These include

dural tears, nerve root injury, diskitis and long-term spinal instability.

### DISCUSSION

Various surgical approaches have been advocated for the surgical management of disk prolapse. These vary from the more orthodox open wide laminectomy and discectomy, fenestration discectomy and MLD. The latter is now considered as the standard against which other newer procedures are compared. Endoscopic lumbar discectomy and MED are the newer kids in the block. These have proven to have similar and comparable results. However, these procedures also have a steep learning curve.

The main advantage of the MLD is its ability to provide depth of vision in addition to illumination and magnification. Moreover, the ability to manoeuvre with both hands is a major advantage which cannot be overestimated. Another advantage is the ability to reach on both sides of the spine though the same incision. However, the advocates of the endoscopic procedures quote the muscle dissection and slightly longer incision associated with MLD as a disadvantage over the endoscopic procedures.

The endoscopic procedures require a small incision and the illumination and magnification is satisfactory. The muscle dissection too is limited. However, the lack of three-dimensional depth and the need to work looking at the video screen is a limiting factor. The endoscopic procedure is usually restricted to a unilateral pathology but some surgeons have mastered the skilful technique of reaching the opposite side through a unilateral paramedian approach. Another limitation is the clouding of the endoscopic vision by the presence of even a small quantity of blood. The introduction of the biportal/two hand technique has helped overcome some of the limitation of the earlier endoscopes. The use of drill although possible can sometimes result in inadvertent damage to the endoscope.

## Personal Remarks and Preference

When a new procedure or technology is introduced, it is usually met with cynicism and opposition. The pendulum then swings in the opposite direction with overemphasis of the procedure. The pendulum usually rests in the center over time. Endoscopic procedures have created a space for themselves especially in the hands of those trained and experienced in these procedures. The value of a new procedure can be ascertained by the ability to have consistent results in the hands of average surgeons in an average infrastructural setup. The ELD and MED is ideally suited for sequestered or large unilateral disk bulge. The MLD, however, is a procedure which has withstood the test of time. The ability to provide illumination and magnification with depth of vision and both hands unrestricted and free is definitely uncomparable by ELD/MED presently. The presence of spinal canal stenosis also has influenced most surgeons to choose the MLD over MED/ELD. It is also not misplaced here to state that the MLD is one of the first surgical procedures a neurosurgical resident learns to perform and constitutes the basic platform over which a resident sharpens his microsurgical skills. Hence, the role of MLD in neurosurgical resident training cannot be overstressed. Similarly, ELD and MED too play a role as a primary training technique for cranial endoscopy.

## CONCLUSION

The results of MLD and ELD/MED are well matched. Although the long-term results are similar, some surgeons quote the advantage of short-term benefits of ELD and MED like lesser postoperative pain and blood loss over MLD. The surgeon's preference, training, skill and institutional

infrastructure apart from patient factors plays a role in which procedure the surgeon applies in a particular patient.

## BIBLIOGRAPHY

1. Ditsworth DA. Endoscopic transforaminal lumbar discectomy and reconfiguration: a posterolateral approach into the spinal canal. *Surg Neurol* 1998;49:588-598.
2. Foley KT, Smith MM. Microendoscopic discectomy. *Tech Neurosurg* 1997;3:301-307.
3. Hlavin ML, Hardy RW Jr. Lumbar disk disease. *Neurosurgery Quarterly* 1991;29-53.
4. Jairam S, Kim DH, Kam AC. History of minimally invasive spine surgery. *Neurosurgery* 2002;51(Suppl 2):1-14.
5. Khoo LT, Fessler RG. Microendoscopic decompressive laminotomy for the treatment of lumbar stenosis. *Neurosurgery* 2002;51(Suppl 2):146-154.
6. Maroon JC. Current concepts in minimally invasive discectomy. *Neurosurgery* 2002;51(Suppl 2):137-145.
7. Mathews HH. Transforaminal endoscopic microdiscectomy. *Neurosurg Clin North Am* 1996;7:59-63.
8. Mayer HM, Brock M. Percutaneous endoscopic discectomy: surgical technique and preliminary results compared to microsurgical discectomy. *J Neurosurg* 1993;78:216-225.
9. Perez-Cruet MJ, Fessler RG, Perin NI. Review: complications of minimally invasive surgery. *Neurosurgery* 2002;51(Suppl 2):26-36.
10. Perez-Cruet MJ, Foley KT, Isaacs RE, Rice-Wyllie L, Wellington R, Smith MM, Fessler RG. Microendoscopic lumbar discectomy: technical note. *Neurosurgery* 51(Suppl 2); 2002;129-136.
11. Tredway TL, Fessler RG. Lumbar microendoscopic discectomy. In: *Arthroscopic and endoscopic spinal surgery—text and atlas*. Kambin P, editor. 2nd ed. Totowa, New Jersey: Humana Press; 2005. p. 359-376.
12. Yeung AT. Selective endoscopic discectomy: 12 years of experience. In: *Arthroscopic and endoscopic spinal surgery—text and atlas*. Kambin P, editor. 2nd ed. Totowa, New Jersey: Humana Press; 2005. p. 205-226.