

# Pemberton Sign in Diagnosis of Retrosternal Goiter

<sup>1</sup>Anand Mishra, <sup>2</sup>Arpit Agarwal, <sup>3</sup>Ravi K Singh, <sup>4</sup>Sandeep Tewari

## ABSTRACT

The Pemberton maneuver (elevating both arms until they touch the sides of the head for a minute) is a method to increase pressure in the thoracic inlet and further narrow the aperture.<sup>1</sup> If congestion, cyanosis of face or distension of neck veins or distress become apparent, it is suggestive of retrosternal goiter. We describe two patients with Pemberton sign.

**Keywords:** Goiter, Intrathoracic, Thyroidectomy, Thyroid surgery.

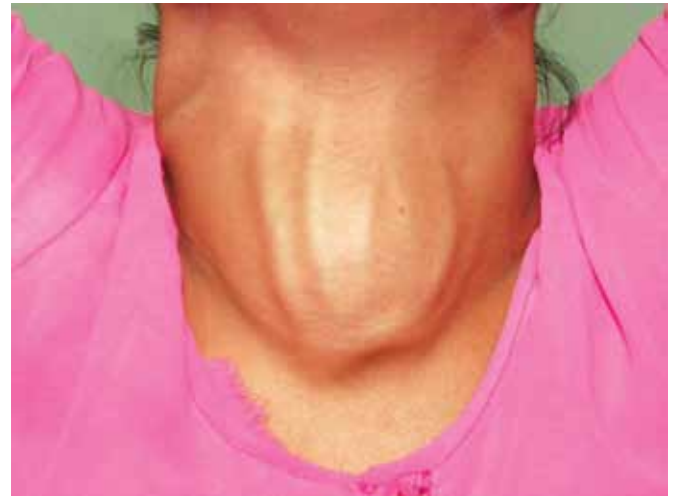**How to cite this article:** Mishra A, Agarwal A, Singh RK, Tewari S. Pemberton Sign in Diagnosis of Retrosternal Goiter. *World J Endoc Surg* 2015;7(3):79-80.

**Source of support:** Nil

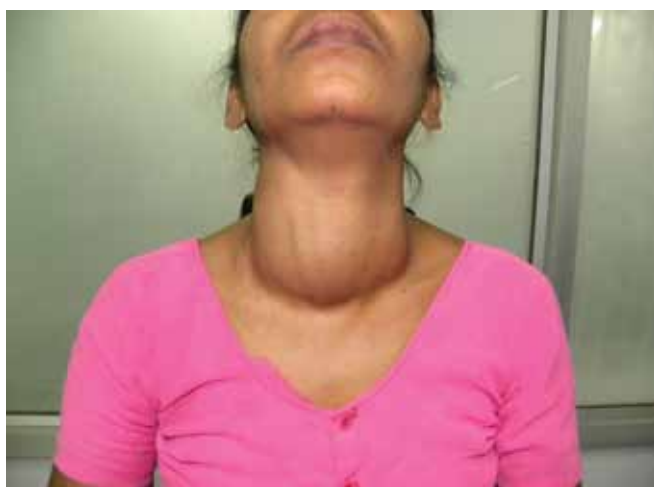**Conflict of interest:** None

## CASES

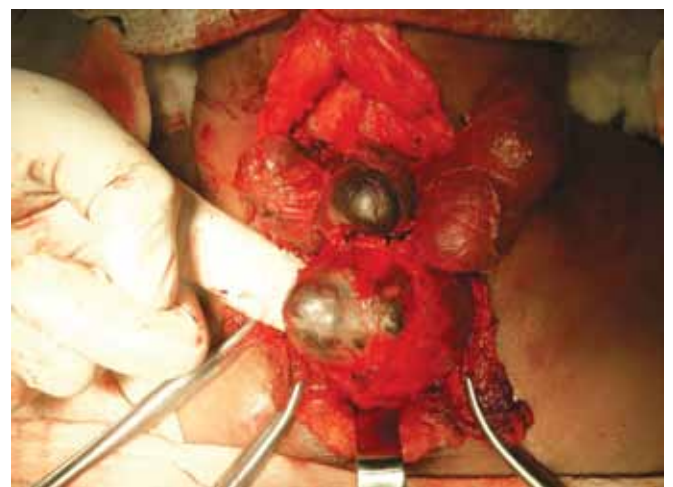
Two patients aged 36, 40-year-old female had neck mass for 5, 9 years respectively. Both had symptoms of compressive symptoms. On examination, there was multinodular goiter but lower margin was not palpable (Fig. 1). On Pemberton maneuver, there was dilatation of several neck veins and distress (Fig. 2). They were biochemically



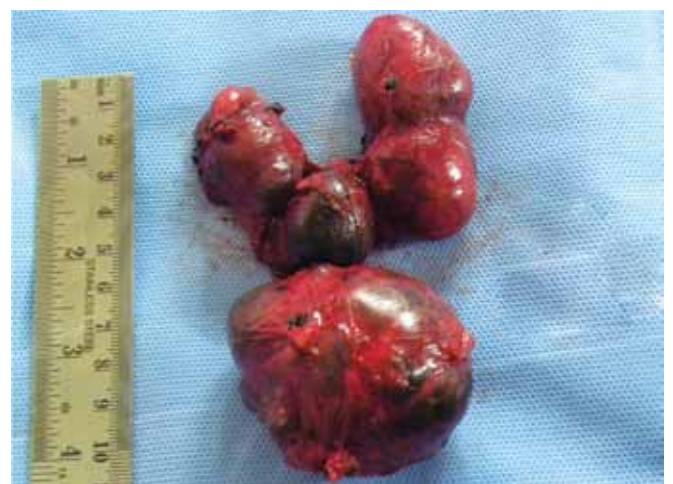**Fig. 2:** After arm raising significant dilatation of neck veins (Positive Pemberton's Sign)



**Fig. 1:** Large multinodular goiter with retrosternal extension



**Fig. 3:** Delivery of retrosternal portion by cervical route



**Fig. 4:** Specimen

<sup>1</sup>Associate Professor, <sup>2</sup>Student (3rd Year)

<sup>3</sup>Senior Resident, <sup>4</sup>Professor

<sup>1-4</sup>Department of Surgery, King George's Medical University Lucknow, Uttar Pradesh, India

**Corresponding Author:** Anand Mishra, Associate Professor Department of Surgery, King George's Medical University Lucknow, Uttar Pradesh, India, Phone: 919415007391, e-mail: mishra101@gmail.com

euthyroid and cytology was suggestive of colloid goiter. Computed tomography showed multinodular goiter with retrosternal extension. Symptoms and signs disappeared after thyroid surgery. Figure 3 is an intraoperative picture showing delivery of the retrosternal portion by cervical route. Surgeon's index finger sweeps around the intrathoracic extension of the gland and all palpable adhesions are divided gently and the retrosternal portion is delivered out in the wound. Figure 4 shows the specimen.

Dr Hugh Pemberton reported the sign as a letter to 'The Lancet' in 1946 in goiters.<sup>2</sup>

## REFERENCES

1. De Filippis EA, Sabet A, Sun MR, Garber JR. Pemberton's sign: explained nearly 70 years later. *J Clin Endocrinol Metab* 2014;99(6):1949-1954.
2. Pemberton HS. Sign of submerged goitre. *Lancet* 1946; 248(6423):509.