

Primary Adrenal Diffuse Large B-cell Lymphoma: A Mini Review

¹Rajeev Parameswaran, ²Dedrick Kok Hang Chan, ³Poon Li Mei Michelle, ⁴Shi Wang

ABSTRACT

Background: Primary adrenal diffuse large B-cell lymphoma are aggressive high grade lymphomas affecting elderly gentlemen and mostly present with bilateral enlarged adrenal masses associated with B symptoms, adrenal insufficiency and elevated lactate dehydrogenase. When imaged with CT or ultrasound, these lesions usually appear as heterogeneous complex large masses with low density. They appear metabolically active on PET scan. Confirmatory diagnosis is established by image guided biopsy or surgical excision. Treatment is usually with rituximab, cyclophosphamide, doxorubicin, vincristine and prednisone (R-CHOP) or CHOP like regimes. Surgery has very limited role, if any in the management of this condition. The prognosis is generally poor with only about a third of patients achieving partial or complete remission following treatment. A concise review of the literature (PubMed database; 1990–2014) on the clinical management of primary adrenal lymphoma along with a case example is discussed.

Keywords: Adrenal, Adrenal tumor, Lymphoma.

How to cite this article: Parameswaran R, Chan DKH, Michelle PLM, Wang S. Primary Adrenal Diffuse Large B-cell Lymphoma: A Mini Review. *World J Endoc Surg* 2015;7(3):65-68.

Source of support: Nil

Conflict of interest: None

INTRODUCTION

Primary adrenal tumors are most commonly adenomas or carcinomas.¹ Primary adrenal lymphomas (PALs) are rare, and represent only about 3% of primary extranodal lymphomas.² Primary adrenal lymphomas is usually

a non-Hodgkin lymphoma, with diffuse large B-cell lymphoma being the most common subtype, and seen in about 70% of patients.³⁻⁶ The characteristic clinical features also include a high incidence of bilaterality⁷⁻⁹ and a low incidence of extra-adrenal disease at diagnosis. Recognizing this rare condition is important as the treatment varies greatly between carcinoma and lymphoma, with the former managed predominantly with surgery, whilst the latter relying on chemotherapeutic regimes. Here we illustrate a case and briefly review the incidence, clinical features, investigations and management of this condition. Articles published in English from 1990 to 2014 were identified by searching PubMed using the search terms 'primary', 'adrenal', 'lymphoma', 'treatment' and 'prognosis' and used for review.

CASE REPORT

A 58-year-old Malay gentleman without significant comorbid medical conditions presented with a 1 month history of low grade fever and backache following a recent trip to Morocco. There was no associated history of night sweats, loss of weight or appetite, and no family history of malignancy. Initial investigations for an infectious etiology in light of his recent travel history were negative. A computed tomography (CT) scan of the abdomen and pelvis was performed which showed large bilateral adrenal tumors. The left adrenal gland measures 8.0 cm in maximum dimension, while the right adrenal gland measures 4.0 cm in maximum dimension (Fig. 1). There was no other organ involvement.

Screening for functional assessment of the adrenal gland was normal for cortisol, renin aldosterone ratio (RAA) and urinary catecholamines. Positron emission tomography/computed tomography (PET/CT) to further characterize the presence of extra-adrenal disease showed no other F-18 Fluorodeoxyglucose (FDG) avid lesions apart from the adrenals (Fig. 2). With a clinical suspicion of primary adrenal lymphoma, a percutaneous CT guided biopsy of the adrenal lesion was performed.

Histological findings showed sheets of medium to large neoplastic lymphoid cells with vesicular nuclei and single to multiple nucleoli (Figs 3A and B). There

^{1,3}Assistant Professor and Consultant

²Resident, ⁴Consultant

^{1,2}Department of Endocrine Surgery, National University Hospital, Singapore

³Department of Hematology-Oncology, National University Hospital, National University Cancer Institute of Singapore National University Health System, Singapore

⁴Department of Pathology, National University Hospital National University Health System, Singapore

Corresponding Author: Rajeev Parameswaran, Assistant Professor and Consultant, Department of Endocrine Surgery, National University Hospital, Singapore, Phone: 6567724229, e-mail: rajeev_parameswaran@nuhs.edu.sg

was conspicuous mitotic activity and apoptotic activity. Immunohistochemical stains were also performed. The neoplastic lymphoid cells expressed LCA, CD20 (Fig. 3C), CD79A, BCL6, MUM1, BCL2 and CMYC and

were negative for CD10 and Cyclin D1. The Ki-67 proliferative index was up to 90% (Fig. 3D). A diagnosis of diffuse large B-cell lymphoma (nongerminal center-like) was made. The patient was treated with R-CHOP therapy.

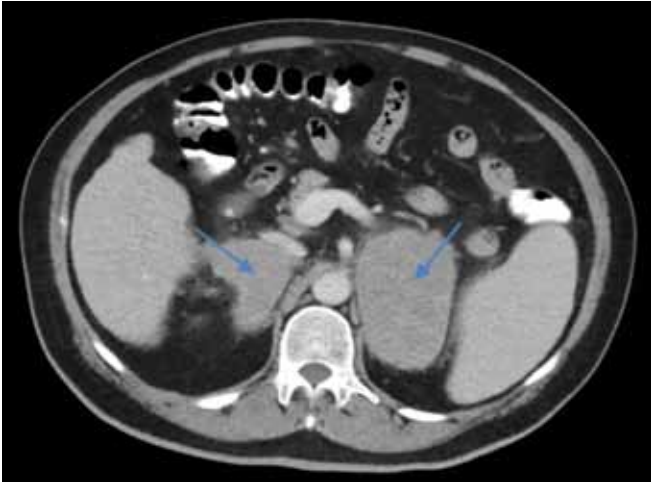

Fig. 1: Computed tomography scan showing large bilateral adrenal lesions. The left adrenal measured 8.0 cm, and the right adrenal measured 4.0 cm; axial CT imaging showing bilateral, bulky adrenal masses (arrows point to location of tumors)

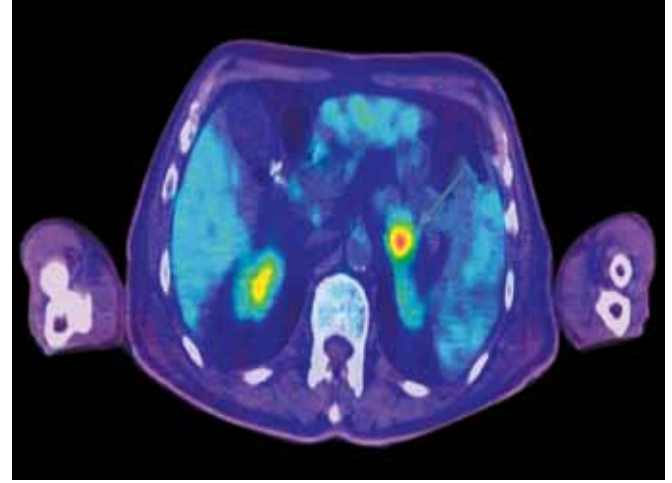
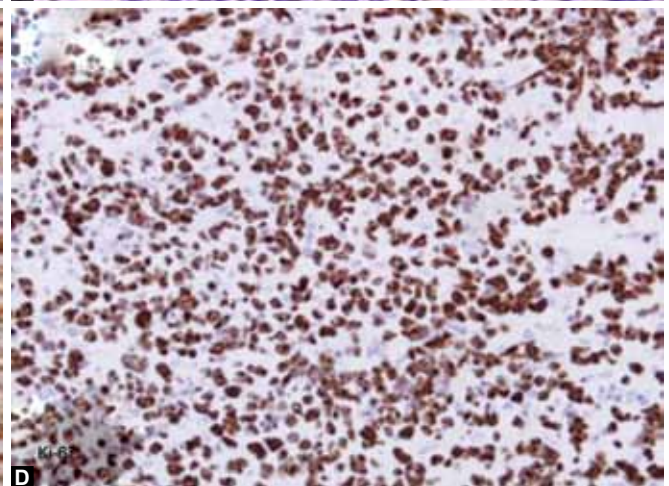
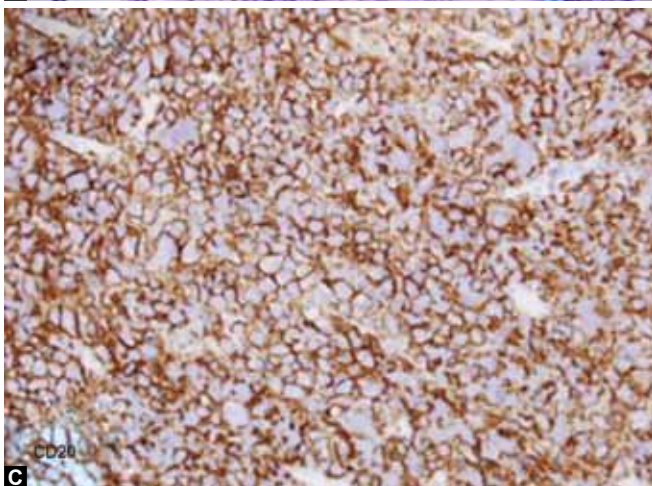
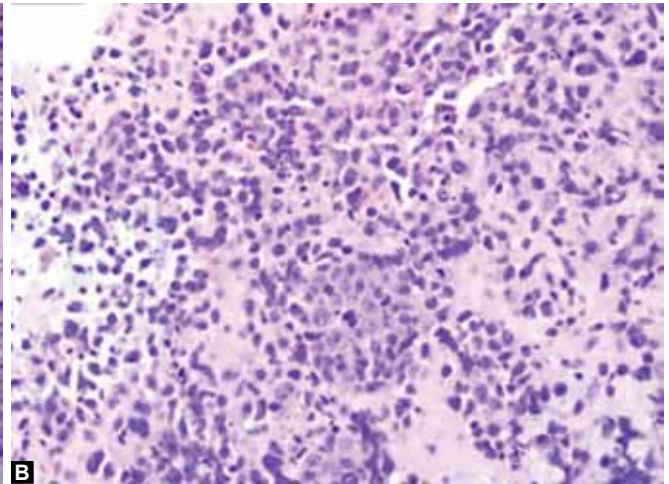
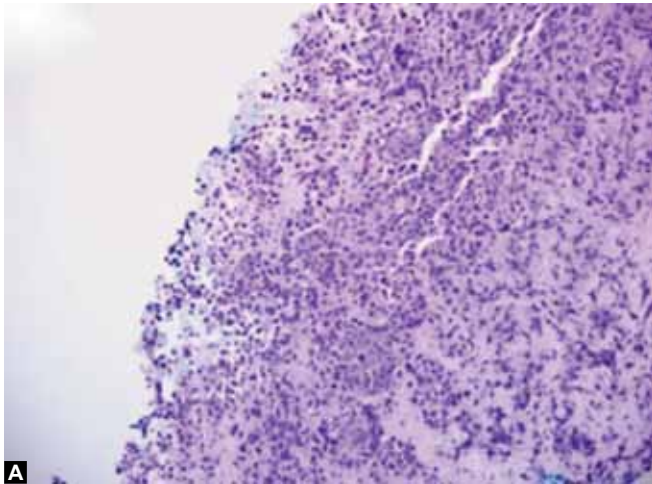


Fig. 2: Positron emission tomography/computed tomography showing no other locations of significant FDG-avid lesions apart from the adrenals, PET-CT image showing left adrenal FDG avid tumor (arrow pointing to tumor)



Figs 3A to D: The adrenal tumor is composed of sheets of medium to large sized neoplastic lymphoid cells with vesicular nuclei and single to multiple nucleoli. H&E Original magnifications 200x (A) and 400x (B), the neoplastic lymphoid cells are positive for CD20; Original magnification 400x (C) the neoplastic lymphoid cells have a high Ki-67 proliferative index of up to 90%; original magnification 400x (D); histological slides showing presence of DLBCL

DISCUSSION

Primary adrenal lymphomas are rare, but remain a diagnostic possibility in the evaluation of adrenal masses (Table 1). The diagnosis of a patient with primary adrenal lymphoma can be challenging because symptoms are non-specific, and only 50% of patients have concomitant adrenal insufficiency, which occurs when there is at least 90% destruction of adrenal parenchyma.¹⁰ Other features which can point to the diagnosis of primary adrenal lymphoma include a male predominance, as well as the presence of bilateral disease. Bilateral adrenocortical carcinoma occurs in only 10% of patients, whereas lymphoma is more commonly bilateral in more than 50% of cases.⁷⁻⁹ There is lack of a uniform consensus on the definition of primary adrenal lymphoma in the past. However, recently there have been efforts to define this disease entity.¹¹ Primary adrenal lymphoma is defined when both of the following conditions are present:

- There is no prior history of lymphoma elsewhere;
- If lymph nodes or other organs are involved, adrenal lesions are unequivocally dominant.

The incidence of primary adrenal lymphoma has been increasing over the last few decades,¹¹ most likely due to improved diagnostic imaging modalities. Men appear to be affected more than women⁷ and adrenal involvement is bilateral in more than 70% of cases.^{8,9} The most common symptoms are fever, pain and associated B-symptoms, and seen with bilateral lesions in comparison to unilateral lesions.¹¹ The incidence of adrenal insufficiency is seen in patients with more than 90% of gland destruction¹² and more commonly in the presence of bilateral disease.¹³

Diagnostic modalities include imaging with ultrasonography (US), CT, magnetic resonance imaging (MRI) and functional imaging, such as gallium 67 scintigraphy imaging or positron emission tomography scans.¹⁴⁻¹⁶ On MRI imaging, the adrenal lesions are characterized by low signal intensity on T1-weighted images, and heterogeneous high signal intensity on T2-weighted images.¹⁷ Histologic diagnosis is confirmative, but requires functional assessment prior to tissue biopsy (Tables 2 and 3). The predominant type of primary adrenal lymphoma in more than 70% of cases is diffuse large B-cell lymphoma (DLBCL), with a nongermlinal center B-cell phenotype.¹⁸⁻²¹ Most cases of primary adrenal DLBCL has BCL6 gene rearrangement and is associated with a poor prognosis.²¹

Numerous treatment regimens for the management of primary adrenal lymphoma have been proposed, however owing to the rarity of this condition, no comparisons have been made between the various treatment modalities. These modalities include bilateral adrenalectomy,

Table 1: Common causes of large adrenal masses

- | |
|---|
| <ul style="list-style-type: none"> • Benign <ul style="list-style-type: none"> – Adenoma – Pheochromocytoma – Myelolipoma • Malignant <ul style="list-style-type: none"> – Adrenocortical carcinoma – Lymphoma – Metastases to adrenals |
|---|

Table 2: Different diagnostic criteria for primary adrenal lymphoma

<i>Kim et al</i> ⁶	<i>Zhou et al</i> ²³
Absence of extra-adrenal involvement, or	Histology proven adrenal lymphomatous disease
Adrenal lesion is dominant if lymph nodes or other organs involved	No nodal involvement
	Absence of leukemia on hematological investigations
	Absence of organ involvement within 6 months of diagnosis of adrenal disease

Table 3: Investigations for functional assessment of adrenal tumor²⁴

- | |
|---|
| <ul style="list-style-type: none"> • Basal cortisol, ACTH • DHEA, 17-OH progesterone, androstenedione, testosterone, estradiol • Urinary 24 hours pheochromocytoma screen • Dexamethasone suppression test • Aldosterone/renin ratio |
|---|

chemotherapy, radiotherapy, and a combination of these.¹⁰ The role of bilateral adrenalectomy remains controversial and has been associated with poor prognosis.⁴ It is therefore important to establish a diagnosis of lymphoma via percutaneous techniques as opposed to following resection of the tumor as this subjects the patient to unnecessary surgical morbidity.

Chemotherapy remains the mainstay of treatment. CHOP (cyclophosphamide, doxorubicin, vincristine and prednisone) which is the most commonly used regimen for lymphomas²² has been used for the treatment of primary adrenal lymphoma.^{11,19} The addition of rituximab to the CHOP regimen in patients with primary adrenal lymphoma was studied in a retrospective review by Kim et al and showed encouraging improvements in overall survival as well as complete remission rates.⁶ Two years overall survival rate was 68.3%, with complete remission achieved in 54.8% of patients. In particular, the impact on outcomes of rituximab therapy has shown to be greatest in the elderly.²³ The study also concluded that complete remission was associated with improved overall survival rates. In contrast, surgery and radiotherapy have not been shown to have survival benefit for patients.⁶

CONCLUSION

Establishing the correct diagnosis of adrenal lymphoma is essential in the management of the patient. Though rare, this condition must be suspected when large bulky and bilateral adrenal tumors are found. The treatment for adrenal lymphoma is nonsurgical, and obtaining a diagnosis precludes the patient from potentially debilitating major surgery. The prognosis of the condition is generally poor.

REFERENCES

- Mansmann G, Lau J, Balk E, Rothberg M, Miyachi Y, Bornstein SR. The clinically inapparent adrenal mass: update in diagnosis and management. *Endocrine Reviews* 2004 Apr;25(2):309-340.
- Nishiuchi T, Imachi H, Fujiwara M, Murao K, Onishi H, Kiguchi T, et al. A case of non-Hodgkin's lymphoma primary arising in both adrenal glands associated with adrenal failure. *Endocrine* 2009 Feb;35(1):34-37.
- Al-Fiar FZ, Pantalony D, Shepherd F. Primary bilateral adrenal lymphoma. *Leukemia and Lymphoma* 1997 Nov;27(5-6):543-549.
- Grigg AP, Connors JM. Primary adrenal lymphoma. *Clin Lymphoma* 2003 Dec;4(3):154-160.
- Ozimek A, Diebold J, Linke R, Heyn J, Hallfeldt K, Mussack T. Bilateral primary adrenal non-Hodgkin's lymphoma and primary adrenocortical carcinoma—review of the literature preoperative differentiation of adrenal tumors. *Endocrine J* 2008 Aug;55(4):625-638.
- Kim YR, Kim JS, Min YH, Hyunyon D, Shin HJ, Mun YC, Park Y, Do YR, Jeong SH, Park JS, et al. Prognostic factors in primary diffuse large B-cell lymphoma of adrenal gland treated with rituximab-CHOP chemotherapy from the consortium for improving survival of lymphoma (CISL). *J Hematol Oncol* 2012;5:49.
- Wang J, Sun NC, Renslo R, Chuang CC, Tabbarah HJ, Barajas L, et al. Clinically silent primary adrenal lymphoma: a case report and review of the literature. *Am J Hematol* 1998 Jun;58(2):130-136.
- Wu HC, Shih LY, Chen TC, Chu SH, Tsai CC. A patient with bilateral primary adrenal lymphoma, presenting with fever of unknown origin and achieving long-term disease-free survival after resection and chemotherapy. *Annals of Hematol* 1999 Jun;78(6):289-292.
- Kumar R, Xiu Y, Mavi A, El-Haddad G, Zhuang H, Alavi A. FDG-PET imaging in primary bilateral adrenal lymphoma: a case report and review of the literature. *Clin Nucl Med* 2005 Apr;30(4):222-230.
- Ercolak V, Kara O, Gunaldi M, Usul Afsar C, Bozkurt Duman B, Acikalin A, et al. Bilateral primary adrenal non-hodgkin lymphoma. *Turk J Haematol* 2014 Jun;31(2):205-206.
- Rashidi A, Fisher SI. Primary adrenal lymphoma: a systematic review. *Ann Hematol* 2013 Dec;92(12):1583-1593.
- Rosenthal FD, Davies MK, Burden AC. Malignant disease presenting as Addison's disease. *Brit Med J* 1978 Jun 17;1(6127):1591-1592.
- Lam KY, Lo CY. Metastatic tumours of the adrenal glands: a 30-year experience in a teaching hospital. *Clin Endocrinol* 2002 Jan;56(1):95-101.
- Inan N, Arslan A, Akansel G, Anik Y, Balci NC, Demirci A. Dynamic contrast enhanced MRI in the differential diagnosis of adrenal adenomas and malignant adrenal masses. *Eur J Radiol* 2008 Jan;65(1):154-162.
- Hahn JS, Choi HS, Suh CO, Lee WJ. A case of primary bilateral adrenal lymphoma (PAL) with central nervous system (CNS) involvement. *Yonsei Med J* 2002 Jun;43(3):385-390.
- Salvatore JR, Ross RS. Primary bilateral adrenal lymphoma. *Leukemia and lymphoma* 1999 Jun;34(1-2):111-117.
- Gupta P, Bhalla A, Sharma R. Bilateral adrenal lesions. *J Med Imag Radiat Oncol* 2012 Dec;56(6):636-645.
- Horiguchi K, Hashimoto K, Hashizume M, Masuo T, Suto M, Okajo J, et al. Primary bilateral adrenal diffuse large B-cell lymphoma demonstrating adrenal failure. *Int Med* 2010;49(20):2241-2246.
- Kim KM, Yoon DH, Lee SG, Lim SN, Sug LJ, Huh J, et al. A case of primary adrenal diffuse large B-cell lymphoma achieving complete remission with rituximab-CHOP chemotherapy. *J Korean Med Sci* 2009 Jun;24(3):525-528.
- Hsu CW, Ho CL, Sheu WH, Harn HJ, Chao TY. Adrenal insufficiency caused by primary aggressive non-Hodgkin's lymphoma of bilateral adrenal glands: report of a case and literature review. *Ann Hematol* 1999 Mar;78(3):151-154.
- Mozos A, Ye H, Chuang WY, Chu JS, Huang WT, Chen HK, et al. Most primary adrenal lymphomas are diffuse large B-cell lymphomas with non-germinal center B-cell phenotype, BCL6 gene rearrangement and poor prognosis. *Mod Pathol* 2009 Sep;22(9):1210-1217.
- Fisher RI, Gaynor ER, Dahlborg S, Oken MM, Grogan TM, Mize EM, Glick JH, Coltman CA Jr, Miller TP. Comparison of a standard regimen (CHOP) with three intensive chemotherapy regimens for advanced non-Hodgkin's lymphoma. *N Engl J Med* 1993 Apr 8;328(14):1002-1006.
- Zhou L, Peng W, Wang C, Liu X, Shen Y, Zhou K. Primary adrenal lymphoma: radiological; pathological, clinical correlation. *Eur J Radiol* 2012;81:401-405.
- Arnaldi G, Boscaro M. Adrenal incidentaloma. *Best Pract Res Clin Endocrinol Metab* 2012;26:405-419.

