

## CASE REPORT

# Immediate Temporization Loading of Multiple Implants in the Maxillary Esthetic Zone: A Clinical Report

<sup>1</sup>Gagan Sabharwal, <sup>2</sup>Panna Mangat

## ABSTRACT

Early or delayed loading is a fundamental problem in fully understanding the dynamic nature of implant loading is the confusion that exists regarding the torque load delivered to the implant complex, the initial force transformation/stress/strain developed within the system of implant complex assembly. In our clinical case report, maxillary anterior teeth were replaced using immediate implant supporting provisional restoration. During the provisional phase, the occlusion was adjusted so, there is no centric or eccentric contact with the antagonist teeth. An impression was made and final restoration was cemented after 4 months. By implementing this protocol, an optimal definitive result could be achieved, together with immediate patient satisfaction. However, cooperation among several disciplines and careful patient selection is required.

**Keywords:** Dental implants, Esthetic zone, Immediate loading, Immediate temporization.

**How to cite this article:** Sabharwal G, Mangat P. Immediate Temporization Loading of Multiple Implants in the Maxillary Esthetic Zone: A Clinical Report. *Int J Clin Implant Dent* 2015; 1(2):77-81.

**Source of support:** Nil

**Conflict of interest:** None

## INTRODUCTION

Many clinicians today recommend implant therapy for patients requiring tooth replacement. This therapy can provide a highly successful restoration of both function and esthetics.<sup>1</sup>

Conventionally, after the placement of dental implants, a 3- to 6-month load-free healing period has been traditionally suggested as the optimal period to ensure successful healing and osseointegration.<sup>2-4</sup> This recommendation is based on the notion that increased vertical or lateral force on the implant during the healing

phase results in implant motion, aberrant healing, and fibrous tissue encapsulation, rather than the bone formation required for osseointegration.<sup>5-8</sup>

Numerous practitioners now advocate immediate loading of implants.<sup>9-14</sup> The implants were restored immediately following surgical placement with acrylic resin provisional crown adjusted to eliminate occlusal contacts. Metal-ceramic/metal free final restorations were placed 4 to 6 months postoperatively.<sup>15</sup>

The advantages of immediately temporary loading implants are clear: they allow for shorter treatment times, the patient is subjected to only one surgical event and the patient is provided with an esthetic restoration on the day of surgery.<sup>16</sup>

## HISTORICAL PERSPECTIVE

To understand the loading of implants, it is necessary to appreciate how loading protocols were established. Loading protocols were arrived at originally by Branemark and associates.<sup>17</sup>

The initial stage of development lasted from the mid 1960s until 1968. A development phase followed from 1968 until 1971, and then a routine stage for the technique followed from 1971 until 1975. During the early and development stages, one aspect that was investigated was loading protocols. Various healing times were evaluated and it was determined that shorter healing times resulted in failure of the implants. These findings suggested that a healing time of 3 months was required in the mandible and 6 months of healing was required for the maxilla. These healing times were used by clinicians and in many studies, 3 months in the mandible and 6 months in the maxilla became recognized as conventional healing times.<sup>18</sup>

The issue is not really the timing of the loading (immediate loading or not) rather, it is the ability to minimize the motion (less than 150 microns), during the healing process. If one considers ways to clinically minimize motion during the healing process, several ways are possible and have been used.

These include are as follows:

- Submerging the implant into the bone tissue below the soft tissues;
- Placing the implant into cortical bone coronally and apically, a process called bicortical stabilization;

<sup>1</sup>Consultant, <sup>2</sup>Reader

<sup>1</sup>Department of Dental Sciences, Fortis Memorial Research Institute, Gurgaon, Haryana, India

<sup>2</sup>Department of Conservative Dentistry and Endodontics, Divya Jyoti College of Dental Sciences and Research, Ghaziabad Uttar Pradesh, India

**Corresponding Author:** Gagan Sabharwal, Consultant, Department of Dental Sciences, Fortis Memorial Research Institute Gurgaon, Haryana, India, Phone: 01244962200, e-mail: drgagan sabharwal@gmail.com

- Rigid splinting of the implants orally;
- Accelerating the rate of healing around the implant;
- Providing cross-arch stabilization especially in cortical bone;
- Keeping the implant restoration out of occlusion and/or opposing a denture rather than a tooth or fixed partial denture; and
- Placing the implant with a large amount of primary contact and/or including press fitting the implant in the cortical bone created by flaring the top of the implant. This last technique is performed by using drills with slightly less diameters than the implant diameter or preparing osteotomy sites smaller than recommended, such as not using the final bur in the preparation of the osteotomy (Bunder drilling) or using osteotomes to a diameter less than the implant diameter. All of these clinical procedures can minimize motion of the implant during the healing process and have been used in clinical practice.<sup>1</sup>

More recent observation is that under some conditions, investigators have reported that the success rates on immediately loaded implants can be as high as success rates on conventionally loaded implants.<sup>19</sup>

These findings reinforce a visionary statement made by Ledermann<sup>20</sup> in 1979. He suggested that the crucial factor for successful osseointegration was the stability of the implant during the healing phase such that any motion at the bone-to-implant interface was below a certain threshold. Other studies also suggest that for osseointegration to occur, the mobility of the implant must be maintained below a certain critical amount.<sup>21</sup>

## CLINICAL REPORT

A 24-year-old male with a history of road traffic accident 1.2 years back was referred for the replacement of missing anterior teeth, on examination patient had missing maxillary central and lateral incisors on either side, maxillary left canine and mandibular right central and lateral incisor (Fig. 1).

Patient desired a durable and fixed restoration for the upper anterior and lower teeth, due to financial consideration upper implant supported fixed restoration and lower metal—ceramic bridge was planned.

The patient was healthy, did not smoke, and intraoral examination revealed a healthy, maintained dentition. Clinically and in OPG (Fig. 2) adequate bone volume was present at the future implant site in all dimensions, a cone beam computed tomography (CBCT) (Fig. 3) was performed for bone type and volume and to evaluate the exact length of the implants and no pathology of the bone and adjacent teeth was noted. It was decided to use an immediate temporization of the implants. One day before

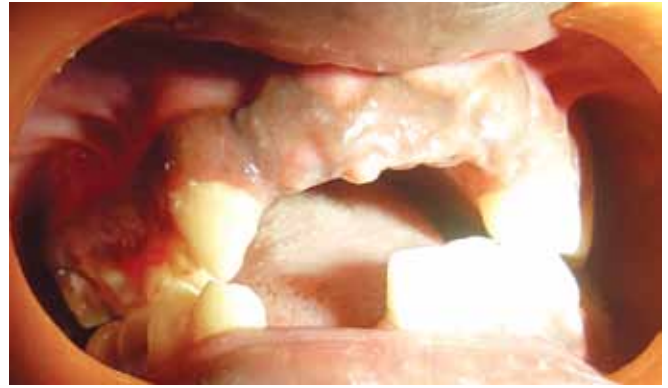

Fig. 1: Perioperative

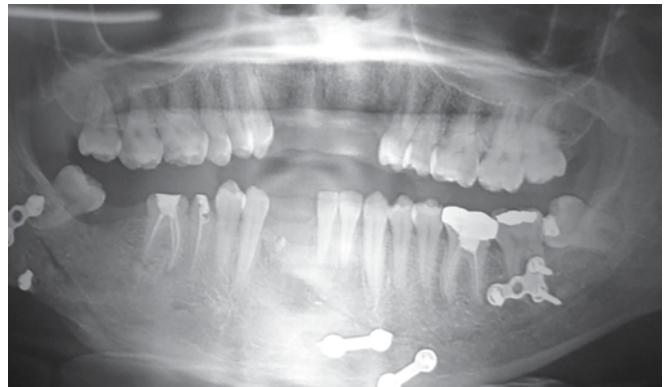


Fig. 2: Preoperative orthopantomogram

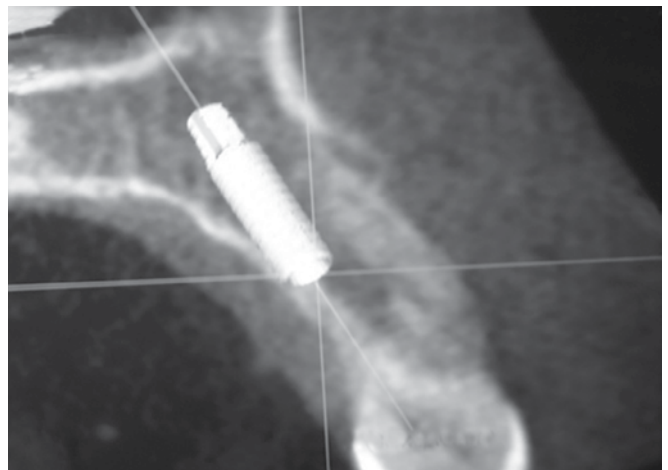
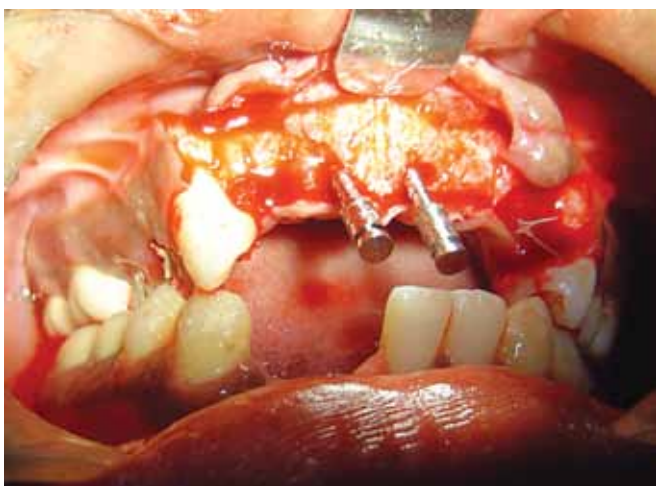


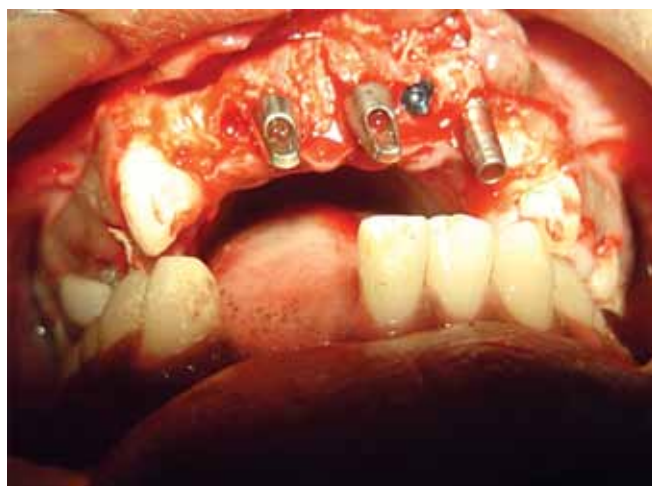Fig. 3: Dentascan with exact size and angulation

surgery, the patient was advised to take combination antibiotics amoxicillin 500 mg and potassium clavulanate 125 mg twice daily and used a 0.2% chlorhexidine mouthwash for oral disinfection.

Following the administering of local anesthesia 2% lidocaine hydrochloride with 1:80,000 adrenaline [Lignospan (Septodont, France)]. A 3.3 mm × 13 mm spiral implants were selected for placement in the region.<sup>11,21-23</sup> Surgical template was made, trapezoidal flap raised, areas where the implants to be placed were marked with a 2 mm round bur. A 2 mm surgical drill was used to perform the osteotomy upto 13 mm parallel/



**Fig. 4:** Parallel and depth pins *in situ*

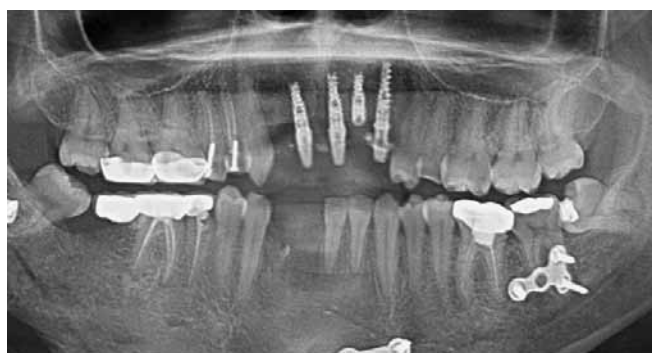

**Fig. 5:** Implants with abutment note 22 region implant with cover screw not used in immediate loading

depth guide pin place for guiding the angulation of the other implants (Figs 4 and 5) and RVG X-ray was taken to conform. A 2.8 mm surgical drill was used up to the desired length. The final 3.2 mm drill was not used and the implants were threaded in place (Bunder drilling technique). Good primary implant stability of >45 Ncm was obtained in three out of four implants, determined with a measurement device for implant site preparation. 20 Ncm of torque was obtained in the maxillary left lateral incisor region implant.

The shoulder of the implant was placed at a depth of 2 mm apical to the buccal and cervical aspect of the prospective clinical crown to provide soft tissue to develop an adequate emergence profile.

Following implant placement 15° angulated abutments were placed on the maxillary right central and lateral incisor region implant and a straight abutment on the maxillary left canine region implant; cover screw was placed on the maxillary left lateral incisor region implant which was not used in immediate loading (Fig. 6). The flaps were closed with 3-0 vicryl. Abutments were milled intraorally, impressions made and provisional acrylic bridge fabricated and cemented the next day

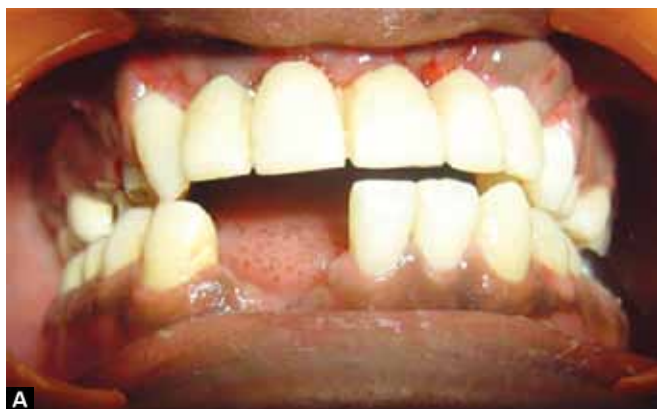

**Fig. 6:** Postoperative orthopantomogram

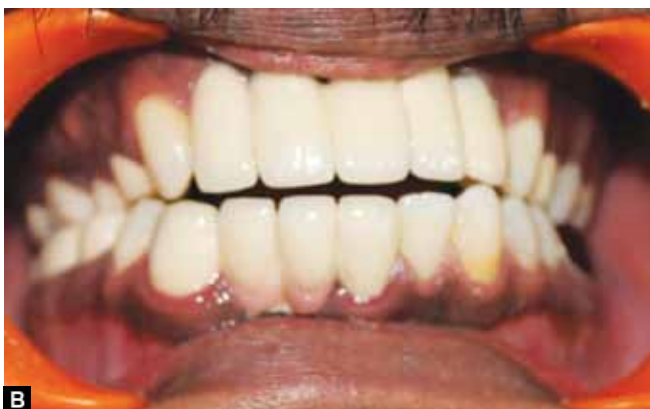(Fig. 7A); Special care was taken to prevent any centric and eccentric occlusion contacts with the antagonist teeth.

The patient was instructed to follow a soft diet, to avoid exerting force on the provisional restoration, good oral care and to continue chlorhexidine rinses for 7 days postoperatively, diclofenac potassium 75 mg twice daily for the time period needed and antibiotics were continued for total of 5 days post surgery.

Four months later, the implant level impressions were made using impression posts and according to gingival height abutments were selected, milled in the laboratory and the metal ceramic final restoration fabricated (Fig. 7B).



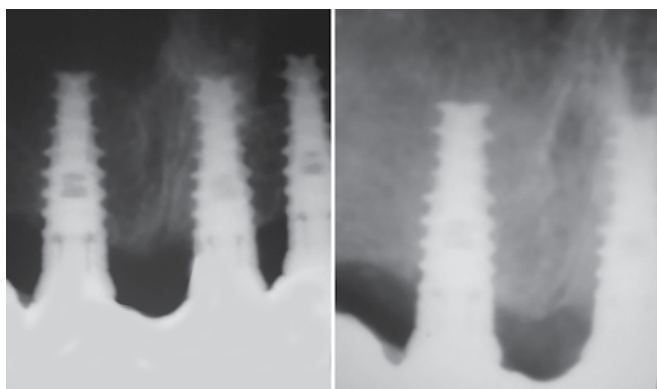
**A**



**B**

**Figs 7A and B:** (A) Temporary acrylic bridge and (B) final restoration in place





**Fig. 8:** One year postoperative X-ray

Follow-up X-ray after 1 year (Fig. 8) revealed good osseointegration and minimal bone loss.

## DISCUSSION

A summary of loading protocols, based on historical development, biological considerations, and the literature indicate that shortened loading protocols are dependent on:

1. The quantity and quality of bone at the implant site and, as a consequence, the amount of primary bone contact, and
2. The rapidity of the bone formation and remodeling of the bone surrounding the implant with resultant secondary bone contact.

These conditions result in two clinical scenarios for supporting reduced healing times. If the implant site has high quality and quantity of existing bone, immediate loading protocols are possible. If the implant site has low quality and quantity of native bone and bone remodeling and bone formation are required, immediate loading is more contraindicated and early loading protocols are possible. However, many factors can be important, such as the characteristics of the implant surface, the location of high-quality bone in the implant site, the ability to protect the implant restoration with adjacent tooth structure, the use of proteins (growth factors or stimulants) or materials and matrices used around the implant, and so forth. These factors are related to either (1) stimulating new bone-to-implant contact or (2) minimizing micromotion of the implant.

In all situations, it is important to remember that the goal is improved patient care. Procedures that put the implant restoration at high risk in the patient are unacceptable. Understanding the historical development of implant healing times, the biological events that result in osseointegration, and knowing the literature on shortened healing times on implants, allows the clinician to appreciate options for various loading protocols and to improve the patient care they deliver.<sup>25-28</sup>

## CONCLUSION

This report describes an immediate temporary loading, finalized with the placement of 5 unit PFM bridge. A major prerequisite for immediate loading is a high degree of primary stability in terms of high insertion torque.<sup>24</sup>

In this treatment, an initial insertion torque of at least 45 Ncm was reached in three of the four implants placed and only three were used for immediate loading. Although clinical studies on immediate implant loading reported varying minimal insertion torques for immediate loading, the authors of this report adopted a threshold of 40 to 45 Ncm.

According to Misch (2004) classification based on loading protocol:

1. Conventional loading/delayed loading or the two stage protocol; where in first stage, implants are surgically placed and the patient is made to wait for 6 months for osteointegration; second stage surgery is then performed where the healing cap is placed and after a week of satisfactory formation of a gingival collar for emergence profile is achieved, impressions are made for implant prosthesis, which may be cement or screw retained.
2. One stage protocol
  - Immediate loading—when a provisional prosthesis is placed in the same session as the surgery. It is further divided based on the biomechanical definition. (a) immediate loading with provisional prosthesis out of or shy of occlusion. (b) Immediate loading with provisional prosthesis in occlusion.
  - Early loading—when the implant prosthesis is placed after a delay of 48 to 72 hours.

## REFERENCES

1. Cochran. The evidence for immediate loading of implants. *J Evid Base Dent Pract* 2006;6:155-163.
2. Branemark PI, Hansson BO, Adell R, et al. Osseointegrated implants in the treatment of the edentulous jaw: experience from a 10-year period. *Scand J Plast Reconstr Surg* 1977;16(Suppl):1.
3. Calvo MP, Muller E, Garg AK. Immediate loading of titanium hexed screw-type implants in the edentulous patient: case report. *Implant Dent* 2000;9(4):351-357.
4. Yoo RH, Chuang SK, Erakat MS, et al. Changes in crestal bone levels for immediately loaded implants. *Int J Oral Maxillofac Implant* 2006;21(2):253-261.
5. Albrektsson T, Branemark PI, Hansson HA, et al. Osseointegrated titanium implants: requirements for ensuring a longlasting, direct bone-to-implant anchorage in man. *Acta Orthop Scand* 1981;52:155.
6. Albrektsson T, Hansson T, Lekholm U. Osseointegrated dental implants. *Dent Clin North Am* 1986;60:151.
7. Brunski JB. Biomechanical factors affecting the bone-dental implant interface. *Clin Mater* 1992;10(15):153-201.

8. Szmukler-Moncler S, Salama H, Reingewirtz Y, et al. Timing of loading and effect of micromotion on bone-dental implant interface: review of experimental literature. *J Biomed Mater Res* 1998;60:192.
9. Ibanez JC, Jalbout ZN. Immediate loading of osseotite implants: two-year results. *Implant Dent* 2002;11(2):128-136.
10. Piattelli A, Corigliano M, Scarano A, et al. Immediate loading of titanium plasma-sprayed implants: an histologic analysis in monkeys. *J Periodontol* 1998;69:321-327.
11. Gatti C, Chiapasco M. Immediate loading of Branemark implants: A 24-month follow-up of a comparative prospective pilot study between mandibular overdentures supported by conical transmucosal and standard MK II implants. *Clin Implant Dent Relat Res* 2002;4(4):190-199.
12. Chiapasco M, Gatti C, Rossi E, et al. Implant-retained mandibular overdentures with immediate loading: a retrospective multicenter study on 226 consecutive cases. *Clin Oral Implants Res* 1997;8:48-57.
13. Chiapasco M, Gatti C. Implant-retained mandibular overdentures with immediate loading: a 3- to 8-year prospective study on 328 implants. *Clin Implant Dent Relat Res* 2003;5:29-38.
14. Albrektsson T, Zarb GA, Worthington P, et al. The long-term efficacy of currently used dental implants: a review and proposed criteria of success. *Int J Oral Maxillofac Implants* 1986;1(1):11-25.
15. Cooper L, Felton DA, Kugelberg CF, et al. A multicenter 12-month evaluation of single-tooth implants restored 3 weeks after 1 stage surgery. *Int J Oral Maxillofac Implants* 2001;16(2):182-192.
16. Deporter DA. A prospective clinical study in humans of an endosseous dental implant partially covered with a powder-sintered porous coating: 3- to 4-year results. *Int J Oral Maxillofac Implants* 1996;11(1):87.
17. Branemark PI, Hansson BO, Adell R, Breine U, Lindstrom J, Hallen O, et al. Osseointegrated implants in the treatment of the edentulous jaw: experience from a 10-year period. *Scand J Plast Reconstr Surg* 1977;16(Suppl):1-132.
18. Szmukler-Moncler S, Piattelli A, Favero GA, Dubruille JH. Considerations preliminary to the application of early and immediate loading protocols in dental implantology. *Clin Oral Implants Res* 2000;11(1):12-25.
19. Chiapasco M, Abati S, Romeo E, Vogel G. Implant-retained mandibular overdentures with Branemark system MKII implants: a prospective comparative study between delayed and immediate loading. *Int J Oral Maxillofac Implants* 2001;16(4):537-546.
20. Ledermann P. [Complete denture support in edentulous problem mandibles with help from 4 titanium plasma-coated PDL screw implants]. *SSO Schweiz Monatsschr Zahnheilkd* 1979;89(11):1137-1138. (German)
21. Degidi M, Piattelli A. Immediate loading of dental implants in selected cases may provide similar success rates as compared with delayed loading. *Int J Oral Maxillofac Implants* 2005;20(1):99-107.
22. Branemark PI, Hansson BO, Adell R, Breine U, Lindstrom J, Hallen O, et al. Osseointegrated implants in the treatment of the edentulous jaw: experience from a 10-year period. *Scand J Plast Reconstr Surg* 1977;16(Suppl):1-132.
23. Cochran DL, Schenk RK, Lussi A, Higginbottom FL, Buser D. Bone response to unloaded and loaded titanium implants with a sandblasted and acid-etched surface: a histometric study in the canine mandible. *J Biomed Mater Res* 1998;40(1):1-11.
24. Kan JY, Rungcharassaeng K, Lozada J. Immediate placement and provisionalization of maxillary anterior single implants: 1-year prospective study. *Int J Oral Maxillofac Implants* 2003;18(1):31-39.
25. Cochran DL, Morton D, Weber HP. Consensus statements and recommended clinical procedures regarding loading protocols for endosseous dental implants. *Int J Oral Maxillofac Implants* 2004;19(Suppl):109-113.
26. Chiapasco M. Early and immediate restoration and loading of implants in completely edentulous patients. *Int J Oral Maxillofac Implants* 2004;19(Suppl):76-91.
27. Ganeles J, Wismeijer D. Early and immediately restored and loaded dental implants for single-tooth and partial-arch applications. *Int J Oral Maxillofac Implants* 2004;19(Suppl):92-102.
28. Morton D, Jaffin R, Weber HP. Immediate restoration and loading of dental implants: clinical considerations and protocols. *Int J Oral Maxillofac Implants* 2004;19(Suppl):103-108.