

Clinicopathological Conference Report—PM 25443

Respiratory Distress in Acute Promyelocytic Leukemia after ATRA Therapy: Not always due to Differentiation Syndrome

CPC Editor : Dr Nandita Kakkar¹
Pathologist (SR) Incharge : Dr Vani Bharani²
Pathology Discussant : Dr Ojas Gupta³
Clinical Discussant : Dr Deepa Shrestha⁴
Pathologist (Consultant) Incharge : Dr Ashim Das⁵
Hematology Consultant : Dr Shano Naseem⁶
Clinician (Consultant) Incharge : Dr SC Varma⁷

This case (PM 25443) was discussed on 9-3-2015, as a student clinicopathological exercise at PGIMER, Chandigarh, India.

Clinical details and case analysis: Dr Deepa Shrestha, Junior Resident, (Dept. of Internal Medicine, PGIMER, Chandigarh, India).

CLINICAL DETAILS

Date of Admission: 30-05-2013

Date of Death: 1-6-2013

A 50 years old male, resident of Kurukshetra, Haryana, was admitted to Hematology ward on 30/5/2013 with chief complains of high grade fever, perianal pain with swelling and cough with mucopurulent discharge since 20 days. Patient also developed shortness of breath since 10 days and had altered sensorium at time of admission. The patient had undergone a hemorrhoidectomy on 08/04/2013 at Karnal. He developed high-grade fever, cough and shortness of breath, one and half months after the surgery, for which he was admitted in Fortis Hospital, Chandigarh, on 23/05/2013. A perianal abscess was identified and drained. The pus culture grew *E. coli*. He was started on IV antibiotics (imipenem and tigecycline) for treating pneumonia. On routine hematologic investigation, he was found to have bicytopenia with leukocytosis. A diagnosis of acute promyelocytic leukemia was made on flow cytometry. Following this, he was started on all

transretinoic acid (ATRA) 40 mg BD and transfusion support. He developed worsening of shortness of breath and hepatorenal dysfunction and was shifted to Postgraduate Institute of Medical Education and Research (PGIMER) on 30/05/2013. Examination revealed that he was febrile with a temperature of 39°C and pulse rate was 116/min. He was tachypnic (respiratory rate 40/min). The SpO₂ was 98% on non-rebreathing mask. He was pale and icteric but there was no cyanosis, clubbing, pedal edema or peripheral lymphadenopathy. The oral hygiene was poor with mucosal plaques and oral ulcers. The patient was stuporosed but there were no signs of meningeal irritation. On systemic examination, bilateral coarse crepitations were present, which were more on left side than right. Patient had tachycardia and rest of cardiovascular system was essentially normal. On per abdomen examination, liver and spleen were just palpable. No free fluid was present. The perianal area showed a surgical wound in right lateral anal margin extending to right buttock. No purulent discharge was expressed on pressure. The per rectal examination revealed a normal anal tone and no mass lesion was palpable.

Investigations: Hemogram: Hb—8.9 gm/dl, TLC—41,900/mm³, DLC P 04, L08, M 07, E03, blasts 73, myelocytes 05 and platelets were reduced (40 × 10⁹/lt). The blasts were 2 to 4 times size of normal lymphocytes, nucleus bilobed/cleaved opened up chromatin with 1 to 2 prominent nucleoli, cytoplasm abundant with granules, occasional Auer rods seen. Renal function tests were deranged with a creatinine of 2.01 mg/dl and urea of 163.2 mg/dl. Sodium was 172 meq/l, potassium was 3.3 meq/l, total bilirubin was 4.03 mg/dl, conjugated bilirubin being 3.15 mg/dl, AST 62 IU/l, ALT 33 IU/l, ALP 198 IU/l, total protein 7.1 g/dl and albumin was 3.9 gm/dl. The coagulogram was deranged with PT 19 seconds, INR 1.4, aPTT 26 sec, fibrinogen 3.2 mg/l and d-dimer was positive.

^{1,5}Professor, ²Senior Resident, ^{3,4}Junior Resident

⁶Assistant Professor, ⁷Professor and Head

^{1,5}Department of Histopathology, Postgraduate Institute of Medical Education and Research, Chandigarh, India

^{2,3}Department of Pathology, Postgraduate Institute of Medical Education and Research, Chandigarh, India

^{4,7}Department of Internal Medicine, Postgraduate Institute of Medical Education and Research, Chandigarh, India

⁶Department of Hematology, Postgraduate Institute of Medical Education and Research, Chandigarh, India

Corresponding Author: Nandita Kakkar, Professor, Department of Histopathology, Postgraduate Institute of Medical Education and Research, Chandigarh, India, e-mail: nandita_kakkar@yahoo.com

Routine urine examination: Sugar nil, trace albumin, RBC: 10-12/hpf and polymorphs 2-3/hpf.

ECG: Normal sinus rhythm, ultrasonography (USG) abdomen revealed hepatomegaly with mild ascites.

NCCT head: Well-defined hypodense lesion (1.4 × 0.7 cm) in right basal ganglia/caudate nucleus region.

HRCT chest: Patchy consolidations with air bronchograms and ground glass opacities and nodules in bilateral lungs. No mediastinal and hilar lymphadenopathy, no pleural and pericardial effusion. Impression—patchy consolidation, GGOs and nodules in bilateral lungs likely infective.

Blood and urine culture were sterile. Wound swab culture and sensitivity grew *Acinetobacter* complex, sensitive only to Colistin.

Bone marrow aspirate (A-861/13): Consistent with acute promyelocytic leukemia.

Flow cytometry: 75% blasts—CD13, CD33 and CD45 positive CD 34 negative.

Course and management: The patient was managed in the emergency outpatient department. He was found to have anemia, raised leukocyte count and thrombocytopenia. Patient had dyselectrolytemia in form of hypernatremia, hypokalemia, along with deranged renal function test (RET) and liver function test (LFT). The chest X-ray showed bilateral fluffy opacities. Patient was started on antibiotics (imipenam and tigecycline), allopurinol, potassium supplementation and insulin. Dexamethasone and liposomal amphotericin were added. On 30/05/2013, the antibiotics were changed to colistin and linezolid. Acyclovir, insulin infusion and hydroxyurea were added. On 31/05/2013, the sensorium further worsened? Hypernatremia? Sepsis. Patient had upper gastrointestinal bleed for which pantoprazole was increased and FFP transfusions were given. On 1/5/15, the patient went into cardiopulmonary arrest.

Cardiopulmonary resuscitation (CPR) was done but he could not be revived. Units clinical diagnosis was acute promyelocytic leukemia (APML) high risk with severe sepsis (focus-perianal infection and pneumonia), multi-organ dysfunction syndrome? differentiation syndrome.

Antemortem Hematologic Work-up

Peripheral blood film: Hemoglobin—8.9 g/dl, TLC— $41.6 \times 10^9/\text{lt}$, Plt— $40 \times 10^9/\text{lt}$, reticulocyte count—1.2%. Differential count promyelocytes—98%, lymphocytes—2%. Many promyelocytes with plenty of Auer rods (faggots) were seen. Red blood cell morphology was normocytic normochromic. Occasional nucleated RBCs were seen.

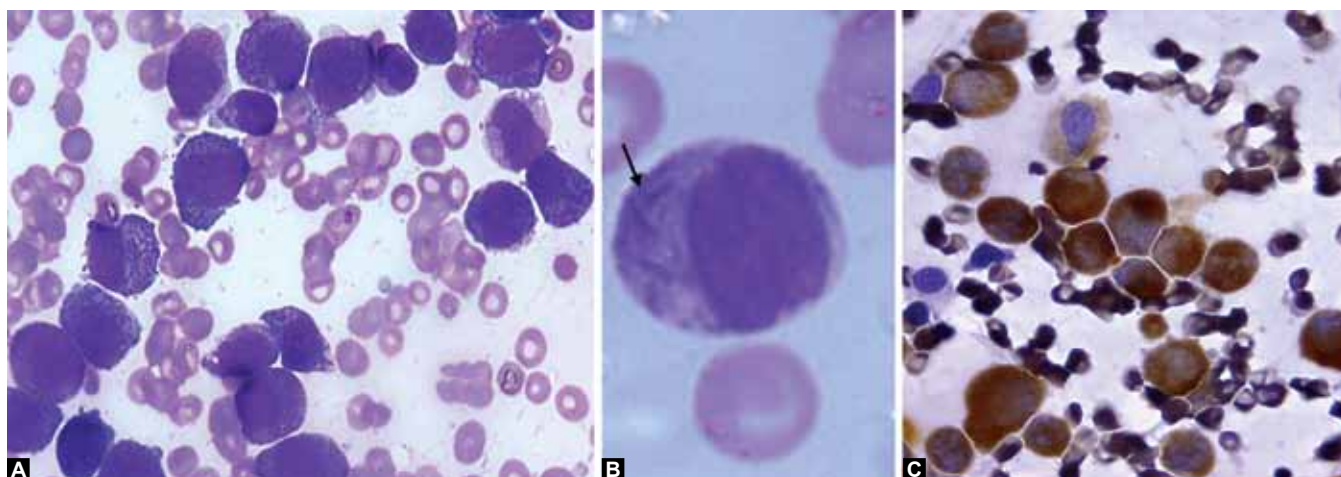
Bone marrow aspirate (Figs 1A to C) was particulate and hypercellular. There was proliferation of atypical promyelocytes (91%) (Fig. 1A), myelocytes 3%, metamyelocytes 2%, lymphocytes 4%. Many promyelocytes containing plenty of Auer rods (faggots) were seen (Fig. 1B). The promyelocytes were strongly MPO positive (Fig. 1C).

On flow cytometry, the cells were dim positive for CD45. CD13, CD33, CD117 and antiMPO were positive. CD34 and HLA-DR were negative.

Real-time polymerase chain reaction (RT-PCR) was performed which showed acute promyelocytic leukemia with t (15;17) (q22;q12); PML-RARA fusion transcript (WHO 2008).

CASE ANALYSIS

To sum up this, 50 years male patient underwent an uneventful hemorrhoidectomy. He subsequently developed fever, shortness of breath and cough with expectoration after one and half month of operation. He also developed a perianal infection. At presentation to PGI, he had altered sensorium. He was found to have anemia, leukocytosis and thrombocytopenia. The peripheral blood film examination and flow cytometry showed features of acute



Figs 1A to C: Antemortem bone marrow examination: (A) Myeloid hyperplasia with proliferation of promyelocytes (40×), (B) promyelocyte with Auer rods—faggot cell (100×) and (C) strong positivity with MPO (40×)

promyelocytic leukemia (AML-M3/APML). On biochemical tests, the patient had hypernatremia, deranged LFTs and RFTs. Chest X-ray revealed bilateral infiltrates. Bilateral consolidation with nodules and ground glass opacities were seen on computed tomography (CT) scan.

Thus, a basic diagnosis of acute promyelocytic leukemia high risk with evidence of infection, anemia, thrombocytopenia and DIC was made. Bleeding manifestation as ecchymotic spots and upper GI bleed were also present. There was leukocytosis $> 10,000/\mu\text{l}$.

The following clinical aspects are to be considered:

1. *Respiratory distress*: The etiology of the respiratory distress could be infective or noninfective. The infective etiology could include bacterial, fungal, mycobacterial, pneumocystis carinii and viral infections. The noninfective etiologies include differentiation syndrome (ATRA syndrome), pulmonary hemorrhage, leukemic infiltration and leukostasis.
 - *Bacterial infection*: This is a likely possibility as the patient had fever, cough, expectoration and shortness of breath. The duration of symptoms was short. On examination, there were crackles. Also, CT showed bilateral air bronchogram with consolidation. Acinetobacter was isolated from perianal wound swab. Points against this are no microbiological evidence and persistence of symptoms despite being on treatment.
 - *Fungal infection*: The immunocompromised state (functional neutropenia) of the patient and lack of response to treatment with broad spectrum antibiotics makes it a likely possibility. Additionally, CT chest showed nodules and GGOs. But, there was no microbiological evidence of a fungal infection. Galactomannan fungal serology and culture were negative. On CT scan, there was no evidence of halo/reverse halo sign and the patient did not respond to antifungals.
 - *Pulmonary tuberculosis (TB)*: Tuberculosis is a likely differential diagnosis due to the endemic setting and immunocompromised state of the patient. Also, a 3 weeks duration of illness supports TB. The lack of response to broad spectrum antibiotics and antifungals goes in favor. But, the patient had no history of pulmonary TB. There was no mediastinal/hilar lymphadenopathy and no pleural effusion. On CT scan, consolidation was diffuse and no upper lobe predilection was noted. There was no microbiological evidence of TB.
 - *Pneumocystis carinii pneumonia*: The immunocompromised state of the patient and hypoxia make this a clinical possibility. Also, there was a lack of response to broad spectrum antibiotics and antifungals. Bilateral ground glass opacities no

effusion and no lymphadenopathy on CT support the diagnosis. But, there was no microbiological evidence.

- *ARDS*: Extrapulmonary cause may include sepsis, cytokines storm and diffuse alveolar damage without any microorganism.
 - *Differentiation or ATRA syndrome*: The worsening of respiratory distress with start of ATRA therapy and radiological evidence of pulmonary infiltrates support a diagnosis of differentiation syndrome. But the patient did not have any other clinical features like edemas/weight gain, pleural or pericardial effusion. Also, there was no improvement with dexamethasone after stopping ATRA. So, differentiation syndrome is unlikely.
2. *Perianal infection*: The patient developed local tenderness and swelling following hemorrhoidectomy. There was history of incision and drainage of pus from the site. *E. coli* was isolated. Later at PGI, acinetobacter was isolated (likely hospital acquired). This could be a source of sepsis and dissemination.
 3. *Hepatic dysfunction*: The patient had conjugated hyperbilirubinemia with slightly raised transaminases and alkaline phosphatase. The possible cause could be a drug induced liver injury. This is a likely possibility, as the patient received multiple hepatotoxic drugs. Liver dysfunction could also be sepsis related. Differentiation syndrome also can present with liver dysfunction. Other possibilities include viral hepatitis, tropical infections or leukemic infiltration.
 4. *Renal dysfunction*: The main possibilities include sepsis induced AKI or a prerenal AKI. Drug-induced AKI should also be considered in the differential as the patient was treated with nephrotoxic medications. Renal dysfunction can also be a part of differentiation syndrome.

The terminal event in the patient was refractory septic shock, ARDS and respiratory failure. The cause of death being refractory septic shock. Thus, the final clinical diagnoses were: (1) APML-high risk, (2) severe sepsis with multiorgan dysfunction syndrome (ARDS, renal and hepatic dysfunction).

OPEN HOUSE DISCUSSION

- *Chairperson*: I invite the treating unit SR for comments.
- *Treating unit SR*: This case typically reflects the course of an AML patient who developed sepsis and multiorgan dysfunction. Our thought process has been reflected well by Dr Deepa. As this was a partial autopsy, the cause of the small intracranial SOL will remain unresolved.
- *Chairperson*: Case is open for discussion.



- Sr Dr Deepa has developed all possibilities of pulmonary infiltrates depending on the major radiographic findings on CT chest. Differentiation syndrome shows GGOs. Nodules with GGOs, a possibility of fungal infection and leukemic infiltrate have to be kept. If there is predominantly consolidation with few GGOs and nodules, bacterial infection is likely. For hypernatremia, diabetes insipidus must be ruled out.

Autopsy Findings: PM 25443—Dr Ojas Gupta Dr Vani Bharani

A partial autopsy was performed. The prosectors noted that the serous cavities were within normal limits. The bone marrow (Figs 2A to C) was hypercellular (Fig. 2A) and marrow spaces were packed with abnormal promyelocytes (Fig. 2B). Other hematopoietic elements were reduced. Immunohistochemistry for MPO was strongly positive (Fig. 2C). The lungs (Figs 3A to F) were heavy and weighed 1500 gm. They were firm to hard to feel. The pleura was dull, discolored and lustreless. No fibrinous tags were identified. Cut section (Fig. 3A) was firm and showed diffuse brownish discoloration (Fig. 3A). Tracheobronchial tree did not show any aspirated material. Pulmonary artery at hilum did not show any thrombus. On microscopy, extensive intra-alveolar hemorrhage (Fig. 3B). Hyaline membrane formation and edema (Fig. 3C) was noted. A small nodular area palpated on gross, showed a focus of angioinvasive fungal infection (Fig. 3D). The fungal hyphae were seen involving the adjoining lung parenchyma. The fungal hyphae were thin with septation, conforming to morphology of *Aspergillus*, better highlighted by Grocott's stain. Focal infiltration of promyelocytes was seen in alveolar septa (Fig. 3E), which was confirmed by immunohistochemistry for MPO (Fig. 3F). The liver (Fig. 4A) weighed 1280 gm. Grossly, the capsular surface was smooth and no nodularity was present. The cut surface, biliary tree, portal tract and hepatic veins were unremarkable. On microscopic examination, the liver showed maintained lobular architecture

and regular portal tracts. Focal infiltration of promyelocytes was seen in the portal tracts (Fig. 4B). The spleen (Fig. 4A) weighed 280 gm. Outer surface was smooth and cut surface was unremarkable. The spleen showed congested red pulp and attenuation of white pulp. Focal infiltration by promyelocytes was seen in the sinusoids (Fig. 4C). The esophagus showed multiple mucosal ulcers grossly. The ulcer bed showed inflammatory cells and granulation tissue, which was extending upto muscularis propria. The stomach was grossly normal. On microscopy, features of chronic superficial gastritis, with focal areas of lymphoid aggregates were seen. The kidneys together weighed 410 gm and were enlarged. On cut section, distinct corticomedullary junction with medullary congestion was noted. The glomeruli were unremarkable. Tubules show features of acute tubular necrosis. Interstitium and blood vessels were within normal limits. Grade II atherosclerosis was seen in the abdominal aorta. The heart weighed 450 gm. There was patchy loss of epicardial fat. There was concentric left ventricular hypertrophy with wall thickness of 1.7 cm. Ventricular cavities and valves were within normal limits and no vegetations were seen. Moderate anisonucleosis was noted on microscopy. Other organs including pancreas, small and large intestine, adrenal glands, urinary bladder, lymph nodes, testis, skeletal muscles were grossly and microscopically unremarkable.

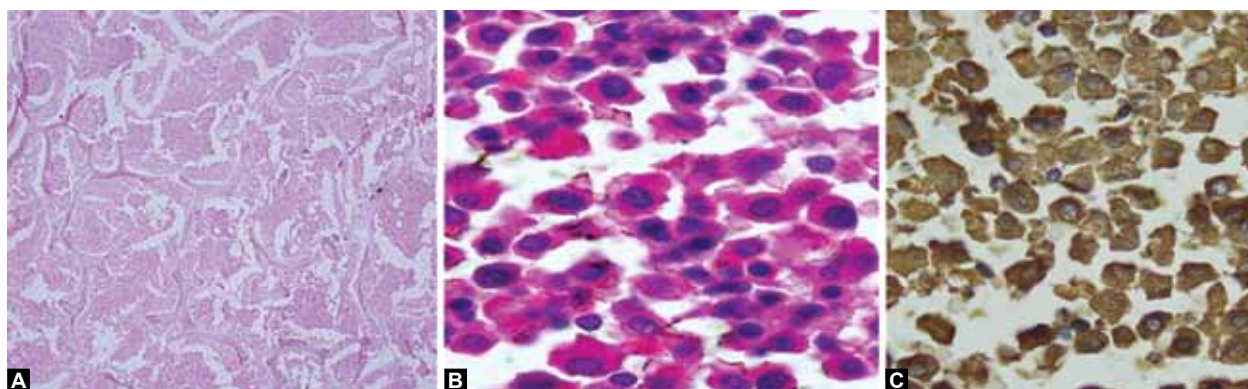
FINAL AUTOPSY DIAGNOSIS

A 50-year-old male, known case of acute promyelocytic leukemia (AP-M3):

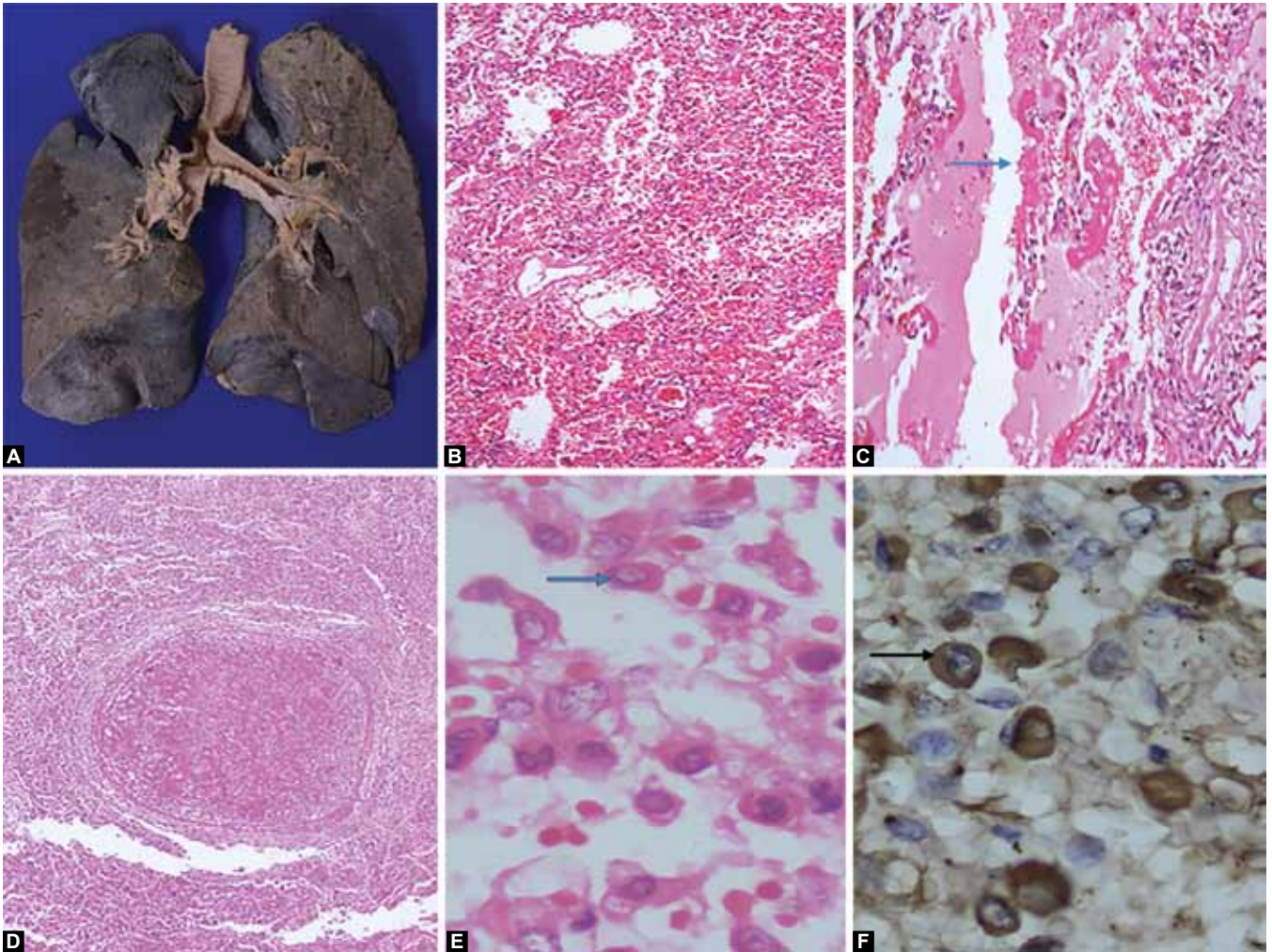
- Leukemic infiltrates (mild) in liver, spleen and lung
- Diffuse alveolar damage with pulmonary hemorrhage and invasive *Aspergillosis* (single focus)
- Left ventricular hypertrophy.

OPEN HOUSE DISCUSSION

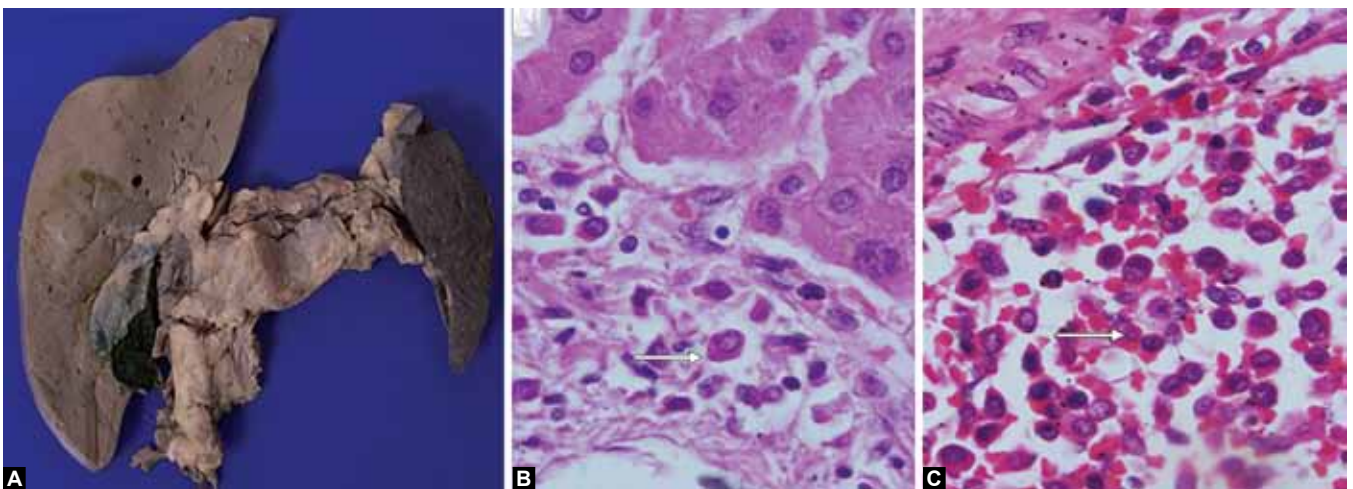
- *SR*: Before autopsy, an important differential diagnosis was differentiation syndrome (DS). Does the



Figs 2A to C: Postmortem bone marrow biopsy: (A) Hypercellular marrow spaces (10×), (B) myeloid hyperplasia with extensive proliferation of promyelocytes (20×) and (C) strong positivity with MPO (20×)



Figs 3A to F: (A) Cut surface of the lung which is firm and shows hemorrhages, (B) microphotograph showing diffuse alveolar hemorrhage (10x), (C) hyaline membrane formation with edema (40x), (D) focus of angioinvasive fungal infection wherein you see hyphae clogging the vessel and permeating into the lung parenchyma (20x) and (E and F) alveolar septae show infiltration by promyelocytes, highlighted by IHC for MPO (100x)



Figs 4A to C: (A) Organ complex of the enlarged liver and spleen, (B) infiltration of promyelocytes in portal tract of liver (40x) and (C) infiltration of promyelocytes in splenic sinusoids (40x)

leukemic infiltrate in lungs qualify for that? What is the pathology of DS that happens after ATRA therapy? Can you differentiate it on autopsy or will you say that there are some leukemic infiltrate or promyelocytes?

- *Dr A Das:* I think making a diagnosis of DS at autopsy is always difficult. We should consider some negative findings. In the index case, there was extensive diffuse alveolar damage with pulmonary hemorrhage, this

would be against what we have seen in one or two cases of DS previously. Second thing is here most of the leukemic infiltrate is like promyelocytes and not differentiating cells in pulmonary capillaries. In DS, pulmonary capillaries are clogged with differentiating cells and a few interstitial cells does not fit in with a diagnosis of DS.

- *Dr Jain:* The issues are very complex, if there is a mixed pathology. Whether it is the disease or the complication of the disease, it can be difficult to prove.
- *Dr Verma:* Do we really know the pathology of DS, to an extent that we can differentiate it from other things? Basically, it is a cytokine release that occurs in patients who are given treatment and the cells start differentiating at a rapid pace. So, infiltration is not a major issue in these patients. The issue is the increase in the total leukocyte count in the peripheral blood, pulmonary infiltrates and most of these people will improve. I do not know if we know with certainty the pathology which occurs in these settings. It will be difficult for any one to comment, unless we are looking at cytokines. But they are also labile and increase in many situations. It is alright to think of DS in this patient as the symptoms started after starting the ATRA therapy. This patient did have coagulation abnormality and intra-alveolar hemorrhage could have occurred because of that. To my mind, the fungal infection occurred in the later part of the illness as there was only a single focus of disease. There were a combination of things that occurred in this patient including intra-alveolar hemorrhage, fungal infection and there was bacterial infection as well. *E. coli* was grown from the abscess and this focus could have led on to septicemia.
- *Dr A Chakrabarti:* This patient was on amphoterecin B for 3 to 4 days only. The morphology shown looks like fusarium which is resistant to amphoterecin B. There was a single focus of fungal infection and not a disseminated one.

COMMENTARY

All transretinoic acid (ATRA) or differentiation syndrome is a well-known complication of ATRA therapy, a drug that has revolutionized the treatment of acute promyelocytic leukemia. About 25% patients with APLM undergoing induction therapy develop the differentiation syndrome.¹ It develops within 2 to 47 days of starting therapy and is preceded by increasing white blood cell counts in most patients. First described by Frankel et al,² this is the main life-threatening complication of therapy with differentiating agents all trans retinoid acid or arsenic trioxide (ATO). It is characterized by

unexplained fever, acute respiratory distress with interstitial pulmonary infiltrates, and/or a vascular capillary leak syndrome leading to acute renal failure. The diagnosis of DS is essentially based on clinical and radiological features and requires the exclusion of alternative causes that could explain the signs and symptoms of the syndrome. According to Frankel et al², the diagnosis of definitely present DS is established by the presence of at least three of the following signs: weight gain, respiratory distress, unexplained fever, interstitial pulmonary infiltrates, pleural or pericardial effusions. The proposed mechanisms for the syndrome remains partially unknown. Cellular migration, endothelial activation, release of interleukins, and vascular factors along with 'cytokine storm' has been described.³ Postmortem examinations in APLM patients who have died with progressive hypoxemia and multiorgan failure show extensive infiltration of maturing myeloid cells into lung, skin, kidney, liver and lymph nodes.⁴ Also, presence of precursors clogging the microvasculature is noted. In the lungs, mild to prominent intra-alveolar myeloid infiltrate has been seen.⁵ Additional findings like intra-alveolar edema, interalveolar hemorrhage, fibrinous exudates⁶ and small vessel inflammation⁷ have also been reported infrequently. Identification of cause of diffuse pulmonary hemorrhage and ruling out differentiation/ATRA syndrome remains a challenge.

The index case was diagnosed as APLM and developed respiratory distress on the 7th day of therapy with ATRA. Parallel problems, including perianal abscess and sepsis, were present in this patient. There was no evidence of weight gain, edemas, pleural, pericardial effusions or increase in white cell counts, but there was respiratory distress, interstitial pulmonary infiltrates, and unexplained fever. Also, there was no improvement with dexamethasone after stopping ATRA. Differentiation syndrome was a strong possibility but was ruled out clinically due to the above said reasons. At autopsy presence of scant infiltration of liver, lung and spleen was seen. An absence of extensive infiltration and lack of differentiating cells clogging the smaller vessels negates a diagnosis of differentiation syndrome and suggests an alternative cause of respiratory distress in this case. Diffuse alveolar damage and alveolar hemorrhage seen at autopsy, secondary to septicemia or ATRA therapy per se, were the cause of respiratory distress which took away the patient.

REFERENCES

1. Montesinos P, Sanz MA. The differentiation syndrome in patients with acute promyelocytic leukemia: experience of the pethema group and review of the literature. *Mediterranean J Hematol Infec Dis* 2011;3(1):e2011059.

2. Frankel SR, Eardley A, Lauwers G, Weiss M, Warrell RP Jr. The retinoic acid syndrome in acute promyelocytic leukemia. *Ann Intern Med* 1992 Aug;117(4):292-296.
3. Luesink M, Pennings JL, Wissink WM, et al. Chemokine induction by all-trans retinoic acid and arsenic trioxide in acute promyelocytic leukemia: triggering the differentiation syndrome. *Blood* 2009 Dec 24;114(27):5512-5521.
4. Kakkar N, Dhameja N, Jasmina, Das A, Radotra BD, Varma S. ATRA syndrome with extensive organ infiltration. *Am J Hematol* 2002 Sep;71(1):62-64.
5. Tallman MS, Andersen JW, Schiffer CA, Appelbaum FR, Feusner JH, Ogden A, Shepherd L, Rowe JM, François C, Larson RS, et al. Clinical description of 44 patients with acute promyelocytic leukemia who developed the retinoic acid syndrome. *Blood* 2000 Jan 1;95(1):90-95.
6. Paydas S, Yavuz S, Disel U, Sahin B, Canbolat T, Tuncer I. Vasculitis associated with all trans retinoic acid in a case with acute promyelocytic leukemia. *Leuk Lymphoma* 2003 Mar;44(3):547-548.
7. Nicolls MR, Terada LS, Tuder RM, Prindiville SA, Schwarz MI. Diffuse alveolar hemorrhage with underlying pulmonary capillaritis in the retinoic acid syndrome. *Am J Respir Crit Care Med* 1998 Oct;158(4):1302-1305.

List of Conferences (2015)

Date	Conference name	National/ International	Department
22nd–23rd July, 2015	8th IJ Dewan Memorial Workshop 'Organ Talk: Time to take prevention'	National	Department of Anatomy
27th–29th August, 2015	Symposium-cum-workshop on Stem Cells in Basic and Clinical Research	National	Department of Translational and Regenerative Medicine
12th–13th September, 2015	PDSICON, 2015	National	Department of Nephrology
19th–20th September, 2015	CME of Chandigarh Orthopedics Society and PGI Alumni	National	Department of Orthopedics
18th October, 2015	29th Annual Update on Pulmonary Medicine (CME)	National	Department of Pulmonary Medicine
29th–31st October, 2015	Annual conference of Indian Academy of Otolaryngology—Head and Neck Surgery	National	Department of Otolaryngology (ENT)
20th–22nd November, 2015	DFSICON, 2015	International	Department of Endocrinology
26th–28th November, 2015	ACBICON, 2015	National	Department of Biochemistry
4th–6th December, 2015	ISRPTCON, 2015	International	Department of Pharmacology

CALL FOR PAPERS

Journal of Postgraduate Medicine Education and Research

The Official Journal of Postgraduate Institute of Medical Education and Research, Chandigarh, India

Editor-in-Chief
Mandeep S Dhillon

Frequency
Quarterly

The Journal of Postgraduate Medicine Education and Research (JPMER) welcomes authors, professors, research scholars to contribute their original works in forms of original research, review articles, case reports, book review and illuminate the pages with their universal ideas and fresh perspectives to make the journal synonymous to the entire research field.



[Submit Manuscript](#)

[Instructions to Author](#)

Benefits to Authors

- ✓ Easy and rapid paper publishing process
- ✓ Articles reviewed by National and International Reviewers
- ✓ Paper will be published online as well as in hard copy of the journal
- ✓ JPMER provides a hard copy of the issue to the first author
- ✓ Automated manuscript submission and tracking system
- ✓ Access to feature rich JPMER- Author Account (Lifetime)
- ✓ Open access journal for high visibility and to promote your research work
- ✓ JPMER is indexed in IndexCopernicus, Open J Gate, ProQuest and many more.

Features

- Platform to share knowledge in front of the world
- Encouraging research work in basic sciences and advanced techniques
- Platform to showcase your research to specialist review team
- Publication Charges: **FREE**



Please submit your manuscript through online submission platform "Scriptor's Zone" which is available on Journal's website: www.jpmer.com



For Queries: editor@jaypeebrothers.com | Phone: 011-49524952, 43574357