

# Computed Tomography: Its Importance in Treatment Planning for Implants

<sup>1</sup>Hariharan Annapoorni, <sup>2</sup>Durga Prasad Tadi

## ABSTRACT

Use of dental implants for the replacement of missing teeth has rapidly increased in the dental profession. To obtain long-term success of the dental implants, it is necessary that the implants be placed in the host site after thorough assessment of the site. Such an assessment can be done only by advanced imaging procedures, such as computed tomography (CT). An in-depth knowledge of interpretation of the imaging modality is necessary before treatment planning the situation. It is the aim of this paper to analyze different clinical situations in CT, the method of interpreting the same and comparing the interpretation with existing clinical situation. Also, in the process, it has been described how a clinician could go wrong when solely dependent on two-dimensional (2D) imaging modalities.

**Keywords:** Computed tomography, Implant, Bone quality, Bone quantity, Treatment planning.

**How to cite this article:** Annapoorni H, Tadi DP. Computed Tomography: Its Importance in Treatment Planning for Implants. *Int J Clin Implant Dent* 2015;1(1):1-7.

**Source of support:** Nil

**Conflict of interest:** None

## INTRODUCTION

The use of dental implants for the replacement of missing teeth has been increasing rapidly throughout the world.<sup>1-3</sup> Because of the increasingly important role of advanced imaging procedure in implant dentistry, it is necessary for the dental professionals to have adequate knowledge of interpretation of the imaging procedures for the assessment of the potential implant site. The success of the dental implant restoration depends on the adequate diagnostic information about bony structures of the oral region.<sup>4</sup> The purpose of this paper is to present the method by which a computed tomography (CT) is interpreted. The reader is taken through the interpretation by presentation of clinical cases that reported to our department.

<sup>1</sup>Professor and Head, <sup>2</sup>Postgraduate Student

<sup>1,2</sup>Department of Prosthodontics and Implantology, Meenakshi Ammal Dental College, Chennai, Tamil Nadu, India

**Corresponding Author:** Hariharan Annapoorni, Professor and Head, Department of Prosthodontics and Implantology, Meenakshi Ammal Dental College, Alapakkam Main Road, Maduravoyal Chennai, Tamil Nadu-600095, India, Phone: (+91) 9789023799 044-23781631, e-mail: hannapoorani@yahoo.co.in

## TOMOGRAPHY

Tomography is derived from Greek word 'tomo' which means slice and 'graph' means picture. This is a special X-ray technique which helps us to see clearly a section of the body's anatomy; by blurring the regions of the body anatomy above and below the section of interest. Tomography may be linear or complex. In linear tomography, the X-ray tube and the film move in a straight line whereas in a complex tomography or high-quality tomography, the motion is circular, spiral and hypocycloidal. Unlike linear tomography, complex tomography produce uniform blurring of the regions of the body anatomy. Dense structures, such as teeth, exostoses, thick cortical plate and restorations are difficult to blur effectively when they are much denser than the structures in the section of the area of interest. For dental implant patients, ideally, tomographic sections spaced 1 or 2 mm helps us to evaluate the implant site region. Normally, a magnification of 10 to 30% is produced with higher quality images. But higher the quality of image, higher is the magnification.<sup>5</sup> The quantity of bone available for implant placement is determined by compensating for the magnification. The quality of bone cannot be well-determined by complex tomography. With the aid of CT, it is possible to overcome this disadvantage.

## COMPUTED TOMOGRAPHY

Computed tomography is a digital and mathematical imaging technique that creates tomographic sections where the area of interest is not contaminated by blurred structures of the adjacent anatomy. The CT helps us to view hard and soft tissues on the image and differentiates them with precision. Computed tomography was invented by Sir Hounsfield. It produces a three-dimensional (3D) digital image of 512 × 512 pixels with a slice thickness determined by the imaging techniques. Computed tomography scanners are standardized at a Hounsfield unit or HFU value, '0' for water; thus, the CT density scale is quantitative. High-resolution CT helps in analyzing the implant site by providing image data in horizontal sections and cross sections. Current generation CT produces section thickness of 0.25 mm, thus providing diagnostic information that other imaging or combinations of imaging techniques cannot provide. Though the utility of

CT for dental implant treatment planning was evident from the 1970s, access to these imaging techniques was limited. Radiologist had to communicate with the doctor to discuss about the prospective surgery and then sit at the imaging computer to interpret the imaging results and then produce the hard copy of the same to send it to the referring doctor.

The limitations were very clear and this led to the development of dental scans. In a dental scan, the radiologist indicates the curvature of the mandible or maxilla, and the computer is programmed to generate cross-sectional or tangential images in 3D. Computed tomography aids in identifying the disease, determining bone quality and quantity, and position and orientation of the dental implants, thus satisfying all the objectives of preprosthetic imaging. To take full advantage of this technique and to incorporate 3D treatment plan, a diagnostic template is necessary.

The various designs of diagnostic templates are as follows:

- Simple vacuform reproduction of the waxed up restoration.
- The processed acrylic reproduction of the waxed-up restoration.
- Templates fabricated with radiopaque denture teeth.
- Processed acrylic template modified by coating the restoration with a thin film of barium sulphate and filling the drill hole through the occlusal surface of the restoration with gutta-percha.
- The vacuform portion of the proposed restoration is filled with a blend of 10% barium sulphate and 90% cold cure acrylic resin, resulting in the radiopaque tooth appearance of the proposed restoration in the CT. A hole may be drilled through the center for the use of twist drills. This procedure will result in a natural tooth-like appearance of the proposed restoration in the CT, in which all the surfaces of the restorations is evident along with the radiolucent channel through the restorations, which identifies the position and orientation of the proposed implant.<sup>6</sup>

## EVALUATION OF IMPLANT SITE USING CT

Computed tomography is a very useful imaging modality in planning the placement of dental implants in partially and fully edentulous arches. It aids in the placement of implants more accurately and safely.<sup>7,8</sup> This article is a practical tour that analyzes the effectiveness of CT in treatment planning of dental implants.

## CASE REPORTS

### Case 1

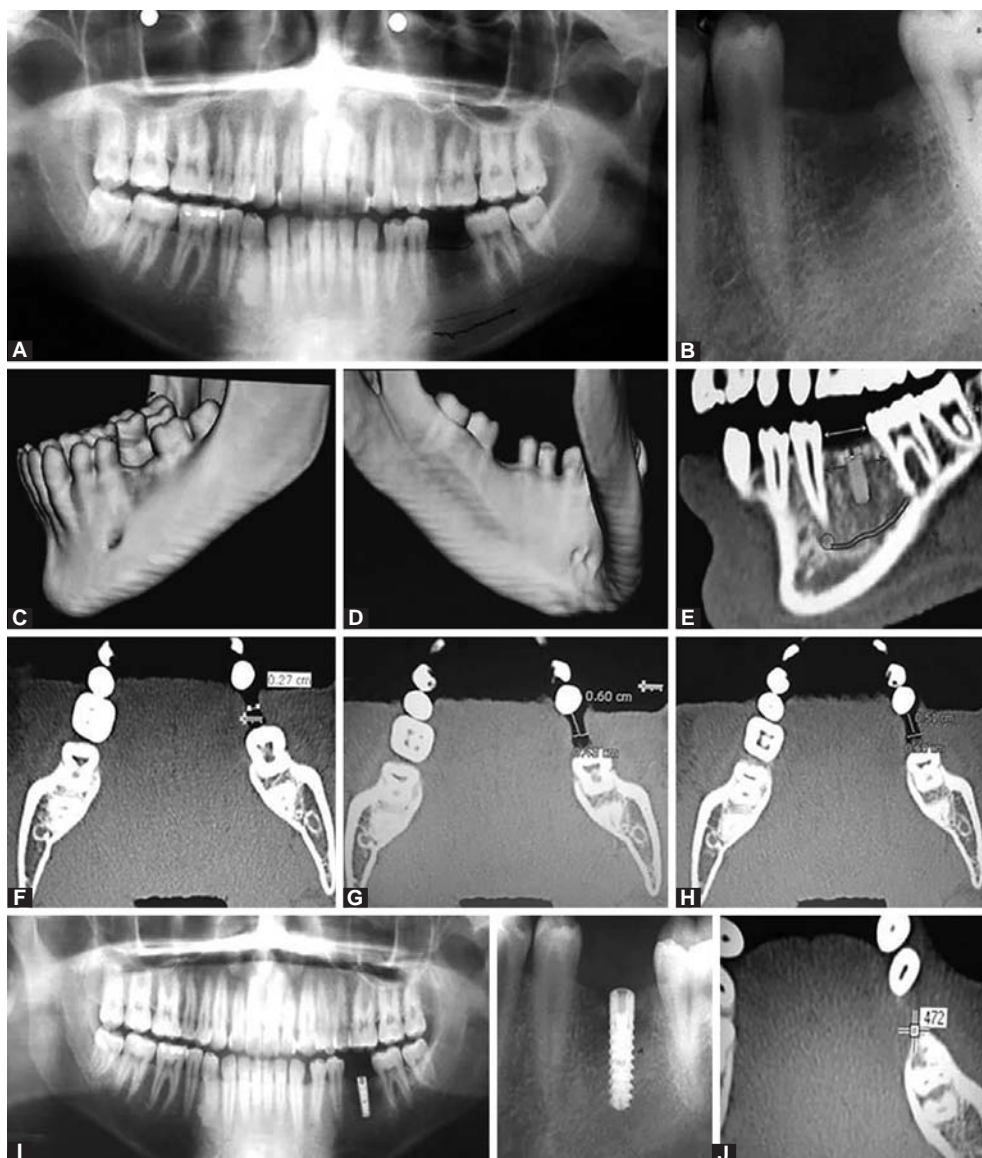
A 24-year-old male reported to the department for replacement of mandibular right first molar. He

underwent an extraction 1 year ago, as conservative treatment was not possible. The panoramic radiograph (Fig. 1A) of the patient seemed normal from every angle but for the rarefied socket region. Intraoral periapical radiograph (Fig. 1B) also revealed the similar appearance. A CT was scanned for the patient and a buccal concavity (Fig. 1C) was revealed. The lingual view of the mandible showed a gentle concavity on the crestal region (Fig. 1D). It was seen that the lingual and buccal concavity had compromised the crestal bone width of the bone exactly in the area of implant placement. This kind of a situation may require bone augmentation material. Thus, this investigation helped us to be prepared with the bone augmentation material and at the same time inform the patient about the additional cost.

The panoramic view (Fig. 1E) determines the intracoronar width and intraradicular width, and the proposed length of the implant as well. Computed tomography tools should be used to determine these parameters. In the central axial view using the CT tool, the width of the host site was determined to be 2.7 mm at the crest (Fig. 1F). As expected these values were phenomenally low because of the buccolingual defects present. The width is then determined for the first slice, (thickness 0.25 mm) this was found to be 4.3 mm (Fig. 1G). Evaluation at the second slice determined the width of 5.1 mm (Fig. 1H).

So, as a part of the treatment plan, it was decided to use a crestotome and slice the knife crest, and then go ahead with placement of dental implant. A 3.75 mm diameter implant (Pitt-easy) was placed successfully without augmentation (Fig. 1I).

Bone quality and quantity are two factors that are considered important in the consolidation of bone implant surface. These two factors also influence the surgical technique to a great extent.<sup>9-14</sup> Bone quantity is often understood in terms of height and width. But bone quality is a more comprehensive term without a more clear definition. It consists of several aspects of bone physiology, degree of mineralization and structural properties.<sup>15-17</sup> In a normal CT, the quality is determined based on the density, which is given to us in HU (Hounsfield units). This is mentioned on the film but can be viewed very easily on our computer. The dentist should ask the scan center for a CD along with a film, so as to enable us to work on our computer. Using the CT tools, determination of density of the host site at various sections on the axial view showed 0 at the crestal level. In the first slice of 0.25 mm, the density is 171 HU. In the second slice, the density is 472 HU (Fig. 1J). Correlating this with the width that was determined earlier, it can be said that in the region of the second slice the width is 5.1 mm and the density is 472 HU. In the region of the third slice, the density is 672 HU.<sup>18,19</sup> According to Lekholm and Zarb,



**Figs 1A to J:** (A) Orthopantomogram of patient case 1, (B) IOPA of case 1, (C) CT showing large buccal concavity. Extending from the crestal region to a short distance on the buccal slope, (D) CT showing gentle lingual concavity, (E) panoramic view of CT, (F) width at the crestal level is 2.7 mm, (G) width at first slice is 4.3 mm, (H) width at the second slice is 5.1 mm, (I) showing postoperative OPG and IOPA and (J) bone density at second slice is 472 HU

density values below +200 HU require meticulous surgical techniques. Intermediary values between +200 and +400 HU units represent conditions favorable for osseointegration (bone types 2 and 3) and values above +400 HU indicate denser bone (type 1), which has a greater risk of overheating during implant installation.

Therefore, if an implant is placed in the region of the second slice, more than 2/3rd of the implant will remain in abundant bone. Such a decision was made possible by the CT.


Apart from analyzing the defect, the quantity and quality of bone and the width of the implant, it is also possible to analyze the length and the angulation of the implant, using a CT. Thus, it is satisfying all the objectives of a good imaging modality. Therefore, it is wise to use CT for diagnosis and treatment planning for implants.

## Case 2

A 20-year-old male reported to the department for replacement of maxillary left and right central incisors. He lost his teeth following an accident and has been wearing a removable partial denture. Patient's panoramic radiograph (Fig. 2A) revealed normal situation.

Since, it was a trauma case, the patient was sent to CT with a template. A large defect was visible on the labial aspect of the maxillary right central incisor region, and smaller defect on maxillary left central incisor (Fig. 2B). The gutta-percha in the template shows the angulation of the implant (Fig. 2C).

Figures 2D and E show the cross-sectional view of the maxillary right and maxillary left central incisors with the template. Note that on the right side, if the angulation of the implant is decided according to the



**Figs 2A to H:** (A) Orthopantomogram of case 2, (B) preoperative CT large defects in the labial region. A large defect was visible on the labial aspect of the maxillary right central incisor region, and smaller defect on maxillary left central incisor, (C) CT template with gutta-percha, (D and E) proposed angulation of the implant, (F) implant and abutment in place, (G) postoperative CT and (H) final restorations

stent, then the implant cannot be placed because there is no bone. Therefore, it was decided to place the implants palatally (Nobel Biocare), without compromising on the final position of the restoration and then augmentation (Bio-Oss Spongiosa, Geistlich Pharma Ag, Switzerland and BioMend, absorbable collagen membrane, Zimmer) of the labial bone was done. The situation is similar on the left side. The implants were placed in the determined angulation (Fig. 2F). On correlating the preoperative (Fig. 2B) and postoperative CT (Fig. 2G) adequate bone deposition labially and angulation of implants without compromising the esthetics were clearly evident. The clinical picture following implant placement is depicted in Figure 2F following the final restoration which is depicted in Figure 2H.

### Case 3

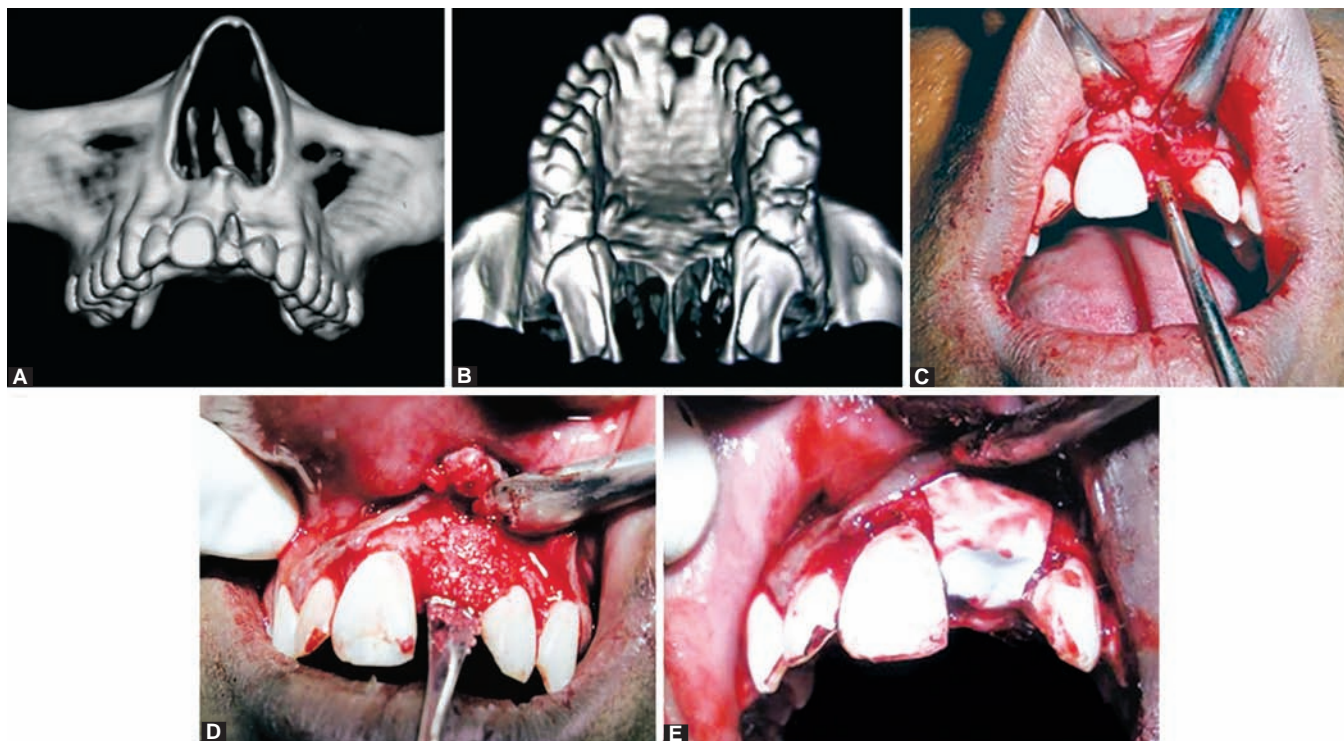
A 20-year-old male reported to the department with loss of maxillary left central incisor following a fall. Craniocaudal view of the CT clearly revealed a large

labial and a small palatal defects (Figs 3A and B). These defects have occurred along with the avulsion of the teeth and this can be visualized on the surgical site (Fig. 3C). Due to the large size of the defect, it was planned to augment the site first and then place an implant. Allograft was placed (Fig. 3D) followed by a membrane (Fig. 3E) (Bio-Oss Spongiosa, Geistlich Pharma Ag, Switzerland and BioMend, absorbable collagen membrane, Zimmer). The panoramic (Fig. 4A) and central axial views (Fig. 4B) clearly show radiolucency due to lack of bone prior to augmentation. The panoramic (Fig. 4C) and central axial views (Fig. 4D) show radiopacity following augmentation.

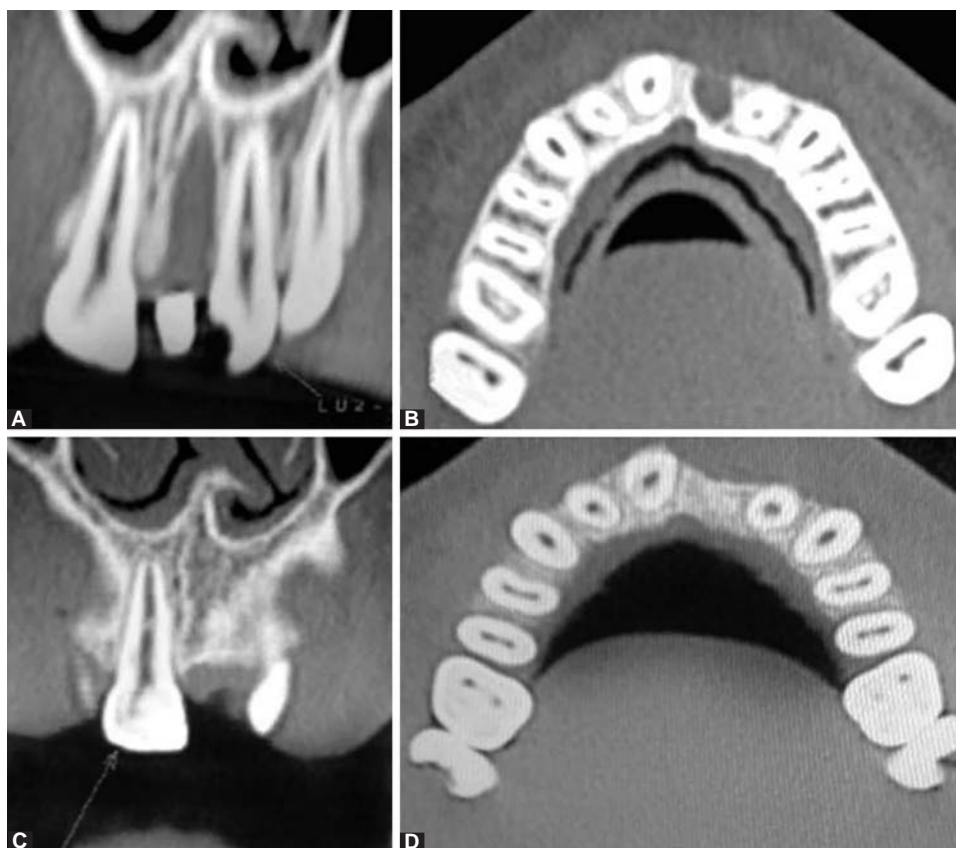
### TOOLS USED IN CT

On insertion of the CD into the computer, an image is displayed on the screen (Figs 5A and B). On the right side of the image, there are the tools. The tool can be carried to the site using mouse.





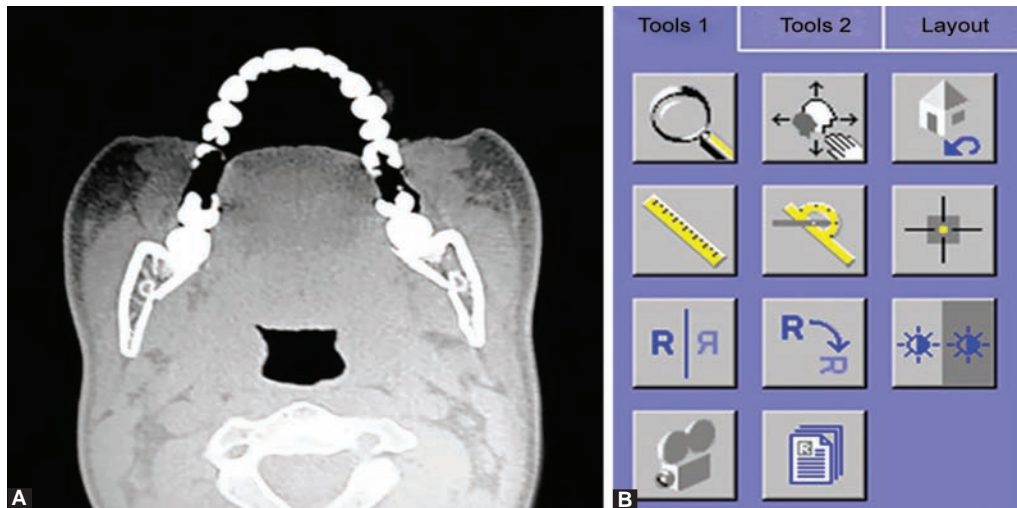
**Figs 3A to E:** (A) Craniocaudal view of the CT clearly revealed a large labial defect, (B) CT showing a small palatal defect, (C) labial defect on elevating flap, (D) graft in place and (E) membrane in place



**Figs 4A to D:** (A) Panoramic view clearly showing radiolucency in the host site before augmentation, (B) central axial view showing radiolucency before augmentation, (C) panoramic view clearly showing radiolucency in the host site after augmentation and (D) central axial view showing radiolucency after augmentation

The tool bar consists of a lens, which is a magnifying tool, which when carried to the desired site magnifies that area. Measuring scale, when extended from one

point to another, shows the distance between the two points in millimeters. Angle measurement tool, when dragged to the desired site, will depict the angulation of



**Figs 5A and B:** Appearance of the CT on the computer screen with the tools

the desired object. Pixel lens, when carried to the host site, automatically displays the density in HU. Drawing pencil (freehand) on selecting gives us the option of enhancing the anatomical landmarks on the CT for a greater clarity, and this will show us the proximity of the implants to vital structures.

### IS CT MANDATORY FOR IMPLANT PATIENTS?

The question is whether an extra information that is provided by CT imaging of the dental alveolus is necessary. Without any doubt, CT provides an extra level of confidence for the placement of the implant at the host site. This comes from the precise information provided to us by the different views of the CT. Hence, CT is mandatory to obtain site specific information.

Advantages of CT are that, a high-contrast image with a well-defined image layer free of blurring, a 3D reconstruction, simultaneous study of multiple implant sites, the availability of software for image analysis and ability to perform virtual surgery. Disadvantages include lack of understanding of the dentist's imaging needs by the radiologic technologists and medical radiologists who acquire and interpret the CT images, expensive, higher doses of radiation compared with conventional tomography.

### REFERENCES

1. Branemark PI, Adell R, Breine U, et al. Intra-osseous anchorage of dental prostheses: experimental studies. *Scand J Plast Reconstr Surg* 1969;3(2):81-100.
2. Adell R, Lekholm U, Rockler B, et al. A 15-year study of osseointegrated implants in the treatment of the edentulous jaw. *Int J Oral Surg* 1981;10(6):387-416.
3. Adell R, Eriksson B, Lekholm U, et al. Long-term follow-up study of osseointegrated implants in the treatment of totally

- edentulous jaws. *Int J Oral Maxillofac Implants* 1990;5(4): 347-359.
4. Benson BW. Presurgical radiographic planning for dental implants. *Oral Maxillofac Surg Clin North Am* 2001;13(4): 751-761.
5. White SC, Pharoah MJ. The evolution and application of dental maxillofacial imaging modalities. *Dent Clin N Am* 2008;52(4):689-705.
6. Christoph HJ Basten, Dent M, Kois JC. The use of barium sulfate for implant templates. *J Prosthet Dent* 1996;76(4): 451-454.
7. Schwarz MS, Rothmann SLG, Rhodes ML, Chafetz N. Computed tomography: preoperative assessment of the maxilla for endosseous implant surgery (Part II). *Int J Oral Maxillofac Implants* 1987;2(3):142-148.
8. Schwarz MS, Rothmann SL, Chafetz N, Rhodes M. Computed tomography in dental implantation surgery. *Dent Clin North Am* 1989;33(4):555-579.
9. Esposito M, Hirsch JM, Lekholm U, Thomsen P. Biological factors contributing to failures of osseointegrated oral implants (I). Success criteria and epidemiology. *Eur J Oral Sci* 1998;106(3):527-551.
10. Friberg B, Jemt T, Lekholm U. Early failures in 4641 consecutively placed Branemark dental implants: a study from stage 1 surgery to the connection of completed prostheses. *Int J Oral Maxillofac Implants* 1991;6(2):142-146.
11. Hermann I, Lekholm U, Holm S, Kultje C. Evaluation of patient and implant characteristics as potential prognostic factors for oral implant failures. *Int J Oral Maxillofac Implants* 2005; 20(2):220-230.
12. Jaffin RA, Berman CL. The excessive loss of Branemark fixtures in type IV bone: A 5-year analysis. *J Periodontol* 1991;62(1):2-4.
13. Jemt T, Lekholm U. Implant treatment in edentulous maxillae A 5-year prospective multicenter follow-up report on patients with different degrees of jaw resorption. *Int J Oral Maxillofac Implants* 1995;10(3):303-311.
14. Shahlaie M, Gantes B, Schulz E, Riggs M, Crigger M. Bone density assessments of dental implant sites: Quantitative computed tomography (I). *Int J Oral Maxillofac Implants* 2003;18(2):224-231.

15. Ekfeldt A, Christiansson U, Ericksson T, Linden U, L ndqvist S, et al. A retrospective analysis of factors associated with multiple implant failures in maxilla. *Clin Oral Implant Res* 2001;12(5):462-467.
16. Lindh C, Nilsson M, Klinge B, Petersson A. Quantitative computed tomography of trabecular bone in the mandible. *Dentomaxillofac Radiol* 1996;25(3):146-150.
17. Lindh C, Petersson A, Klinge B, Nilsson M. Trabecular bone volume and bone mineral density in the mandible. *Dentomaxillofac Radiol* 1997;26(2):101-106.
18. Lindh C, Obrant K, Petersson A. Maxillary bone mineral density and its relationship to the bone mineral density of the lumbar spine and hip. *Oral Surg Oral Med Oral Pathol Oral Radiol Endod* 2004;98(1):102-109.
19. C ndido R, de Oliveira G, Leles CR, Normanha LM, Ribeiro-Rotta RE, Goi nia, Goi as, Brazil, Malm . Assessments of trabecular bone density at implant sites on CT images. *Oral Surg Oral Med Oral Pathol Oral Radiol Endod* 2008;105(2): 231-238.