10.5005/jp-journals-10040-1010

REVIEW ARTICLE

Total Ankle Arthroplasty: Why does It fail?

Hajo Thermann

ABSTRACT

Over the past 10 years, total ankle arthroplasty (TAA) has been established as an alternative to treat osteoarthritis of the ankle. In this review, problems occurring after TAA will be analyzed and solutions presented. Furthermore, my own 18 years experience regarding the failure or poor success of a TAA implantation will be illustrated. The range of revision options from leaving the prosthesis to a complete modification as well as the explantation with subsequent arthrodesis will be presented algorithmically. Another problem of the poor success of prosthetic implants exists in the flat learning curve resulting from the surgeons' lack of routine coupled with the difficult pathology with deformity and stiffness of the ankle.

Keywords: Total ankle replacement, Malposition of ankle replacement, Revision.

How to cite this article: Thermann H. Total Ankle Arthroplasty: Why does It fail? J Foot Ankle Surg (Asia-Pacific) 2014;1(2):41-47.

Source of support: Nil

Conflict of interest: None

INTRODUCTION

Total ankle arthroplasty (TAA) has become more prevalent in the last 10 years and is regarded as a reputable alternative to treat osteoarthritis of the ankle. The reasons for the increasing indication and shifting of the patient toward TAA are clearly seen through better mobility since the meta-analyses in terms of pain and complications have not yet produced any advantages to TAA.[1,2] Meta-analyses of TAA as reported by the Swedish Ankle Arthroplasty Register in a data collection of 531 operations between 1993 and 2005, mainly from three hospitals, revealed a survival rate of 78% (CI: 74-82%). The first 30 cases had poorer performance than those of the subsequent cases (86%).[3] The Norwegian Ankle Arthroplasty Register from 1994 to 2005 showed 257 cases with a 5-year survival rate of 98% and a 10 years interval of 76%.[4]

In a meta-analysis by Haddad et al[5], similar survival rates can be seen between ankle replacements and ankle fusions. It is striking that the TAA has a larger proportion of 'major revisions' (7%), whereby loosening at 28% is the largest component within this group. After ankle arthrodesis, pseudarthrosis (65%) was primarily responsible for the revisions (9%).

The published problems of TAA experiences in the United States with numerous failures of the Agility prosthesis are particularly evident during infection. A series of uncontrollable infections with lower leg amputations are reported.[6-8] Overall, the numbers are bleak but the alternative of ankle arthrodesis does not show any better results either. It should be noted nevertheless that the frequency of performed arthrodesis compared to ankle prosthetics is significantly higher.[9-11] Key data publications indicate a factor of 10:1 (4800/480 patients) as the ratio of fusion/TAA.[11] The lack of routine of at least one operation per week or every 2 weeks is without question still a decisive factor for failure and complications in TAA. A review of the literature shows only a few cases of a visible learning curve in the studies.[12-14] After all, results in the comparison of two consecutively operated patient clienteles reveal that the second group has achieved improvements in the prevention of errors. However, there are also some errors, such as fractures of the malleoli and component malpositioning in the second group.[13] If we enumerate the problems of TAA, they would include pain, stiffness and lack of mobility, implant failure and the worst-case scenario: infection.

If one has the pain after TAA, we often find it in the medial, anterior-medial and postero-medial (malleolus) area and less frequently in the syndesmosis and lateral area. Several questions need to be discussed here. The issue of the incorrect position of the implants, the question of the sufficiency of 'resurfings of arthrotically modified joints (medial gutter and lateral gutter),' unbalanced insertion of the device with tension profiles in the described or anatomical area, 'overstuffing' of the tibial or even talar components, excessive load profiles of the patients by regained mobility (carrying loads, sports activities). The stiffness primarily affects dorsiflexion, particularly in cases in which the device was implanted after rigid post-traumatic osteoarthritis. Overall, the following premises are to be observed directly for the indication and implantation as well as for the clarification of the patient: a preoperative stiff joint will never reach normal mobility. It is a fact that traditional approaches and techniques can only achieve mobility similar to a healthy ankle after TAA. The stiffness in dorsiflexion as

Surgeon

Department of Orthopedic Surgery, Center for Hip, Knee and Foot Surgery, Sports Traumatology, ATOS Clinic, Germany

Corresponding Author: Hajo Thermann, Surgeon, Department of Orthopedic Surgery, Center for Hip, Knee and Foot Surgery, Sports Traumatology, ATOS Clinic, Bismarckstr 9-15, 69115, Heidelberg, Germany, Phone: 00496221983190 e-mail: hajo.thermann@atos.de

well as in plantarflexion is often associated with 'overstuffing' of the implants, with contractures especially in the posterior portions, shortening of the Achilles tendon as well as anteriorly caused by adhesions of the extensor tendons.

A significant error in my view is 'overstuffing' of the prosthesis (the smaller of the possible components should always be used). The post-treatment profiles with the question of an earlier mobilization and splint must be re-evaluated to find out to what extent the noncemented prostheses can be mobilized earlier.

Complications and failures from prosthetic loosening relate to the individual tibial and talar components. It is rare for both components to be affected according to the literature. Instability is another problem. The causes are remaining instabilities medially (valgus deformities) or laterally (varus deformity), or the selection of polyethylene components which are too small. The malpositioning of the prostheses in the coronal and sagittal as well as traverse plane are of outstanding importance for the functional outcome. Malpositions of the components predominately lead to restrictions on mobility; at least in terms of a natural reaction of the tissue to cause the unbalanced pressure and load conditions. This is usually associated with pain. Since all patients have an extremely high pain level preoperatively, one must qualify the postoperative pain situation, so that patients often indicate that they are indeed in pain but the pain is acceptable. My personal experience over 18 years shows that no patient with implant malposition is absolutely pain-free. Of course, there should also be discussion as to whether freedom from pain can ever be reached in any case with the currently available nonanatomical, functional, biomechanical, 'incorrect' implants.

If one were to follow the advancement of TAA, significant progress would be seen in terms of instrumentation, repeatability and assistance in achieving an optimal implantation. However, there has not been any substantial change in the present design, which does not correspond to the anatomy and biomechanics of the ankle. However, we must point out that even in total knee arthroplasty, nonanatomical implants have ensured optimal functional results for decades.

ANALYSIS OF MALPOSITIONS

Proximally malpositioned implants lead to an elongation of the gastroc-soleus Achilles tendon complex. That causes a change in gait (push up) and a proximal migration of the talus accompanied by increased ligamentous tension, which decreases plantar flexion. There is often a medial and lateral impingement and an increased risk of dislocation of the talar components (Figs 1A and B). Distally malpositioned implants lead to shortening of the gastroc-soleus Achilles tendon complex. That causes increased bone resection in the talar region and a final implantation on the softer cancellous bone. The tension of the ligaments is reduced in dorsiflexion. Gait changes during the swing phase can be seen. The risk of component luxation is increased and possible polyethylene instability exists.

In varus malposition, we have a hindfoot inversion with increased stresses on the lateral structures and ligaments. We have significantly increased stresses on the poly-ethylene with impingement of the medial compartment, 'overload' in the area of the MT-V and the lateral column. Pain and instability exist in the region of the lateral ankle structures, ligaments and peroneal tendons along with significantly increased polyethylene wear (Fig. 2).

Valgus malposition of the ankle also leads to a valgus malposition of the hindfoot with increased stress on the medial ligaments (deltoid, spring ligament), increased stress on the polyethylene, impingement in the lateral

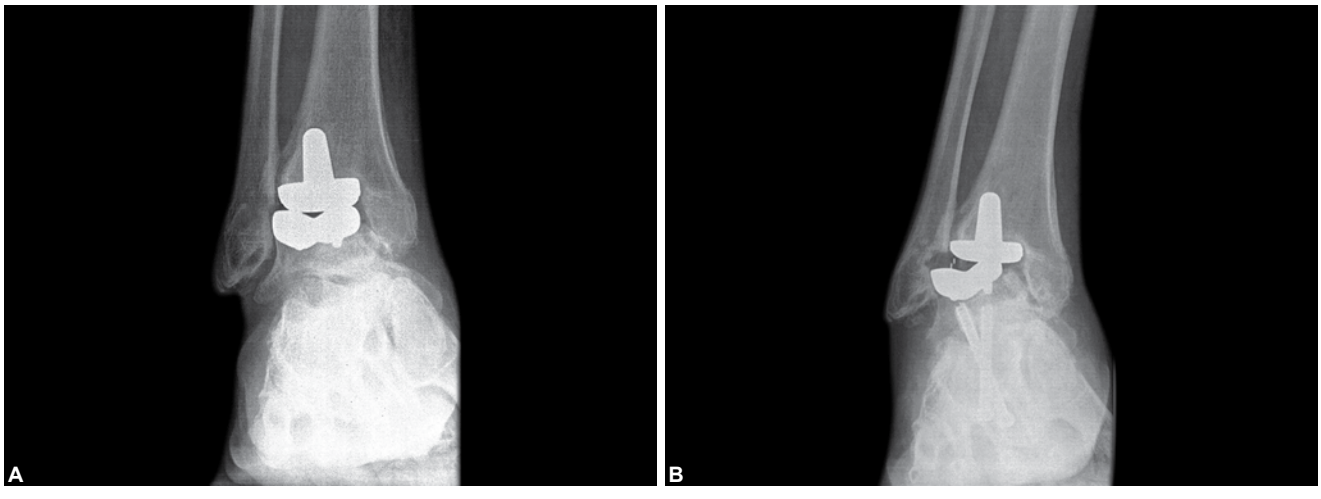

Figs 1A and B: Coronal plane of increasing varus deformity (A) with subluxation of the components despite a corrective subtalar fusion (B)

compartment, pronation deformity with increased wear in the polyethylene as well as pain in the region of the posterior tibial tendon and the medial ligaments as well as sometimes medial instability.

The anterior malposition primarily affects the talar component and leads to an anterior dislocation of the center of rotation of the talus in relation to the tibia axis with nonisometric stress of the polyethylene and the collateral ligaments. Dorsiflexion is reduced due to anterior impingement. It partially corresponds to an anterior 'tilting' of the tibial component as well as instability, luxation and loosening of the talar component (Fig. 3).

The posterior malposition leads consecutively to a malpositioned center of rotation. There are also non-isometric stresses on the polyethylene and the collateral ligaments with reduced plantar flexion, posterior tilting of the tibial components and loosening of the talar component (Fig. 4).

The medial malposition often leads to stress fractures in the medial malleolus region. In 'edge loading' of the talar component, an early cyst formation occurs from polyethylene wear and breakage up of the polyethylen. The same is true for lateral impingement leading to osteolysis and fibular fracture as well as valgus deformity.[15,16]

OVERSTUFFING

Certainly, overstuffing results from the surgeon's concern with resectioning as little bone as possible. For years, initial TAA implantation recommendations had always favored the larger component when presented with a choice between two components. However, this trend has now completely reversed. Overstuffing leads to constant, non-specific pain, often medially. Because of the reaction of tissue to the 'tightness', arthrofibrosis with stiffness of the joint most often follows (Fig. 5). When checking the alignment of the prosthesis, load stresses (sagittal, dorsoplantar and hindfoot axis) are to be examined as well as problems in terms of pain regarding whole leg load stress. This requires examining the alignment of the ankle prosthesis throughout the entire leg axis.

Fig. 2: Coronal plane of varus implantation of the prosthesis

Fig. 3: Sagittal plane of anterior malalignment of the talar component

Fig. 4: Sagittal plane of posterior malalignment of the talar component

Fig. 5: Coronal plane of medial 'overstuffing'

OSTEOPHYTES

Other causes of pain and stiffness are osteophyte formations, which occur frequently in the posterior portion of the tibial plafond as support reactions. With regard to that, length of the posterior tibial component is important. It should be longer than the posterior 'cortex' in order to prevent overgrowth. This is taken into account in the 'newer design'.

The influence of small 'sawdust' with inadequate irrigation during implantation as well as the resection of the capsule in the posterior compartment must be considered at this stage. Incorrect implantation of the tibial component in the sagittal plane, which is often dorsally extended does not allow for optimal prosthesis incorporation in the bone. Therefore, osteolysis in the tibial plafond can often be found. The problem of osteophyte overgrowth is also relevant for post-traumatic changes in particular because complete removal of the existing osteophyte changes in the posterior as well as medial and lateral joint section is not successful despite the time-consuming operation.

FATIGUE FRACTURES

Overstuffing is not the only cause of fatigue fractures. Another problem, especially in the medial malleolus region, is an injury during the cutting of the tibial 'cuts' of the medial cortex which, combined with stretching of medial structures due to the correction of the varus deformity, leads to increased stress on the weakened medial malleolus. These types of fractures usually occur within 4 to 6 months with forced load and increased activity. In my opinion, large cystic changes in the malleolar area within a year are caused by resorption and not by polyethylene wear. Because of injury of the cortex in the fibular and medial malleolus regions, synovial fluids cause a 'wash out' of cancellous bone. A bone graft can easily repair this. PEs from the cystic tissue in our testing have failed to show any polyethylene wear. Therefore, this type of cyst formation is easy to handle (Fig. 6). Painful posterior osteophytes and arthrofibrosis with medial osteophytes can be debrided arthroscopically with the appropriate amount of expertise. However, one should have a great deal of posterior endoscopic experience in particular because the considerable adhesions place great technical demands.

LOOSENING OF THE PROSTHESIS

The principles for revision arthroplasty in the case of a loosening of the prosthesis are usually indicated by dysbalances with malpositioned tibial and talar components which increase with increased strain and lead to a loosening causing considerable pain. One basic prerequisite for revision arthroplasty is absolute agreement of the patient that(s) he would like another endoprosthetic implant and under no circumstances accept a fusion. In principle, the surgeon should be capable to clearly analyze the mechanism, which has led to an increased malpositioning and to a loosening of the prosthesis. Furthermore, the surgeon, on the basis of experience and surgical abilities must understand how to carry out revision surgery in order to provide a definitive solution to the problem. In this regard, osteotomies (supramallelar, hindfoot, and medial malleolus) should also be considered. Soft tissue release, M. tibialis post, Achilles tendon, medial deltoid ligament should be taken into consideration.[16]

Doubtless at this point in time that at least with suspected low grade infection (loosening of two components without clear evidence of the cause) changing to a fusion is the solution to the problem. In this case, one must take into consideration that following the removal of the prosthesis and debridement, significant bone defect occurs. Following resection these defects in the components may amount to 1.5 to 3.5 cm. Stabilization of such bone defects through arthrodesis is doubtless not comparable with an 'index operation'—an arthrodesis in the case of osteoarthritis.[8,17]

In exchanging talar components, a reliable revision is possible especially from a supplier of flat-cut prostheses, which has a spread corrective profile. The aim is to restore the joint lines to through resurfacing of the talus, which is technically relatively simple and provides a stable situation. From my experience and in the experience of other European protagonists a hybrid implant is suitable, i.e. changing of the talar components and 'leaving' the tibial components of various suppliers (provided these are not loose!) since generally the flat tibial components are compatible with various talar components with corresponding sliding core (Figs 7A to C).

Fig. 6: Coronal plane of a stress fracture in a young active patient 3 months after implantation

The issue of low-grade infections is always extremely difficult to treat as it is normally very difficult to diagnose the pathogen. Although it has always been denied and scientific evidence is lacking, I believe that a part of the low-grade infection with a recognizable pathogen may be an allergic reaction to the implant.

All in all the porous coated prostheses show very good acceptance behavior whereby the individual and incomplete incorporation in spite of optimal technology, is not always fatefully essential.

Increasing osteolysis should be regarded as loosening. In relation to the impairment of wound healing in the area of the anterior wound or in the area of wound closures after lengthening of the Achilles tendon, low-grade infection must always be taken into consideration. Osteolysis without significant loss of function is a significant problem. Here, decision should be taken on a case-by-case basis. If the patient has good and relatively painless function, short time check ups over a period of months are fine enough in order that a relatively painless situation does not place one under time pressure. Usually, marked osteolysis often leads to an arthrodesis in the revision operation.[15,18]

CONCEPT FOR FUSION FOLLOWING TOTAL ANKLE ARTHROPLASTY

Aseptic loosening with little loss of bone stock, good bone quality, no talar necrosis, no symptomatic subtalar arthritis. In this case, the ankle should be fused with a large structural bone graft. I consider fusion with screws and anterior plate with a large structural bone graft as adequate. The corticospongiotic bone graft and the cancellous bone should be taken from the back of the iliac crest in order to rabbet a large pressfit graft. In this case, screw fixation or a anterior 'arthrodesis plate' can be used.

Aseptic fusions with major bone defects, poor bone quality (talus necrosis), symptomatic subtalar arthritis: fusion with a large corticospongiotic bone block, evtl. with using an allograft (femoral head mixed with bone marrow and possibly blood platelet associated growth factors and autologous cancellous bone). This should be fixed by means of a 'hindfoot arthrodesis nail'. In such situations, the subtaler joint cannot be saved even in the case of little discomfort in the subtalar joint[19] (Figs 8A to C).

Fusion resulting from septic TAA with low level bone defect and a good soft tissue layer, no subtalar

Figs 7A to C: Computed tomography coronal plane of tibial overstuffing: (A) X-ray coronal, (B) sagittal plane and (C) after revision of the tibial component (flat cut)

Figs 8A to C: Sagittal plane of loosening of the prosthesis after 8 years with subtalar arthritis (A) sagittal, (B) coronal plane, (C) of hindfoot fusion with A3© nail (Small Bone Innovations, Morrisville) and allograft (femoral head)

joint infection: the implant should be removed, a Palacos Spacer implanted and the ankle fixed by external fixation. Arthrodesis can be perfomed when the soft tissue is in good condition, without a major cortico-spongiosal bone graft, partially by shortening using a screw fixation, and potentially also with one of the 'newer' anterior arthrodesis plates.

Fusion following septic TAA with large scale bone loss, soft-tissue necrosis, poor soft-tissue coverage, purulent infection (also pertaining to the subtalar joint): removal of the implant, Palacos Spacer, external fixation and sequential debridement, possible VacuSeal® if a minor defect is present. Further treatment: 'free flap' to stabilize the soft tissue layer, following the stabilization of the soft tissue, retrograde hindfoot nail, potentially with cancellous bone in very clean conditions. In such situations, one should consider applying an Ilizarov-fixation and carrying out a proximal lenghtening (larger defects), to minimize shortening.

SUMMARY AND CONCLUSION

To summarize, it can be said that the main problem in TAA at this point in time is still the broad lack of and low levels of surgical expertise, in comparison with knee and hip arthroplasty. This is due to a low incidence rate and also possibly to the high degree of technical difficulty associated with this highly complex joint and the multiple pathologies of the foot and ankle joint. The proposed treatment plan must, necessarily, depend primarily on the surgeon's level of expertise. One of the foremost experts in TAA, Peter Wood, has not used TAA for a number of years in cases of malaligned joints, which is documented in the successful outcomes reported during his follow-up examinations.[20]

The instruments used in TAA have been improved for the user but the potential for mistakes is still considerable. A radiological examination of the primary bone cuts at the tibia, as well as at the talus, in the anteroposterior and lateral plane should be obligatory. A decisive factor here is the alignment of the rotation centre of the talus to the tibial axis. In my opinion, this provides the direction for the continued functioning and the success of an ankle joint prosthesis. It is here that manufacturers should be improving instruments more intensively so that serious mistakes in the alignment of the talar to the tibial components can be avoided. The review of TAA clearly shows that technical mistakes lead to early failure

at comparatively greater levels than are found in both hip and knee arthroplasty. This raises the question as to when a surgeon can perform which operations independently and what support does he need to perform the procedure to an optimal level. This is where each surgeon must critically assess whether their own learning curve, knowledge and experience of TAA and of the relevant prosthesis for the case in question is sufficient to provide the patient with a successful outcome. These are the lessons from my own learning curve!

Revision TAA operations relating to the complete replacement of components have only been documented anecdotally, without clear scientific statements or concepts. Based on the personal accounts of leading experts for prosthetic implants and on the statistics, there are, similarly, no clear treatment algorithms. Fusion following TAA has also, in most cases, nothing to do with the fusion, which was initially carried out. On this basis, the discussion of an arthrodesis as a completely successful operation following a loosened ankle joint prosthesis is, per se, not sufficiently scientifically supported. Based on personal experience and on the statistics, a clear analysis of the factors, which lead to the failure of prostheses, needs to be conducted. Where there is an aseptic loosening with manageable, clearly defined treatment possibilities, the prosthesis, in the form of revision prosthesis should be left in place and the appropriate supports provided for the patient. In such cases, less experienced surgeons should, at this point, refer patients to experienced endoprosthetic surgeons, at least for analysis and consultation.

REFERENCES

1. Hintermann B, Valderrabano V, Knupp M, Horisberger M. The hintegra ankle: short-and mid-term results. Orthopade 2006 May;35(5):533-545.
2. Karantana A, Hobson S, Dhar S. The scandinavian total ankle replacement: survivorship at 5 and 8 years comparable to other series. Clin Orthop Relat Res 2010 Apr;468(4):951-957.
3. Henricson A, Skoog A, Carlsson A. The swedish ankle arthroplasty register: an analysis of 531 arthroplasties between 1993 and 2005. Acta Orthop 2007 Oct;78(5):569-574.
4. Fevang BT, Lie SA, Havelin LI, Brun JG, Skredderstuen A, Furnes O. 257 ankle arthroplasties performed in Norway between 1994 and 2005. Acta Orthop 2007 Oct;78(5):575-583.
5. Haddad SL, Coetzee JC, Estok R, Fahrbach K, Banel D, Nalysnyk L. Intermediate and long-term outcomes of total ankle arthroplasty and ankle arthrodesis: a systematic review of the literature. J Bone Joint Surg Am 2007 Sep;89(9): 1899-1905.
6. Kotnis R, Pasapula C, Anwar F, Cooke PH, Sharp RJ. The management of failed ankle replacement. J Bone Joint Surg Br 2006 Aug;88(8):1039-1047.
7. Spirt AA, Assal M, Hansen ST Jr. Complications and failure after total ankle arthroplasty. J Bone Joint Surg Am 2004 Jun; 86-A(6):1172-1178.
8. Vaupel Z, Baker EA, Baker KC, Kurdziel MD, Fortin PT. Analysis of retrieved agility total ankle arthroplasty systems. Foot Ankle Int 2009 Sep;30(9):815-823.
9. Coester LM, Saltzman CL, Leupold J, Pontarelli W. Long-term results following ankle arthrodesis for post-traumatic arthritis. J Bone Joint Surg Am 2001 Feb;83-A(2):219-228.
10. Fuchs S, Sandmann C, Skwara A, Chylarecki C. Quality of life 20 years after arthrodesis of the ankle: a study of adjacent joints. J Bone Joint Surg Br 2003 Sep;85(7):994-998.
11. SooHoo NF, Zingmond DS, Ko CY. Comparison of reoperation rates following ankle arthrodesis and total ankle arthroplasty. J Bone Joint Surg Am 2007 Oct;89(10):2143-2149.
12. Carlsson A. Single- and double-coated star total ankle replacements: a clinical and radiographic follow-up study of 109 cases. Orthopade 2006 May;35(5):527-532.
13. Lee KB, Cho SG, Hur CI, Yoon TR. Perioperative complications of hintegra total ankle replacement: our initial 50 cases. Foot Ankle Int 2008 Oct;29(10):978-984.
14. Saltzman CL, Amendola A, Anderson R, Coetzee JC, Gall RJ, Haddad SL, et al. Surgeon training and complications in total ankle arthroplasty. Foot Ankle Int 2003 Jun;24(6):514-518.
15. Hintermann B. Endoprothetik des Sprunggelenks-Historischer Überblick, aktuelle Therapiekonzepte und Entwicklungen. Wien: Springer; 2005.
16. Thermann H. Neue Techniken-Fußchirurgie. Darmstadt: Steinkopf; 2004.
17. Hansen ST. Appropriate ankle arthrodesis technique to allow revision to total ankle arthroplasty: an editorial comment. Oper Orthop Traumatol 2005 Oct;17(4-5):563-568.
18. Harris NJ, Brooke BT, Sturdee S. A wear debris cyst following STAR total ankle replacement-surgical management. Foot Ankle Surg 2009;15(1):43-45.
19. Schill S. Ankle arthrodesis with interposition graft as a salvage procedure after failed total ankle replacement. Oper Orthop Traumatol 2007 Dec;19(5-6):547-560.
20. Wood PL, Sutton C, Mishra V, Suneja R. A randomised, controlled trial of two mobile-bearing total ankle replacements. J Bone Joint Surg Br 2009 Jan;91(1):69-74.