CASE REPORT

Multiple Odontogenic Keratocysts

[1]Shivayogi Charantimath, [2]Zameera, [3]Anjana Bagewadi, [3]Vaishali Keluskar

[1]Senior Lecturer, Department of Oral Medicine, Diagnosis and Radiology, KLES's Vishwanath Katti Institute of Dental Sciences Belgaum, Karnataka, India

[2]Reader, Department of Oral Medicine and Radiology, KLES's Vishwanath Katti Institute of Dental Sciences, Belgaum, Karnataka India

[3]Professor, Department of Oral Medicine and Radiology, KLES's Vishwanath Katti Institute of Dental Sciences, Belgaum Karnataka, India

Correspondence: Shivayogi Charantimath, Senior Lecturer, Department of Oral Medicine, Diagnosis and Radiology, KLES's Vishwanath Katti Institute of Dental Sciences, Belgaum, Karnataka, India, e-mail: yogi031_shiv@rediffmail.com

Abstract

Odontogenic keratocyst is a cyst of odontogenic origin that exhibits a keratinized epithelial lining. Odontogenic keratocyst has been the topic of numerous investigators and is known for its potentially aggressive behavior and significant rate of recurrences.[1]

OKC cyst often occurs as a solitary lesion at the angle of the mandible, however in some instances, multiple such cysts may occur in association with a syndrome called "Nevoid basal cell syndrome".[1]

These patients have propensity to develop multiple neoplasm including basal cell carcinoma and medulloblastoma. Hence early diagnosis and treatment is of utmost importance in reducing the severity of long-term sequelae of this syndrome. Here we present a case of multiple odontogenic keratocysts with nevi and narrowed ribs which has profound relevance to specialist in Oral Medicine and Radiology and Oral and Maxillofacial Surgery.

Keywords: Odontogenic keratocyst, basal cell carcinoma, nevi, syndrome.

INTRODUCTION

The term odontogenic keratocyst was introduced by the oral pathologists in Europe in mid-1950's, to denote a cyst with specific histological features and clinical behavior. In earlier literature, the keratocyst was described as a cholesteatoma and MicKulicz in 1876, described it as a dermoid cyst.[1,2]

Odontogenic keratocyst has a keratinized lining and the cyst arises from the cell-rests of the dental lamina (i.e., dental primordium) rather than from the reduced enamel epithelium or the cell rests of Malassez. Evidence suggest a genetic predisposition to formation of odontogenic keratocyst due to its association with nevoid basal cell syndrome. There might be a hereditary embryological maldevelopment in these patients, which predisposes them to the development of new cysts or recurrence.[4,12]

Odontogenic keratocyst may occur at any age and rarely occurs below 10 years of age peak incidence is in 2nd and 3rd decade, of life. Mandible is more affected than maxilla and is common in the ramus-third molar area followed by anterior mandible. In the maxilla the most common site is the third molar followed by canine region. The associated symptoms include pain and soft tissue swelling.[7]

Common features are its affinity for posterior mandibular location, thinness of the lining epithelium, expansion within the medullary spaces thus preventing bony perforation, propensity for recurrence which may occur as late as 10 years following surgical treatment, which suggests a lack of correlation between treatment modality and recurrence.

Multiple odontogenic keratocysts are associated with syndromes such as Basal Cell Nevoid Syndrome usually in patient's younger than 10 years of age.

PATHOPHYSIOLOGY

Gorlin syndrome is a hereditary condition transmitted by an autosomal dominant mode of inheritance. The causative gene is located on chromosome 9q (22.3-q31). Incidence is 1 in 50,000 to 150,000 which could vary by region.[2]

Studies on genetics of Gorlin syndrome have lead to important basic discoveries on developmental biology. Patients with Gorlin syndrome have a germline defect in DNA sequence of 1 of 2 gene sepsis of tumor suppressive gene.[3]

DNA analysis from patients with Gorlin syndrome has shown that the gene is homologous to sequence in fruit fly dorsophilia called the segment polarity gene or patched gene. PTCH is a tumor suppressor gene located at 9q 22.31. The patched gene is known to be important in developmental abnormalities growth regulation and segmentation in fruit fly dorsophilia.[4]

Basal cell carcinomas from patients, with Gorlin syndrome have abnormalities of the patched sequence gene suggesting a potential role of this gene as a tumor supressor gene.[4]

In dorsophilia, the patched gene functions as a components of the Hedgehog signaling pathway. Hedgehog is a diffusible protein that binds to and inhibits PTCH. In NBCC the Sonce Hedgehog signaling pathway is expressed during early murine tooth development. There is evidence that mutations in PTCH account for the development of odontogenic keratocyst.[5]

One of the challenges of Gorlin syndrome is diagnosing patients where most of them commonly present in 3rd to 4th decade of life with either dental cysts or basal cell carcinoma. In a significant percentage of patients the syndrome is probably never diagnosed.

Diagnostic Criteria for Gorlin Syndrome[6]

Diagnostic criteria is given by Evans et al. These criteria were modified by Komones et al in 1997. Gorlin syndrome can be established when two major or one minor criteria are present.

Major Criteria

1. More than two basal cell carcinomas or one BCC under the age of 20 years.
2. Histologically proven odontogenic keratocyst of the jaws.
3. Three or more cutaneous palmar or plantar pits.
4. Bifid, fused or markedly splayed ribs.
5. First degree relative with NBCCS.

Minor Criteria

Any one of the following features:

1. Proven macrocephaly after adjustment for height
2. One of several orofacial congenital malformation, cleft-lip or palate, frontal bossing, coarse face, moderate to severe hypertelorism.
3. After skeletal abnormalities, marked pectus deformity, marked syndactyly of the digits.
4. Radiological abnormalities, bridging of the sella turcia vertebral anomalies such as hemivertebra, fusion or elongation of the vertebral bodies modeling defects of hands and feet
5. Ovarian fibroma.
6. Medullobalstoma

CASE REPORT

A 21-year-old male patient reported to the OPD of Department of Oral Medicine and Diagnostic and Radiology, Institute of Dental Sciences, Belgaum with chief complaint of pain in upper right back region of jaw since 10 days (Fig. 1, Patient profile).

Fig. 1: Showing patient profile

Fig. 2: Pigmentation on flexor surface of right upper limb

Patient was moderately built and well-nourished with no history of chewing habits and nonsignificant medical and dental history.

General physical examination revealed a bluish black macular pigmentation measuring around 2 × 2 cm on flexor surface of right upper limb with hair growth and irregular border as shown in Figure 2 and similar pigmented area was seen on upper part of right back region as shown in Figure 3.

The pigmentation was noticed since two months and was gradually increasing in size suggesting a provisional diagnosis of nevi for the same. On intraoral examination a well-defined vestibular swelling measuring about 2 × 2 cm was observed extending from 14-15 region as shown in Figure 4 with inflammation of overlying mucosa.

The inspectory findings were confirmed on palpation. Swelling was firm in consistency tender, nonfluctuant and nonpulsative.

Further the patient was subjected for radiographic examination which revealed:

1. A well-defined periapical radiolucency measuring around 2 × 2 cm between right max 1st and 2nd premolar with divergent roots (Fig. 5).
2. An orthopantomogram revealed following features as shown in Figure 6:

Fig. 3: Pigmentation on upper part of right back region

Fig. 4: Intraoral swelling in 14 and 15 region

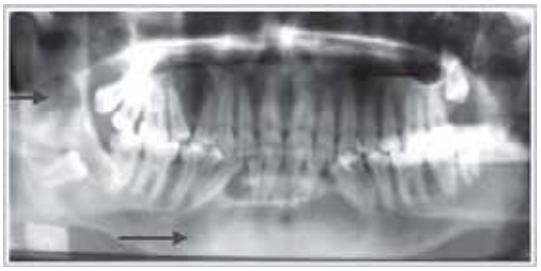

Fig. 5: Orthopantomogram shows radiolucency in 14 and 15, multi-locular radiolucency in relation to 33 and 43 region inferior displacement of 48

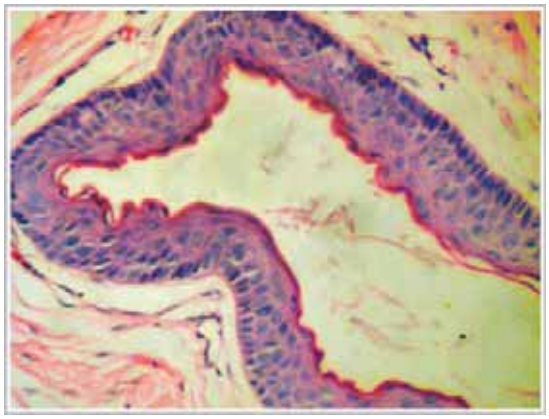

Fig. 6: Histopathological picture

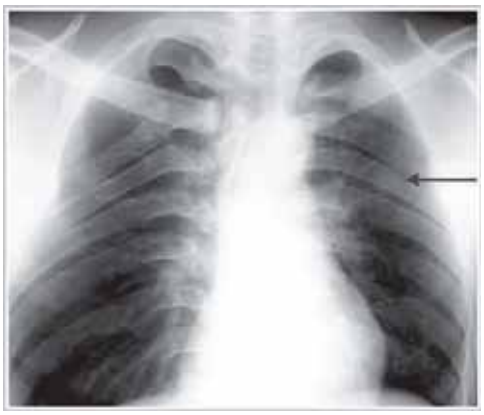

Fig. 7: Chest radiograph shows narrow ribs on right side and reduced inter rib distance on left 2nd and 3rd rib

- In relation to right ramus of mandible a well-defined unilocular radiolucency measuring around 4 × 5 cm in diameter extending from mesial root apex of 1st mandibular molar to ramus area with scalloped margin, well-defined cortication with inferior displacement of 48.
- In relation to mandibular anterior region, a well-defined multilocular radiolucency was seen extending from 33 to 43 region giving a soap bubble appearance.
- In relation to upper right maxilla a well-defined radiolucency was seen between 14 and 15 region with divergent root and impacted 28.

Observing the OPG findings a radiographic diagnosis of multiple odontogenic keratocysts was suggested.

The patient was subjected for incisional biopsy following the routine blood examination.

Histopathological report revealed stratified squamous parakeratinized epithelium with 4 to 6 cells layers without rete pegs, epithelium appeared to be detached from the underlying connective tissue. Basal cells showed corrugated keratin. Connective tissue showed bundles of collagen fibers with spindle shaped fibroblast and in the juxtaepithelium region stroma was loosely arranged. Few endothelial lined blood vessels with RBC were also seen. All the above features were suggestive of odontogenic keratocyst (Fig. 7).

Thus a final diagnosis of multiple odontogenic keratocyst was made.

Then the patient was subjected to chest radiography which revealed narrow ribs on right side and reduced inter rib distance on left 2nd and 3rd rib.

Finally based on clinical and radiographic findings a consistent diagnosis of Nevoid basal cell carcinoma syndrome was given.

DISCUSSION

Odontogenic keratocysts contribute up to 3.11% of all developmental odontogenic cysts and may be found from

infancy to old age but 60% are diagnosed in patients between 10 to 40 years of age. There is slight predilection for males, with M:F ratio of 1.3:1 and mandible is involved in 80% of cases with marked propensity to involve the posterior body of mandible and ascending ramus.[7]

In the present case presence of multiple odontogenic keratocysts, narrow ribs and nevi suggested a final diagnosis of Gorlin-Goltz syndrome according to diagnostic criteria given by Kimonis et al 1997.[6]

The importance of diagnosing OKCs is being stressed by many researchers due to the fact that they grow to a large size before clinically manifesting and have a high-rate of recurrence.

However, OKCs are often the first and most representative sign of Gorlin's syndrome. They are present in 90% of patients with NBCCs.[2] The appearance of two or more recurrent OKCs or appearance of an OKC in a young patient should lead dentist to suspect the presence of NBCCs. In the present case as the patient was 21 years old and had multiple OKCs on radioigraphic examination, we subjected the patient for chest radiograph which revealed rib abnormality.

General examination reveled nevi on flexor aspect of upper arm and on right side of back, which is in accordance with past literature where most of BCCs are found on back, and hence a diagnosis of NBCCs was made.

BCCs most often proliferate between puberty and 35 years of age as was seen in our case. Only after puberty however, BCCs can become aggressive and locally invasive.[3,6]

Other dermal manifestation are benign cyst, which are keratin filled cysts found on face in 30% of patients and palmer, plantar pits which are tiny dermal defects of about 2 to 3 mm in diameter and 1 to 3 mm in depth where both of findings were absent in our case.[9]

Majority of maxillary cysts occur in incisor-canine and molar tuberosity region. The most common site being the molar ramus region followed by incisor canine region in mandible as was seen in our case. There was a cyst in maxillary premolar region which is rare but adds to 3% which was revealed in a study by Muzio.[8]

Among the other oral findings recently described is bilateral hyperplasia of mandibular coronoid process.[10]

Skeletal anomalies: The gene responsible for Gorlin syndrome is suggested to have an effect on development of skeletal system manifesting with altered shape of ribs, number of ribs, shape of skull being most affected our case also had demonstrated abnormality with ribs.[11]

Ocular defects: Hypertelorism was evident in our case which is observed in 70% of patients with NBCCs.[12]

As per the diagnosis; Muzio in 1999 has suggested a specific and systematic clinical protocol to diagnose these patients which is helpful to diagnose patients at risk of Gorlin syndrome. In young children at risk earlier detailed examination is recommended. An OPG once in a year from 8 years of age and annual examination of skin is recommended.

Treatment: Multispeciality treatment is advised for patients with Gorlin syndrome.

CONCLUSION

Thorough clinical examination supplemented with appropriate investigations reveal the concerned diagnosis as was observed in the present case, where in the patient reported with mere dental pain but thorough evaluation lead to diagnosis of Gorlin syndrome followed by prompt treatment of the patient. So as to reduce the long-term sequele and mortality imposed by Gorlin syndrome, early diagnosing and treatment should be the mainstay for patient benefit.

ACKNOWLEDGMENT

Our sincere thanks to Departement of Oral Pathology, KLESs Institute of Dental Sciences, Belgaum for their histopathological expertise.

REFERENCES

1. Manjula Hebbale, Anjana Bagewadi, Vaishali Keluskar. Bilateral odontogenic keratocyst: A case report, JIAOMR 2005;17(01): 24-27.
2. Mangredi M, Vescovi P, Bonanini M, Porter S. Nevoid basal cell carcinoma syndrome: A Review of Literature. Int J Oral Maxillofacial Surg 2004;33:117-24.
3. Deepa MS, Raphy Paul C, Anita Balan. Gorlin-Goltz syndrome: A Case Report, JIAOMR 2003;15:203-09.
4. MM Cohen (Jr). Nevoid basal cell carcinoma syndrome: Molecular biology and new hypothesis. Int J Oral Maxillofac Surg 1999;28:210-23.
5. Gailani MR, Bale SJ, Leffel DJ. Developmental defects in Gorlin syndrome related to putative tumor suppressor gene on chromosome. Cell 1992;69(1):111-17.
6. Lorenzo Lo Muzio, Pierfrancero Nocini, Paulo Maurizo. Early diagnosis of Nevoid basal cell carcinoma syndrome. J Am Dent Assoc 1999;130(5):669-74.
7. Browne RM. "The odontogenic keratocyst; clinical aspects". Brit Dent J 1970;128:225-31.
8. Lo Muzio L, Nocini PF, Sawaie A, Consolo V. Nevoid basal cell carcinoma syndrome. Clinical findings in 37 Italian affected individuals. Clin Genet 1999;55(1):34-40.
9. Gutterrez MM, Morcee. Nevoid basal cell carcinoma syndrome: A review and case report of a patient with unilateral basal cell nevus syndrome. Am Acad Dermatol 1986;15(5):1023-30.
10. Leonardi RG. Bilateral hyperplasia of the mandibular coronoid process associated with the nevoid basal cell carcinoma syndrome in Italian boy. Br Dent J 2001;190(7):349-50.
11. Robert P Langlais, Olaf E Langland, Christofell J Nortje. "Diagnostic imaging of jaws" Willaims Company. Malvern, 1995. Chapter 13. Multiple Radiolucencies 327-29.
12. Shafer WG, Hine MK, Levy BA, Charles ET. Text Book of Oral Pathology (5th ed), 2005.