

# A Rare Case of Extraforaminal Schwannoma in Lumbar Region in an Elderly Male without Neurofibromatosis Operated by Transparaspinal Approach

<sup>1</sup>Vishwanath Sidram, <sup>2</sup>PC Chandrakumar, <sup>3</sup>M Varunkumar, <sup>4</sup>Bellara Raghavendra

## ABSTRACT

**Introduction:** Schwannoma is a benign tumor arising from the neural crest-derived Schwann cells. These tumors usually grow within the spinal canal and produce compression of spinal cord and nerve root of origin.

**Aim:** To report a rare case of extraforaminal schwannoma in lumbar region in an elderly male operated by transparaspinal approach.

**Case:** A 65-year-old male, presented with pain which is characterized by radiation to right thigh and associated with pins and needles sensation, intermittent type.

**Investigation:** MRI scan demonstrated mixed intensity lesion in right paravertebral region L3-4 suggestive of extraforaminal schwannoma and disc bulge L3-4, L4-5 compressing anterior thecal sac and bilateral traversing nerve roots. Histology showed a tumor with features of schwannoma. The stroma at places shows myxoid change and hyalinization. Mononuclear cell infiltration is seen into the stroma.

**Treatment:** Complete removal of the mass done by transparaspinal approach.

**Results:** No residual tumor on follow-up scan and pain disappeared.

**Conclusion:** Extraforaminal schwannoma in lumbar region in an elderly male is a rare condition. The rarity of extraforaminal schwannoma and transparaspinal excision was highlighted. Transparaspinal approach is the most feasible and directly accessible approach to remove tumor and relieve pressure symptoms and rare possibility of malignancy.

**Keywords:** Extraforaminal, Schwannoma, Transparaspinal.

**How to cite this article:** Sidram V, Chandrakumar PC, Varunkumar M, Raghavendra B. A Rare Case of Extraforaminal Schwannoma in Lumbar Region in an Elderly Male without Neurofibromatosis Operated by Transparaspinal Approach. *J Spinal Surg* 2014;1(2):98-100.

**Source of support:** Nil

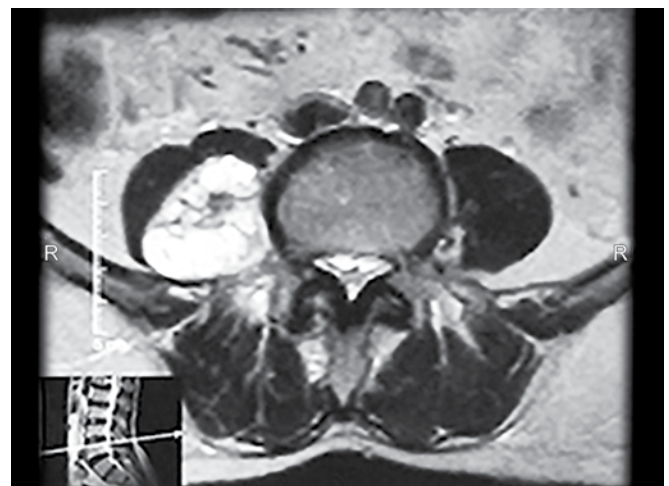
**Conflict of interest:** None

## INTRODUCTION

Schwannoma is a benign tumor arising from the neural crest-derived Schwann cells.<sup>1</sup> The first case was described in 1954.<sup>2</sup> Spinal schwannomas are about 25% of intradural spinal cord tumors in adults.<sup>3</sup> Most are solitary and can occur throughout the spinal canal.<sup>3</sup> In that extraforaminal type is a rare entity.<sup>4</sup> Familial types associated with neurofibromatosis type 2.<sup>3</sup> Schwannomas are encapsulated tumors which have rare occurrence, which are commonly located in peripheral nerves of limbs, head and neck.<sup>1</sup> They are rare because most of them are asymptomatic types are the most common forms, thus making difficult at early stage diagnosis, although non-specific abdominal or back pain may occur.<sup>5</sup>

## CASE REPORT

A 65-year-old male patient presented with pain radiating to right thigh and associated with pins and needle sensations since 5 years. Clinical examination found to be normal. MRI of spine was done which showed mixed intensity lesion in right paravertebral region L3 L4 L5 (Fig. 1) suggestive of extraforaminal schwannoma and disc bulge L3-4, L4-5 compressing anterior thecal sac



**Fig. 1:** MRI of spine showing mixed intensity lesion in right paravertebral region L3 L4 L5

<sup>1</sup>Associate Professor, <sup>2,4</sup>Assistant Professor  
<sup>3</sup>Postgraduate

<sup>1</sup>Department of Neurosurgery, Vijayanagara Institute of Medical Sciences, Bellary, Karnataka, India

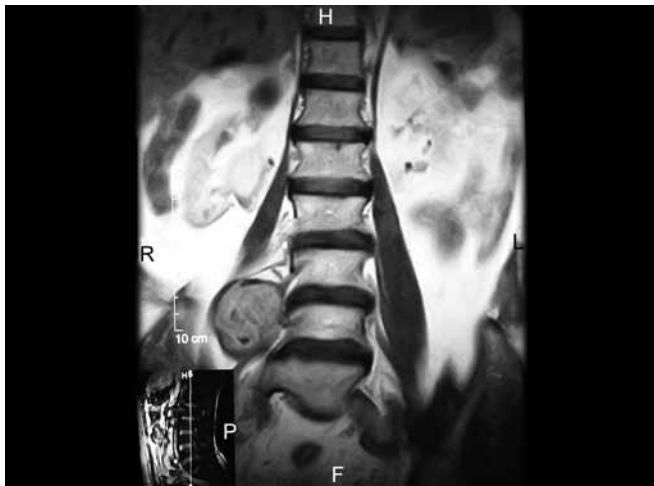
<sup>2,3</sup>Department of Surgery, Vijayanagara Institute of Medical Sciences, Bellary, Karnataka, India

<sup>4</sup>Department of Community Medicine, Vijayanagara Institute of Medical Sciences, Bellary, Karnataka, India

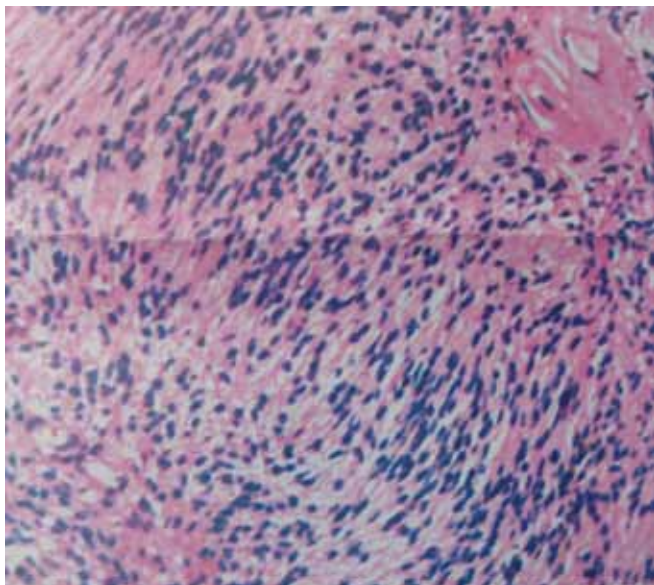
**Corresponding Author:** Bellara Raghavendra, Assistant Professor Department of Community Medicine, Vijayanagara Institute of Medical Sciences, Cantonment, Bellary, Karnataka, India Phone: +91-9901301830, e-mail: bellararaghu@gmail.com

and bilateral traversing nerve roots and well-defined encapsulated mass, in the right paraspinal region at the L3 L4 L5 level along the posterior side of left psoas muscle (Fig. 2).

Patient was posted for surgery. Incision site was planned by localizing the lesion using fluoroscopic technique. Lesion found to be at L3/4 level. With patient in prone position vertical median incision taken supplemented by a transverse T-shaped extension at the level of tumor. Fascial layer is exposed and is opened laterally directly over the tumor to the edge of the paraspinal muscle complex. Paraspinal muscles i.e part of external and internal oblique muscles, serratus posterior inferior and erector spinae were transected to expose tumor. Spinous process and lamina are removed to expose tumor fully. Interface between capsule of the tumor and the dura is developed. Tumor was removed in toto



**Fig. 2:** MRI showing a well-defined encapsulated mass, in the right paraspinal region at the L3 L4 L5 level along the posterior side of left psoas muscle



**Fig. 3:** Histology—the stroma at places shows myxoid change and hyalinization and mononuclear cell infiltration in the stroma

along with the dorsal nerve roots involved. Suture ligation done to the root stumps. No cerebro spinal fluid leak found intraoperatively. Incision closed in layers. Specimen was sent for histopathological examination. Histology showed a tumor with features of schwannoma. The stroma at places shows myxoid change and hyalinization. Mononuclear cell infiltration is seen into the stroma (Fig. 3).

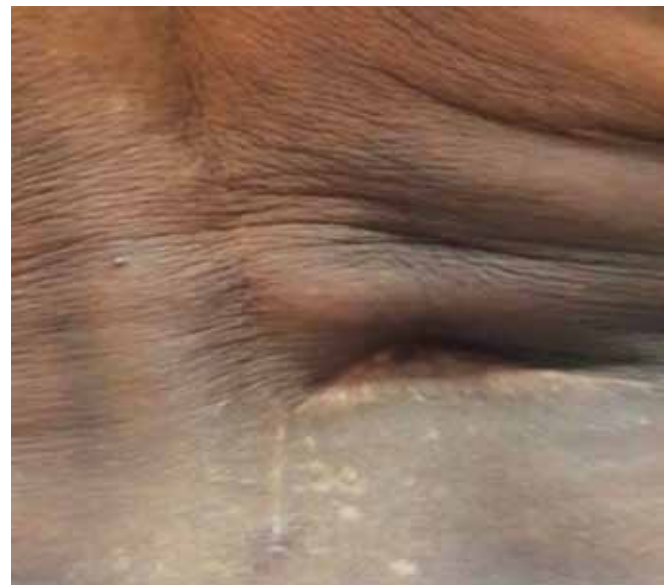In postoperative period, patient had surgical site seroma formation. Skin stitches opened and allowed to heal by secondary intention (Fig. 4). Patient was relieved of pain symptoms which were present earlier, without any neurological deficits.

Repeat MRI was done during follow-up visit after 6 weeks which showed no evidence of tumor (Fig. 5).

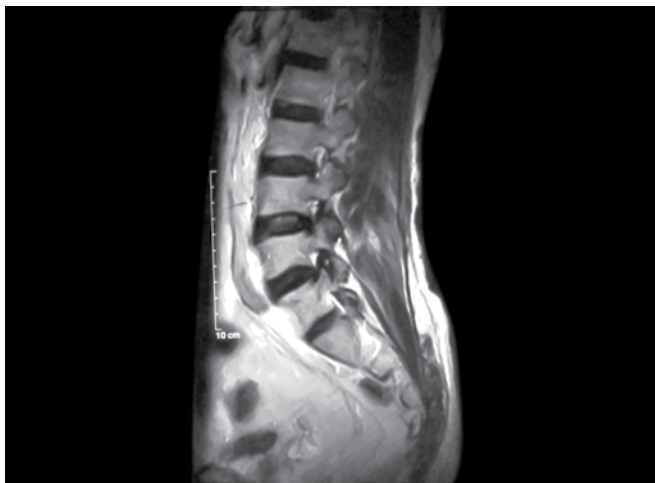
## DISCUSSION

Spinal schwannomas which occur in complex manner poses challenge for the surgeon.<sup>6</sup> These tumors grow within spinal canal and produce cord and nerve root compression.<sup>6</sup> Cellular, glandular, epithelioid, melanotic and ancient types have been described.<sup>7</sup> CECT shows a non-specific, well defined lesion with low or mixed signal, sometimes rarely areas of cystic necrotic centre seen.<sup>8</sup> MRI show low-intensity signals on T1-weighted images and high-intensity signals on T2-weighted images.<sup>9</sup> Schwannomas characteristically grow within the capsule and is peripherally attached to parent nerve.<sup>10</sup>

Histology shows two growth patterns, Antoni A and Antoni B. Antoni A pattern has highly cellular zones. These zones have nuclear palisades and nuclear free zones between palisades are termed a Verocay bodies.<sup>10</sup> In the Antoni B pattern of growth, the tumor is less densely cellular and consists of



**Fig. 4:** Fully healed T-shaped incision by secondary intention



**Fig. 5:** Postoperative follow-up MRI showing no residual tumor a loose meshwork of cells, microcysts and myxoid stroma.<sup>10</sup> Malignant change is extremely rare, but local recurrence can follow incomplete resection.<sup>1</sup>

Transparaspinal exposure provides direct and simplest route for resection of these tumors in extraforaminal region. This approach is based on two concepts. First, even though paraspinal muscles are sectioned completely there are minimal biomechanical consequences. Second, there is a surgical plane between adjacent neural and vascular structures and tumor capsule. This allows complete removal of tumor from single posterior approach.<sup>6</sup>

## CONCLUSION

Extraforaminal schwannoma in lumbar region in an elderly male is a rare condition. The rarity of extraforaminal

schwannoma and transparaspinal excision was highlighted. Transparaspinal approach is the most feasible and directly accessible approach to remove the tumor and relieve pressure symptoms and rare possibility of malignancy.

## REFERENCES

1. Antonopoulos C, Lilimpakis C, Karagianni M, Daskalopoulou D, Kyriakou T, Vagianos C. Ancient schwannoma of lumbar spine and review of the literature on paraspinal tumors, the role of preoperative biopsy: a case report. *Cases J* 2009 Dec;2:9325.
2. McCormack LJ, Hazard JB, Dickson JA. Malignant epithelioid neurilemoma (schwannoma). *Cancer* 1954 July;7(4):725-728.
3. Jeon JH, Hwang HS, Kim CH. Spinal schwannoma; analysis of 40 cases. *J Korean Neurosurg Soc* 2008 Mar;43(3):135-138.
4. Weil AG, Obaid S, Shehadeh M, Shedid D. Minimally invasive removal of a giant extradural lumbar foraminal schwannoma. *Canada ISSN* 2011;2(1):186.
5. Inokuchi T, Takiuchi H, Moriwaki Y, Ka T, Takahashi S, Tsutsumi Z, Shima H, Hirota S, Yamamoto T. Retroperitoneal ancient schwannoma presenting as an adrenal incidentaloma: CT and MR findings. *Magn Reson Imaging* 2006;24(10):1389-1393.
6. Wolfia CE, Resnick DK. Transparaspinal approach to Dumbbell-shaped tumors. *Neurosurgical Operative Atlas. Spine and peripheral nerves* 2nd edition, Ch. 43, Jhieme Publishers 259-265.
7. Chan PT, Tripathi S, Low SE, Robinson LQ. Case report-ancient schwannoma of the scrotum. *BMC Urol* 2007;7:1.
8. Cury J, Coelho RF, Srougi M. Retroperitoneal schwannoma: Case series and literature review. *Clinics* 2007;62(3):359-362.
9. Nasu K1, Arima K, Yoshimatsu J, Miyakawa I. CT and MRI findings in a case of pelvic schwannoma. *Gynecol Obstet Invest* 1998 Aug;46(2):142-144.
10. Wippold II FJ, Lubnera M, Perrind RJ, Lämmler M, Perry A. Neuropathology for the neuroradiologist: Antoni A and Antoni B tissue patterns. *Am J Neuro Radiol* 2007 Oct;28:1633-1638.