10.5005/jp-journals-10039-1014

REVIEW ARTICLE

Odontoid Fractures: Management

[1]P Sai Sudarsan, [2]I Dinakar

ABSTRACT

Odontoid fractures account for approximately 20% of all cervical fractures, majority of them being type II. Treatment of odontoid fractures is determined by multiple factors, including fracture type, presence of associated injuries, patient's age and comorbidities. Majority of type I and III fractures do not warrant surgical correction. However, management of type II fractures still remains controversial. Of late internal fixation has become an accepted treatment. Multiple surgical options have been proposed. This article reviews various alternatives of treating odontoid fractures.

Keywords: Odontoid fractures, Transverse atlantal ligament, Posterior fixation, Trans articular screws, Odontoid screws.

How to cite this article: Sudarsan PS, Dinakar I. Odontoid Fractures: Management. J Spinal Surg 2014;1(2):69-76.

Source of support: Nil

Conflict of interest: None

HISTORICAL PERSPECTIVE

Mixter and Osgood[1] were the first to describe the management of odontoid fractures in 1910. Osgood and Lund[2] published the first series of odontoid fractures in 1928. They reported a series of 55 cases. There was a very high incidence of mortality and morbidity in their series. Ten patients who were normal after the initial injury died subsequently following a trivial injury. They inferred that union in dens fracture was rare.

ANATOMY OF UPPER CERVICAL SPINE

The upper cervical spine consists of atlas and axis.[3] The atlas articulates superiorly with occiput (atlantooccipital joint) and inferiorly with the axis (atlantoaxial joint). The atlanto axial joint is responsible for 50% of all cervical rotation and the atlanto occipital joint is responsible for 50% of flexion and extension.

The atlas is ring shaped and does not have a body, unlike the rest of the vertebrae. Fused remnants of the atlas body have become part of C2 when it is called the odontoid process.[4] The odontoid process is held in tight proximity to the posterior aspect of anterior arch of atlas by the transverse atlantal ligament. This ligament stabilizes the atlanto axial joint. The apical and alar ligaments provide further stabilization and prevent posterior displacement of the dens in relation to the atlas.

The axis has a large vertebral body, which contains the odontoid process. The odontoid process articulates with the anterior arch of the atlas *via* its anterior articular facet and is held in place by the transverse ligament. The axis articulates with the atlas with its superior articular facets.

[1]Head, [2]Consultant

[1]Department of Neurosurgery, Star Institute of Neurosciences Hyderabad, Telangana, India

[2]Department of Neurosurgery, Yashoda Hospital, Secunderabad Telangana, India

Corresponding Author: P Sai Sudarsan, Head, Department of Neurosurgery, Star Institute of Neurosciences, Banjara Hills Hyderabad-500034, Telangana, India, e-mail: sudarsan63@gmail.com

EMBRYOLOGY

The axis has a very complex embryologic development. It is derived from 4 ossification centers, one for the body, one for the odontoid process and two for the neural arches.[5] The odontoid process fuses by the seventh gestational month. At birth a vestigial cartilaginous disk space called the neuro central synchondrosis separates the odontoid process from the body of the axis.[4] The synchondrosis is seen in all children around 3 years and disappears at around 6 years.[5] It should not be confused with a fracture. The apical portion of dens ossifies by about 4 years and fuses with the rest of the structures around 12 years of age.[5]

VASCULATURE

Dens has an extensive arterial anastomotic network, fed by the paired anterior and posterior ascending arteries arising from the vertebral and the carotid arterial arcade from the skull base. The anastomotic arcade also receives tributaries from the ascending pharyngeal arteries.[4,6]

LIGAMENTS

The external and internal ligaments secure the atlantoaxial joints. The external ligaments are the atlantooccipital and anterior longitudinal ligaments. The internal ligaments have five components (Fig. 1):

1. The transverse ligament is the major stabilizing ligament of the atlantoaxial joint. It holds the odontoid process in place against the posterior atlas.[7]
2 and 3. Alar ligaments attach the axis to the base of the skull.[8] They function as stabilizing structures and act to limit axial rotation and lateral bending on the contralateral side.[9]

4. Apical ligament attaches the tip of the odontoid process to the basion. It also adds to the stability of the cranio vertebral junction.[10]
5. Tectorial membrane is a well-developed superior continuation of the deeper layer of the posterior longitudinal ligament.[11] It restricts the extension at the atlantooccipital joint and flexion/extension at the atlantoaxial joint.[12]

These ligaments play a vital role in maintaining structural stability of the upper cervical spine. A thorough working knowledge of this anatomy is therefore important.[13]

CLASSIFICATION

Anderson and D'Alonzo[14] in 1974 classified the odontoid fractures (Fig. 2). Their study was based on a detailed analysis of 60 patients. Their classification still holds good. They identified 3 types of fractures based on the anatomic location of the fracture line. Type I is an oblique fracture through the upper part of the odontoid process. It represents an avulsion fracture where the alar ligament attaches to the tip of the odontoid process. Type II is a fracture occurring at the junction of the odontoid process with the body of the second cervical vertebra. Type III is a fracture line that extends downwards into the cancellous portion of the body and is really a fracture through the body of the axis. Each subtype is further classified as displaced or undisplaced. This was modified by Hadley et al.[15] They described the type II A fracture where there is an additional chip fracture at the anterior or posterior aspect of the base of the dens. This modification is significant, because this fracture subtype is very unstable and results in nonunion, whatever be the direction of initial dens displacement. This subset of fractures should be considered for early surgical stabilization. They account for 5% of type II fractures.

Grauer et al[16] proposed a modified classification of odontoid fractures in 2005, stressing on fracture management. The type II and III of the Anderson and D'Alonzo were redefined based on the involvement of superior articular facet. According to Grauer et al in type II fracture the superior articular facet was spared where as type III fractures involved the superior articular facet. They further subclassified the type II fractures. In type II subtype A the displacement was less than 1 mm with no comminution. In type II subtype B the fracture line passes from antero superior to postero inferior with a displacement of more than 1 mm. It is ideal for anterior screw fixation. The fracture line in type II subtype C passes from antero inferior to postero superior or there may be significant comminution of dens. This subtype is treated with posterior atlanto axial fixation. Their analysis did not assess their classification with respect to treatment.

INCIDENCE

Odontoid fractures are the most common fractures of the axis.[17] In the Greene et al[18] series of 340 fractures, odontoid fractures accounted for 199 of the axis fractures, accounting for 59%. The type I is the least prevalent. It accounted for only 1% of all odontoid fractures in Greene et al series.[18] Anderson and D'Alonzo found the incidence to be 3% in their series of 60 dens fractures. The type II dens fracture is the most common (Figs 3A and B). It accounted for 60% in Greene et al series and 54% in Anderson and D'Alonzo series. The type III odontoid fracture was second common amounting to 39% in Greene et al and 42% in Anderson and D'Alonzo reviews respectively.

MANAGEMENT

The cervical spine research society[19] in 1985 published a multi center review regarding management of odontoid frac-

Anderson and D'Alanzo	*Hadley*	*Grauer*
Type I	Type I	Type I
Type II	Type II	Type IIA
	Type IIA	Type IIB
		Type IIC
Type III	Type III	Type III

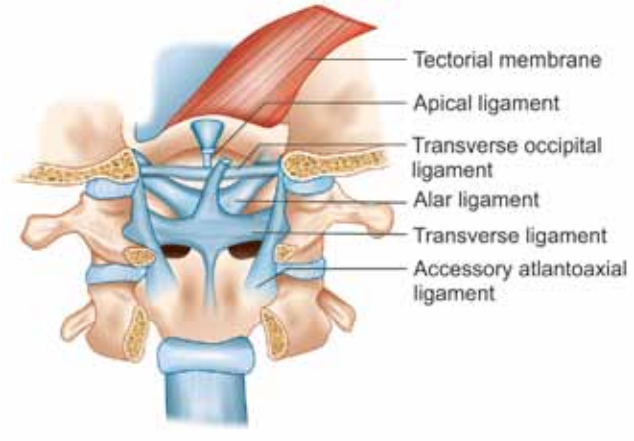

Fig. 1: Schematic representation of ligaments of craniovertebral junction

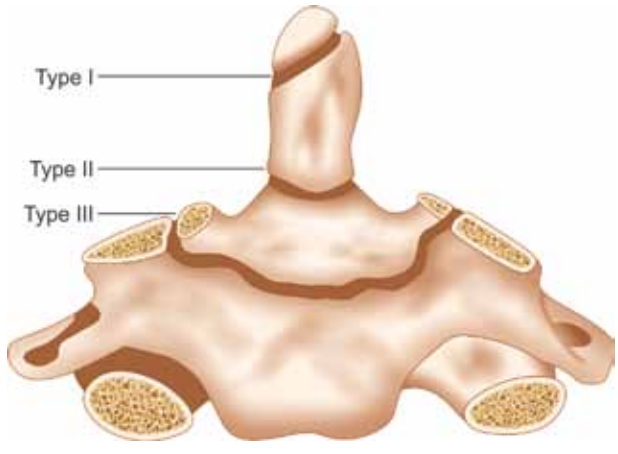

Fig. 2: Odontoid fractures depicted in a picture

Figs 3A and B: Computed tomography (CT) images of type II odontoid fracture in sagittal (A) and coronal (B) planes

tures. This review included many patients with type II and III fractures in whom no treatment was offered. Bony fusion did not occur in any of them. The conclusion in this review was no treatment of odontoid fractures is not an acceptable management option.

The many treatment strategies proposed for odontoid fractures are based on fracture type, the degree of dens displacement, the angle of the fracture with respect to the body, the integrity of the transverse ligament and the age of the patient. There are many external orthoses for nonoperative management of odontoid fractures with variable results. Surgical options include both anterior and posterior approaches. Anterior approaches include odontoid screw fixation and anterior trans articular screw fixation. Posterior stabilization techniques include Halifax clamps, screw and rod constructs, posterior trans articular screws and wiring techniques.

NONOPERATIVE MEASURES: TRACTION/CERVICAL COLLAR

Traynelis[20] and Julien[21] performed literature review on odontoid fractures treated conservatively with traction for 4 to 6 weeks followed by collar immobilization. They found 100% fusion rates in 3 cases of type I fractures but only 57% fusion in 97 cases of type II fractures. The fusion rates increased to 88% in 65 cases of type III fractures. This treatment strategy can be considered acceptable for type I and III fractures but not ideal for type II subtype. This conservative modality should only be considered for type II fractures in extremely unstable and critically ill patients who are otherwise not fit for any surgical intervention.

Cervical collar immobilization alone may suffice for type I fractures. But in type III fractures, there was a 10% incidence of non-union and a 40% incidence of mal union in a series by Clark and White.[19] In another study by Polin et al[22] 100% fracture healing and stability was documented in post immobilization flexion and extension imaging in type III fractures. The same study documented a fusion rate of only 53% in type II fractures. In another study by Wang et al[23] the fusion rate in type II fractures was only 57%.

HALO DEVICE IMMOBILIZATION

Greene et al[18] managed 2 cases with type I fracture using halo immobilization and they obtained good bony fusion in 12 weeks. Similar results were seen by Julien et al[21] analysis in a review of 9 case series.[19,24-27] In this 9 case series, there were 3 cases of type I fractures and all had good bony fusion with halo immobilization. Sixty-nine patients with type III fractures were managed with halo immobilization in Greene et al[18] series. They obtained good bony fusion in 68 patients with 1.4% nonunion. Polin et al[22] reported 100% bony union in 13 cases of type III fractures. In Julien et al[21] analysis the union rate was 84%. Seven cases in this analysis had mal union and non union was documented in 6 cases. This experience suggests that rigid immobilization alone is an effective management strategy in both type I and III odontoid fractures.

Results in type II fracture group did not match those of type I and III groups. In all the series reviewed the failure rate was close to 30% in type II fractures. The high incidence of non union in type II fractures can be explained by the embryological development of the axis as a whole. The axis as a unit is supplied by 2 vascular arcades as described by Schiff and Park[6] in 1973. One arcade supplies the body of the axis and another arcade supplies the tip of the dens as summarized by Maiman and Larson.[28] The base of the dens is relatively avascular. Vascularity becomes more compromized after fracture with displacement. Added to this, the dens are enveloped in a synovium and there is no periosteal blood supply. Another reason for non union is the orientation of the apical ligament. Following a fracture there is a distraction effect at the fracture plane leading to non union.

Non union rates are very high in type II A odontoid fractures where there is an additional chip fracture at the base of the dens. These cases should be considered for early surgery. Hadley et al[29] in 1985 reported that non union rate was very high in type II fractures with dens displacement of more than 6 mm. They reported a non union rate of 67% compared to 26% in cases where the dens displacement was less than 6 mm. This relationship was further confirmed by Greene et al[18] in 1997. Several other investigators also found a negative correlation between healing and dens displacement.[19,26,27,30,31]

Lennarson et al[32] found a good correlation with age. They evaluated[33] patients with isolated type II odontoid fractures and found that nonunion was very high in patients above 50 years. It was 21 times high when compared to the group

below 50 years. Patients' sex, degree of fracture displacement, direction of displacement, duration of hospital stay did not show any significant effect on outcome in their study.[32]

SURGERY FOR ODONTOID FRACTURES

Posterior approach was the mainstay in the surgical treatment for many decades. In 1910, Mixter and Osgood[1] reported the first surgery for odontoid fractures. In 1939, Gallie[33] described the first wire and bone technique. Since then many similar constructs have been tried with relative success. Inter laminar clamps were introduced by Tucker[34] in 1975. Magerl[35] in 1979 developed the atlanto axial screw technique via a dorsal trans articular approach. In 1981, Bohler[36] described an osteo synthesis technique through anterior route. Goel[37] et al in 1994 and Harms and Melcher[38] in 2011 described a C1 lateral mass and C2 pedicle screw and rod technique. In 2004, Wright[39] described a poly axial screw and rod technique.

POSTERIOR CERVICAL STABILIZATION

Stainless steel was long the alloy of choice in spinal instrumentation because of its strength and suppleness. Traditionally monofilament stainless steel was used. Subsequently braided titanium cables have replaced steel. Their main disadvantage is they can cut through the bone.

GALLIE FUSION

This is a C1-C2 arthrodesis. A notched bone graft is placed between the posterior arch of atlas and superior part of C2 spine. The graft is secured with a C1 sub laminar wire that winds around the C2 spinous process. It is a solitary midline fixation and fusion construct susceptible to rotational forces.

BROOKS AND JENKINS FUSION

Brooks and Jenkins[40] in 1978 described a construct to overcome the rotational deficiency of Gallie fusion. They used a bilateral inter laminar bone grafts and bilateral sub laminar wires. Griswold et al[41] modified this by using 2 sub laminar wires on either side. This technique increased the risk of neurological deficit.

SONNTAG'S MODIFICATION OF GALLIE FUSION

In this modification, a bi cortical bone graft is wedged between the decorticated inferior edge of C1 lamina and decorticated superior edge of C2 lamina and spinous process. Wires are passed just as in Gallie fusion. The graft is vertically oriented and provides immediate segmental stability. The bone to bone contact is cancellous and this aids in excellent fusion. The wire contact is better and the stability is assured in all the 3 planes. Since, there is no sublaminar wire under the C2 the neurological deficits are lesser compared to Brooke fusion.

EFFECTIVENESS OF WIRE FIXATION

There have been many retrospective analysis of wire-bone techniques.[19,24-26,28,30,42,43] The over all fusion rates in type II fracture was 87% and 100% in type III fractures. One series of Maiman and Larson[28] documented a fusion rate of only 35% at the dens fracture line, but the dorsal fusion rate was 100%. In all the analyzed cases of these series postoperative immobilization was done with Halo vest device.

HALIFAX CLAMP ARTHRODESIS

They were described by Tucker[34] in 1975. This method avoids sub laminar wires and immediate stabilization is provided by compression over the graft. The odontoid could be dorsally angulated with compression leading to ventral compression over the spinal cord. There were many other complications and this method went out of vogue. Statham et al[44] reported complications in 14 of 45 patients they studied. Twenty percent needed reoperation. In contrast Huang and Chen[45] achieved good fusion in all the patients. They combined clamp arthrodesis with Halo vest immobilization.

TRANS ARTICULAR SCREW FIXATION

This was first described by Magerl.[35] This method provides immediate rigid stabilization of C1-C2 complex. This can be re-enforced with Soontag modified Gallie arthrodesis. Vertebral artery trajectory should be predetermined since about 20% population have an anomalous vertebral artery trajectory at this level.[46] Fluoroscopy is very useful during this procedure. The entry point on C2 is 2 mm lateral from the medial edge of the facet and 3 mm superior to the caudal edge. The trajectory is straight up across the C1 and C2 articular surfaces and into the lateral mass of C1. The surgeon can use a probe to palpate the medial surface of the C2 pedicle for assistance. The exit point should be in the posterior third of superior surface of C2 facet. If the vertebral artery bleeding is encountered, opposite side should not be attempted. A lag screw will help in reducing the distracted joint. The success rate of bony fusion with Magerl technique is approximately 90% with a reported success between 78 and 99%.[47-53] The vertebral artery injury during this technique is reported to be between 3.7 and 8.2%.[47,48,51,54]

GOEL AND LAHERI/HARMS AND MELCHER FIXATION

Goel and Laher[55] first described the lateral mass screws in C1 and pedicle screws in C2 with plate fixation in 1994 and the same technique was described by Harms and Melcher[38] in 2001 with poly axial screws and rods (Fig. 4). Goel and Laher further described distraction of C1-C2 joint space with spacers. Resnick and Benzel[56] further modified the Harms

Fig. 4: X-ray showing C1 lateral mass and C2 pedicle screw fixation

and Melcher technique with C1 and C2 pedicle screws. This method of atlanto axial stabilization is the procedure of choice for immediate C1-C2 stabilization. In Goel et al[37] series, 160 patients were operated with a bony fusion of 100%. Harmes and Melcher[38] also reported a 100% fusion rate in their series of 37 patients. There was no vertebral artery injury or spinal cord injury in both the series. Aryan et al[57] treated 102 patients with C1-C2 instability with 98% fusion rates. They used a distraction technique by placing an allograft into the decorticated C1-C2 joint in 39 cases in their series.

CROSSED C2 INTRALAMINAR SCREWS

In 2004, Wright[39] described a technique involving the use of poly axial screws inserted into the lamina of C2 in a crossing fashion. These screws are secured to C1 lateral mass screws. C2 laminar screws do not damage the vertebral arteries and thus can be used as a rescue technique should the vertebral artery be compromised. The laminar screws enter at the spino laminar junction of the opposite lamina at which they will be placed. The screw intended for the right lamina enters the left lamina and its poly axial head is on the left side. One side should be inserted at the rostral end of the lamina and the opposite side, the caudal end of the lamina. Wright[39] and Menendez and Wright[58] separately reported 100% fusion rates with no complications. However, the authors warn that this newer technique needs further study before widespread implementation.

BIOMECHANICS IN POSTERIOR ARTHRODESIS

Dickman et al[59] compared the biomechanics of all C1-C2 cable fixations. All the techniques were compared and each of the constructs was subjected to fatigue. None of the cable techniques were found to be rigid in all directions. They all allowed considerable rotation and translation. Modified Brooks and Jenkins and the Sonntag interspinous techniques provided better fixation than Gallie technique. The authors opined that additional support to C1-C2 wiring techniques in the form of rigid cervical collar, halo vest or internal fixation like trans articular screw will have a long-term benefit.

Naderi et al[60] evaluated the biomechanics of different C1-C2 constructs. They found that interspinous cable graft provided superior restriction of the angular motion of flexion and extension, but provided limited rotational and lateral bending stabilization. The bilateral trans articular screw fixation device gave the best rotational and lateral bending stabilization but was not very effective in limiting flexion and extension movements. The most stable construct in their findings was the combination of 3 point fixation model of C1-C2 interspinous cable graft with bilateral trans articular screws.

Richter et al[61] compared the biomechanics of different C1-C2 internal fixation and fusion constructs and opined that the 3 point fixation of C1-C2 provided the most stable construct. The trans articular screw technique combined with the atlas claw provided the best fixation of C1-C2. Of the constructs that did not involve the trans articular screws, the C1-C2 screw rod technique provided the best stability.

Claybrooks et al[62] compared the biomechanics of C1 lateral mass-C2 pedicle fixation with C1 lateral mass-C2 laminar fixation. Both techniques were equivalent on flexion and extension and antero posterior translation. However, the C2 pedicle screw fixation demonstrated more stability with lateral bending and axial rotation. Gorek et al[63] found these 2 constructs to be biomechanically equal.

Lapsiwala et al[64] compared anterior trans articular, posterior trans articular, C1 lateral mass-C2 pedicle screws and C1 lateral mass-C2 intra laminar screws. It was found that the posterior trans articular fixation and C2 pedicle fixation constructs were better off with cable augmentation in flexion-extension. Results of anterior trans articular fixation were same as that of posterior trans articular fixation without cable augmentation. There was a significant difference in lateral bending between posterior trans articular fixation with cable augmentation and C2 intra laminar screw fixation with cable augmentation. The authors concluded that C2 intra laminar screw fixation with cable augmentation provided significant stability compared with the baseline intact spine.

ANTERIOR CERVICAL FIXATION

Good fusion rates can be achieved with posterior fixation but at the cost of range of motion. There will be restriction of head on neck rotation. White and Punjabi[65] described a reduction of 47º of axial rotation and a reduction of 10º of flexion and extension following posterior arthrodesis. The segment is stabilized but the fracture is not reduced nor completely fused. Maiman and Larson[28] in fact documented only

35% fusion across the fracture line after posterior arthrodesis for odontoid fractures. Contrary to the posterior arthrodesis odontoid screw fixation aids in direct reduction and fixation of the fracture while maintaining rotational mobility.

ODONTOID SCREW FIXATION

Bohler[36] was the first to describe this approach. The utility of this technique was demonstrated with the series of Aebi et al[66] and Apfelbaum.[67] The main indications for this procedure are type II odontoid fracture and some types of type III fractures. The main limiting factor for odontoid screw fixation is the integrity of the transverse ligament. Disruption of the transverse ligament is an absolute contra indication. Relative contra indications are severe osteopenia, a sloping fracture plane from antero inferior to postero superior, a fracture older than 6 months and poor patient body habitus.

Julien et al[21] reviewed a series of articles on odontoid fixation[24,26,36,68,69] and found that the fusion rates of type II fractures was 89% (112 of 126 patients) and that of type III fractures was 100% (20 patients). Subach et al[70] managed 26 patients with odontoid screw fixation and achieved 96% fusion. Jenkins et al[69] compared single screw to double screw fixation in a retrospective series of 42 patients. The fusion rates were 81 and 85% respectively. Apfelbaum et al[67] compared anterior screw fixation in recent and remote fractures. Fusion rates were 88% in 6 months or less group and 25% in the remote injury group. This experience suggests that anterior odontoid screw fixation is most effective when performed early after injury (Fig. 5).

ANTERIOR ATLANTOAXIAL FACET FIXATION

This technique was described by Feiz et al[71] This approach is same as for odontoid screw fixation. The C1-C2 junction is identified on either side and screws are placed in the anterior cortex of C2 through C1-C2 joint space at a 90º angle. This procedure is contra indicated in patients with osteoporosis, fracture of the superior articular facets, C2 body fracture or fracture of lateral mass of C1.

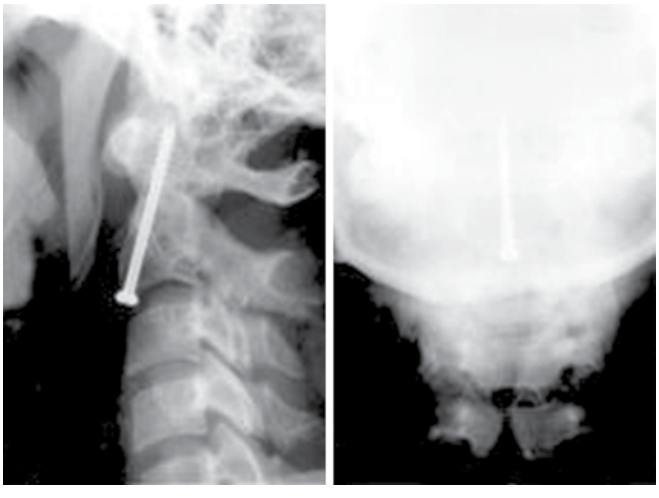

Fig. 5: X-ray showing odontoid screw fixation

ODONTOID FRACTURES IN THE ELDERLY

Many series argue against surgical fixation in the elderly.[18,72,73] Ryan and Taylor[72] described 30 patients aged above 60 with type II dens fracture. There was no significant difference in the outcome between surgical and nonsurgical groups. Lennarson[32] series provides evidence in support of surgery for patients aged over 50 years. In this series of there was 21 times higher rate of non union in the group managed with halo immobilization alone.

SUMMARY

Odontoid fracture is the most common subtype of C2 fractures. Type I odontoid fractures are rare and are usually managed with external orthoses. The fusion rate is 100% regardless of the type of external immobilization. The fusion rates in type III fractures are 85% with external orthoses and 100% with internal fixation and arthrodesis. The common practice is to go for external immobilization initially and to opt for surgical fusion in failed cases.

The treatment of type II fractures is not that straightforward type II fractures are the most common and the management strategies depend on age, fracture comminution, degree of displacement and the integrity of the transverse ligament. Surgical fusion rates are higher in patients aged above 50 years. Type IIA odontoid fractures have a high rate of non union when managed conservatively. They should be operated upon at the earliest. A dens displacement of more than 5 mm or significant posterior displacement are features which support early surgical fixation. If the transverse ligament is intact and fracture line is transverse odontoid screw fixation with postoperative collar immobilization is the treatment of choice. Transverse ligament disruption, comminuted fracture line or antero inferior to postero superior type II fracture warrants a posterior approach. All the methods of posterior arthrodesis have a high fusion rate. Trans articular screw fixation and ploy axial screw rod constructs provide the greatest stability.[17]

REFERENCES

1. Mixter SJ, Osgood RB. IV Traumatic lesions of the atlas and axis. Ann Surg 1910:51(2):193-207.
2. Osgood RB, Lund CC. Fractures of the odontoid process. New Eng J Med 1928;198:61-72.
3. Malanga GA. The diagnosis and treatment of cervical radiculopathy. Med Sci Sports Exerc 1997 July;(7 Suppl):S236-S245.
4. Menezes AH. Embryology, development and classification of disorders of the cranio vertebral junction. In: Dickman CA, Sonntag VKH, Spetzler RF, editors. Suregry of the craniovertebral junction. New York: Thieme Medical Publishers; 1998 p. 3-12.

5. Menezes AH. Evaluation and treatment of congenital and developmental anolamlies of the cervical spine. J Neurosurg 2004;(Spine1)2:188-197.
6. Schiff DC, Park WW. The arterial supply of the odontoid process. J Bone Joint Surg Am 1973;55(7):1450-1456.
7. Dickman CA, Mamourian A, Sonntag VK, Drayer BP. Magnetic resonance imaging of the atlantal ligament for the evaluation of atlanto axial instability. J Neurosurg 1991;75:221-227.
8. Duorak J, Schneider E, Saldinger P, Rahn B. Biomechanics of the craniocervical region: the alar and transverse ligaments. J Orthop Res 1998;6:452-461.
9. Derrick LJ, Chesworth BM. Post motor vehicle accident alar ligament laxity. J Orthop Sports Phys Ther 1992;16:6-11.
10. Ebraheim NA, Lu J, Yang H. The effect of translation of C1-C2 on the spinal canal. Clin Ortho Relat Res 1998;351:222-229.
11. Werne S. Studies in spontaneous atlas dislocation. Acta Orthop Scand Suppl 1957;23:1-150.
12. Oda T, Panjabi MM, Crisco JJ III, Bueff HV, Grob D, Novak J. Role of tectorial membrane in the stability of the upper cervical spine. Clin Biomech (Bristol Avon) 1992;7:201-207.
13. Shane TR, Justin DH, Virginia R, Robert PN, Martin M, Mohammad MS, Marios L, Aaron AC. Ligaments of the craniocervical junction. J Neurosurg Spine 2011;14:607-709.
14. Anderson LD, D'Alonzo RT. Fractures of the odontoid process of the axis. J Bone Joint Surgery Am 1974;56(8):1663-1674.
15. Hadley MN, Brower CM, Liu SS, Sonntag VK. New subtype of acute odontoid fractures (Type IIA). Neurosurgery 1988; 22(1 Pt1):67-71.
16. Grauer JN, Shafi B, Hilibrand AS, et al. Proposal of a modified, treatment oriented classification of odontoid fractures. Spine J 2005;2(2):123-129.
17. David MP, Mark NH. Axis fracture. Neurosurgery 2010;66: A68-A82.
18. Greene KA, Dickman CA, Marciano FF, Draiber JB, Hadley MN, Sonntag VK. Axis fractures: analysis of management and outcome in 340 consecutive cases. Spine (Phila Pa 1976) 1977;22(16):1843-1852.
19. Clark CR, White AA 3rd. Fractures of the dens, a multi center study. J Bone Joint Surg Am 1985;67(9):1340-1348.
20. Traynelis VC. Evidence based management of type II odontoid fractures. Clinical Neurosurgery 1997;44:41-49.
21. Julien TD, Frankel B, Traynelis VC, Ryken TC. Evidence based analysis of odontoid fracture management. Neurosurg Focus 2000;8(6):e1.
22. Polin RS, Szabo T, Bogaev CV, Replogle RE, Jane JA. Non-operative management of type II and III odontoid fractures. The Philadelphia Collar versus Halo vest. Neurosurgery 1996;38(3): 450-457.
23. Wang GJ, Mabie KN, Whitchill R, Stamp WG. The non-surgical management of odontoid fractures in adults. Spine (Phila Pa 1976) 1984;9(3):229-230.
24. Chiba K, Fujimura Y, Toyama Y, Fuji E, Nakanishi T, Hirabayashi K. Treatment protocols for fracture of the odontoid process. J Spinal Disord 1996;9(4):267-276.
25. Pepin JW, Bourne RB, Haxkins RJ. Odontoid fractures with special references to the elderly patient. Clin Orthop 1985;193: 178-183.
26. Fuji E, Kobayashi K, Hirabayashi K. Treatment in fractures of the odontoid process. Spine (Phila Pa 1976) 1988;1316:604-609.
27. Lind B, Nordwall A, Sihlbom H. Odontoid fractures treated with Halo Vest. Spine (Phila Pa 1976) 1987;12(2):173-177.
28. Maiman DJ, Larson SJ. Management of odontoid fractures. Neurosurgery 1982;11(4):471-476.
29. Hadley DF, O'Day J, Mendelsohn RA. Cervical injuries suffered in automobiles crashes. J Neurosurgery 1981;54(3):316-322.
30. Dunn ME, Seljeskog EL. Experience in the management of odontoid process injuries. An analysis of 128 cases. Neurosurgery 1986;18(3):306-310.
31. Ekong CE, Schwartz ML, Tator CH, Rowed DW, Edmonds VE. Odontoid fracture management with early mobilization using halo device. Neurosurgery 1981;9(6):631-637.
32. Lennarson PJ, Mostafavi H, Traynelis VC, Walters BC. Management of type II dens fractures, a case control study. Spine (Phila Pa 1976) 2000;25(10):1234-1237.
33. Gallie WL. Fractures and dislocations of the cervical spine. Am J Surg 1939;46:495-499.
34. Tucker HH. Technical report: method of fixation of subluxed or dislocated cervical spine below C1-C2. Can J Neurol Sci 1975:2(4):381-382.
35. Magerl F, Seeman PS. Stable posterior fusion of Atlas by trans articular screw fixation. In: Kehr P. Weidner A, editors. Cervical Spine New York. NY. Springer Verlag 1987.
36. Bohler J. Screw-osteosynthesis of fractures of the dens axis (author's translation) (in German) Unfallbeilkunde 1981;84(6): 221-223.
37. Goel A, Desai KI, Muzumdar DP. Atlantoaxial fixation plate and screw method. A report of 160 treated patients. Neurosurgery 2002;51(6):1351-1357.
38. Harms J, Melcher RP. Posterior C1-C2 fusion with poly axial screws and rod fixation. Spine (Phila Pa 1976);26(22):2467-2471.
39. Wright NM. Posterior C2 fixation using bilateral crossing C2 laminar screws: case series and technical note. JS Pinal Disord Tech 2004;17:158-162.
40. Brooks AL, Jenkins EB. Atlantoaxial arthrodesis by wedge compression method. J Bone Joint Surg Am 1978;60(3):279-284.
41. Griswold DM, Albright Ja, Schiffman E, Johnson R, Southwick WO. Atlanto axial fusion for instability. J Bone Joint Surg Am 1978;60(3):285-292.
42. Coyne TJ, Fehling MG, Wallace MC, Bernstein M, Tator CH. C1-C2 posterior cervical fusion. Long-term evaluation of results and efficacy. Neurosurgery 1995:37(4):688-693.
43. Waddel JP, Reardon GP. Atlantoaxial arthrodesis to trat odontoid fractures. Can J Surg 1983;26(3):255-257, 260.
44. Statham PO, Sullivan M, Rusel T. The Halifax, inter laminar clamp for posterior cervical fusion. Initial experience in the United Kingdom. Neurosurgery 1993;32(3):396-399.
45. Huang CI, Chen IH. Atlantoaxial arthrodesis using Halifax inter laminar clamps reinforced by vest immobilization. A long-term follow-up experience. Neurosurgery 1996;38(6):1153-1157.
46. Paramore CG, Dickman CA, Sonntag VK. The anatomic C1-C2 suitability of the C1-C2 complex for trans articular screw fixation. J Neurosurg 1996;85(2):221-224.
47. Dickman CA, Sonntag VK. Posterior C1-C2 screw fixation for atlantoaxial arthrodesis. Neurosurgery 1998;43(2):275-281.
48. Grob D, Jeanneret B, Aebi M, Markwalder TM. Atlanto axial fusion with trans articular screw fixation. J Bone Joint Surg Br 1991;73(6):972-976.
49. Grob D, Crisco JJ 3rd, Punjabi M, Wang P, Dvorak J. Biomechanical evaluation of four different posterior atlantoaxial fixation techniques. Spine (Phils Pa 1976) 1992;17(5):480-490.
50. Jeanneret B, Magerl F. Primary posterior fusion C1/2 in odontoid fractures: indications, techniques and results of trans articular screw fixation. J Spinal Disord 1992;5(4):464-475.

51. Jeanneret B. Posterior trans articular screw fixation C1-C2. Tech Orthop 1994;1:49-59.
52. Suchomel P Stulik J, Klez Z, et al. Trans articular fixation of C1-C2: a multi center retrospective study [in Czech]. Acta Chir Orthop Traumatol Cech 2004;71(1):6-12.
53. Stulik J, Vyskocil T, Sebesta P, Kryl J. Atlantoaxial fixation using the poly axial screw rod system. Eur Spine J 2007;16(4): 479-484.
54. Starr JK, Eismont FJ. Atypical Hangman's fracture. Spine (Phila Pa 1976) 1993;18(14):1954-1957.
55. Goel A, Laher V. Plate and screw fixation for atlantoaxial subluxation. Acta Neuro Chir (Wein) 1994;129(1-2):47-53.
56. Resnick DK, Benzel EC. C1-C2 Pedicle screw fixation with rigid cantilever beam construct: case report and technical note. Neurosurgery 2002;50(2):426-428.
57. Aryan HE, Newman CB, Nottmeir EW, Acosta FL Jr, Wang VY, Ames CP. Stabilization of the atlantoaxial complex via C1 lateral mass and C2 pedicle screw fixation in a multi center clinical experience in 102 patients: modification of Hams and Goel technique. J. Neurosur Spine 2008;8(3):222-229.
58. Menendez JA, Wright NM. Techniques of posterior C1-C2 stabilization. Neurosurgery 2007;60 (1 suppl1):S103-S111.
59. Dickman CA, Crawford NR, Paramore CG. Biomechanical characteristics of C1-C2 cable fixations. J Neurosurg 1996: 85(2):316-322.
60. Naderi S, Crawford NH, Song GS, Sonntag VK, Dickman CA. Biomechanical comparison of C1-C2 posterior fixation: cable, graft and screw combinations. Spine (Phila Pa 1976) 1998;23(8): 1946-1956.
61. Richter M, Schmidt R, Claes I, Puhul W, Wilke HJ. Posterior atlantoaxial fixation: biomechanical in vitro comparison of six different techniques. Spine (Phila Pa 1976) 2002;27(16):1724-1732.
62. Claybrooks R, Kayanja M, Molks R, Benzel E. Atlantoaxial fusion: a biomechanical analysis of the two C1-C2 fusion techniques. Spine J 2007;7(6):682-688.
63. Gorek J, Acaroglu E, Breven S, Yousef A, Puttlitz CM. Constructs incorporating intra laminar C2 screws provides rigid stability for atlantoaxial fixation. Spine (Phila Pa 1976) 2005;30(13):1513-1518.
64. Lapsiwala SB, Anderson PA, Oza A, Resnik DK. Biomechanical comparison of four C1 to C2 rigid fixative techniques: anterior trans articular, posterior trans articular, C1-C2 pedicle and C1-C2 intra laminar screws. Neurosurgery 2006;58(3):516-521.
65. White AA, Punjabi MM. Clinical Biomechanics of the Spine 2nd ed. Philadelphia PA: JB Lippincott 1990.
66. Aebi M, Etter C, Coscia M. Fractures of the odontoid process. Treatment with anterior screw fixation. Spine (Phila Pa 1976) 1989;14(10):1065-1070.
67. Apfelbaum RI, Lonser RR, Veres R, Casey A. Direct anterior screw fixation for recent and remote odontoid fractures. J Neurosurg 2000;93(2 suppl):227-236.
68. Dickman CA, Sonntag VK. Surgical management of atlantoaxial non unions. J Neurosurg 1995;83(2):248-253.
69. Jenkins JD, Coric D, Branch CL Jr. A clinical comparison of one and two screw odontoid fixation. J Neurosurg 1998;89(3): 366-370.
70. Subach BR, Morone MA, Haid RW Jr, McLaughlin MR, Rodts GR, Comey CH. Management of acute odontoid fractures with single screw anterior fixation. Neurosurgery 1999;45(4):812-820.
71. Feiz-Erfan I, Klopfenstein JD, Vougioukas VI, Dickman CA. Surgical therapy for fractures and dislocations of the cranio cervical junction and upper cervical spine. In: Kim DH, Henn JS, Vaccaro AR, Dickman CA, editors. Surgical Anatomy and Techniques to the Spine. Philadelphia, PA: WB Saunders 2006;328.
72. Ryan MD, Taylao TK. Odontoid fractures in the elderly. J Spinal Disord 1993;70(1):45-49.
73. Seybold EA, Bayley JC. Functional outcome of surgically and conservatively managed dens fractures. Spine (Phils Pa 1976) 1998;23(17):1837-1846.