



## CASE REPORT

# An Unusual Asymptomatic Foreign Body at Tracheobronchial Tree

<sup>1</sup>Santosh Kumar Swain, <sup>2</sup>Sanghamitra Mishra, <sup>3</sup>Mrutunjay Dash

## ABSTRACT

Inhalation of foreign body is usually seen in children which should be promptly and immediately removed otherwise it leads to complications and death. Early detection of foreign bodies is essential to safe removal. Management approach has to be systematic. Preoperative history taking, radiological assessment followed by rapid intervention by skilled bronchoscopist usually results in favorable outcome. We here report an interesting and an unusual presentation of a sharp and long iron nail in trachea and right bronchus, which was expelled spontaneously after coughing.

**Keywords:** Foreign body, Tracheobronchial tree, Iron nail.

**How to cite this article:** Swain SK, Mishra S, Dash M. An Unusual Asymptomatic Foreign Body at Tracheobronchial Tree. *Int J Phonosurg Laryngol* 2014;4(1):40-42.

**Source of support:** Nil

**Conflict of interest:** None

## INTRODUCTION

Foreign bodies of the airways always puzzled and mystified to the otorhinolaryngologists. Its identification and management have posed a great challenge. Foreign body aspiration is one of the leading causes of accidental death, especially in children. Different types of foreign bodies in the tracheobronchial tree have been reported and they include organic/inorganic and metallic/non-metallic. Foreign body can only enter the air passage if there is some interference with normal reflex action, such as sudden inspiration while eating, playing, fright or laughter.<sup>1</sup> The incidence of foreign bodies occurs most commonly in children population especially in their first 6 years of life<sup>2,3</sup> with peak incidence in children between age of 1 and

3 years.<sup>4,5</sup> Children are naturally vulnerable to be involved in foreign body mishap due to lack of molar teeth, the tendency to oral exploration and to play during the time of ingestion and poor coordination during swallowing.<sup>5,6</sup> Long iron nail in the air passage is rare one and life-threatening. Here we reported a case of long iron nail in the tracheobronchial tree without any symptoms in a 2 years child. The investigation and treatment of this unusual foreign body is discussed. This case is very interesting and uncommon to see such a long sharp foreign body which was lying in tracheobronchial tree with no clinical presentation and is expelled out spontaneously during cough. It is quite an unusual incidence and most unlikely to be thought about.

## CASE REPORT

A 2-year-old male child referred from pediatric casualty to ENT OPD with history of accidental inhalation of long metallic iron nail 1 day back. The event was informed to the parents by another child with age of 4 years. There were no symptoms like difficult feeding, vomiting, cough, respiratory distress and excessive crying. X-ray chest (Figs 1 and 2) revealed a long iron nail in the trachea and blunt end at the right bronchus. Auscultation did not reveal any signs of obstruction and his other ENT and routine tests were normal. As there were no symptoms of airway obstruction we had planned first diagnostic esophagoscopy followed by rigid bronchoscopy under general anesthesia, where no foreign body found in esophagus. Through endotracheal tube fiberoptic bronchoscope introduced, foreign body was confirmed as a pulsatile mass at the lower part of the trachea. Then we planned for rigid bronchoscopy for removal of foreign body. Just after extubation and before doing bronchoscopy, patient coughed forcefully, so that the iron nail (Fig. 3) with length of 8 cm come out to oral cavity. The diagnostic rigid bronchoscopy (3.5 mm size) was just performed for checking any injury in tracheobronchial wall. Postoperatively child was fine. Child was discharged after 24 hours of observation.

## DISCUSSION

A foreign body is an object or a substance foreign to the location where it is found.<sup>7</sup> Foreign body aspiration is a common occurrence and carries significant morbidity and

<sup>1,3</sup>Associate Professor, <sup>2</sup>Professor

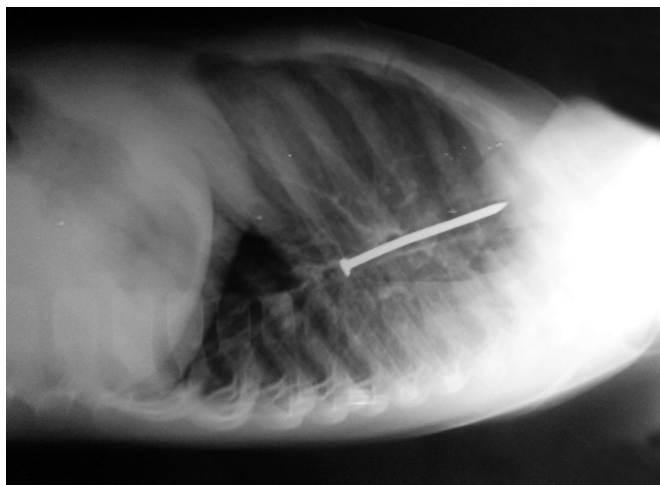
<sup>1</sup>Department of ENT, Institute of Medical Sciences and SUM Hospital, Bhubaneswar, Odisha, India

<sup>2</sup>Department of Anesthesiology, Institute of Medical Sciences and SUM Hospital, Bhubaneswar, Odisha, India

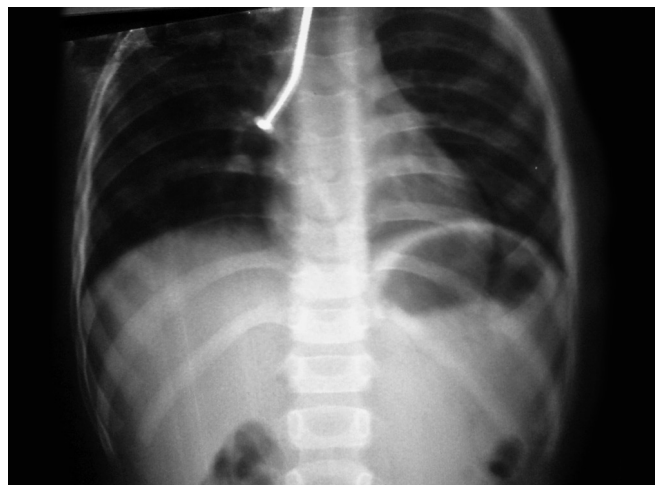<sup>3</sup>Department of Pediatrics, Institute of Medical Sciences and SUM Hospital, Bhubaneswar, Odisha, India

**Corresponding Author:** Santosh Kumar Swain, Associate Professor, Department of ENT, Institute of Medical Sciences and SUM Hospital, Bhubaneswar, Odisha, India, Phone: 067423 86292, e-mail: santoshvoltaire@yahoo.co.in






**Fig.1:** X-ray of chest (lateral view) showing iron nail



**Fig. 2:** X-ray chest (PA view) showing iron nail

mortality.<sup>8</sup> The severity of the symptoms depend upon the location, size, composition and the period for which the foreign body has been present. A variety of foreign bodies have been reported in the tracheobronchial tree. Food or food products are major airway foreign bodies, the reported incidence being as high as 70% of all foreign bodies.<sup>9</sup> Unusual foreign bodies like bubble gums, leech, broomstick, broken tracheostomy tube, etc. have also been reported. Long iron nail is very rarely reported in tracheobronchial tree as foreign body. It is necessary to screen and X-ray every patient who is admitted with a history of having swallowed a foreign body or patient who suddenly develops cough or dyspnea.<sup>10</sup> Foreign bodies always create temptation to remove immediately and land up in pushing the foreign object to the deeper area. The dictum while dealing with these foreign bodies is that one should not hurry to remove the foreign body unless proper illumination, instrumentation and expertise are available.

‘Nature cures by its own way’. Nature has developed its own reflex protective mechanism which is strong enough to handle the situation many times. It is very interesting and rare to see that such a big foreign body (long Iron nail) which was lying in trachea and right bronchus, is expelled out spontaneously with bout of cough. It is quite possible that due to administration of steroids, mucosal edema was relieved and foreign body was disimpacted. Due to its movements within tracheobronchial tree and stimulation during removal of endotracheal tube after esophagoscopy, airway was stimulated and severe bout of cough produced which was strong enough to cause the foreign body to be expelled all the way from right bronchus and trachea to oral cavity. Spontaneous expulsion of foreign body from tracheobronchial tree is unimaginable and quite rare. There are very few reports available in the literature for spontaneous expulsion of foreign body. Negus<sup>11</sup> reported



**Fig. 3:** Iron nail recovered from tracheobronchial tree

an incidence of about 2% of spontaneous expulsion of foreign body from airway while it has been quoted to vary between 2 and 4% by Chevalier Jackson.<sup>12</sup>

It is unwise and dangerous and inadvisable to wait for spontaneous expulsion in cases of foreign body bronchus.<sup>13</sup> As subglottis is the narrowest part of the upper respiratory airway in children, there is always a risk during spontaneous expulsion of foreign body from tracheobronchial tree. The foreign body may lodge into the subglottis and create life-threatening emergency which need urgent intervention.

Metallic foreign bodies are inert and minimally reacting than vegetable foreign body.<sup>14-16</sup> So the metallic foreign body will not produce any immediate signs and symptoms unless obstructing the airway significantly. In contrast vegetable foreign bodies are rapidly reacting, after lodging in tracheobronchial tree, these swell up blocking the air passage and producing chemical reaction and leading to respiratory distress and even pneumonitis.

The prognosis and successful outcome depends on different factors like age of the patient, presentation, surgical

and anesthetic skills. Management for removal of foreign body from airway has to be systematic. Proper history taking, preoperative radiological assessment followed by early intervention by skilled bronchoscopist usually results in favorable outcome.

It can be prevented by imparting proper education to the parents and public at large. They should be told about dangers of these accidents and eventualities.

## CONCLUSION

Absence of positive history or symptoms always create dilemma for intervention. But early diagnosis should be done by relevant X-ray or CT scan and removal by expert with appropriate instruments are key to prevent complications. Early removal of airway foreign body will save the child and reduce the mortality. It is equally important to educate the parents and caretakers not to be careless for their valuable child.

## ACKNOWLEDGMENT

Authors are thankful to Dr RN Padhy and MC Sahu, Central Research Laboratory, IMS and SUM Hospital, SOA University, for drafting this manuscript.

## REFERENCES

1. Iqbal I, Lateef M, Wani AA, Rafiq S. A rare case of foreign body bronchus: a case report. *Indian J Otolaryngol Head Neck Surg* Jul 2011;63(1):81-82.
2. Rothman BF, Boeckman CR. Foreign bodies in the larynx and tracheobronchial tree in children: a review of 225 cases. *Annal Otol Rhinol Laryngol* 1979;89(1):434-436.
3. Nandi P, Ong GB. Foreign body in the esophagus: review of 2394 cases. *Br J Surg* 1978;65(1):5-9.
4. Wal Pak M. A prospective study of foreign body ingestion in 311 children. *Int J Pediatr Otorhinolaryngol* 2001;58(1):37-45.
5. Fernandez JI, Gutierrez SC, Alvare J MV, et al. Foreign body aspiration in childhood- a report of 210 cases. *Ann Esp Paediatr* 2000;53(4):335-338.
6. Higo R, Matsumoto Y, Ichimura K, Kaga K. Foreign bodies in the aerodigestive tract in pediatric patients. *Auris Nasu Larynx* 2003;30(2):397-401.
7. Jackson C. *Bronchoesophagology*: WB Saunders; 1951. p. 13-34.
8. Yadav SPS, Asruddin, Yadav RK, Singh J, Gathwala G. Esophageal foreign body in four month old infant. *Indian J Otolaryngol Head Neck Surg* 2003 October;55(4):288-289.
9. Singh H, Parakh A. Tracheobronchial foreign body aspiration in children. *Clin Ped* 2014;53(5):415-419.
10. Shah KU, Kherwala SDD, Pardiwala HA. A bronchial foreign body producing dysphagia. *Indian J Otolaryngol Head Neck Surg* 1968;20s:38-40.
11. Negus VE. *Diseases of nose and throat*. Cassell and Co. Ltd., London; 1948.
12. Jackson and Jackson. *Diseases of nose, throat and ear* 2nd ed. WB Saunders Co, Philadelphia and London 1959.
13. Gupta SK, Mundra RK, Goyal A. Spontaneous expulsion of an interesting long standing metallic foreign body from left main bronchus. *Indian J Otolaryngol Head Neck Surg* 2004; 56(3):233-234.
14. Jackson C, Jackson CL. *Disease of the Air and Food Passage of foreign body origin*. Philadelphia: Saunders; 1950. p. 13-34.
15. Holinger PH, Holinger LB. Use of the open tube bronchoscope in the extraction of foreign bodies. *Chest (Supplement)*,73,721 Scoot. 4th ed. *Brown disease of ENT* 1979;4:634.
16. Harboyan G, Nassif R. Tracheobronchial foreign bodies: a review of 14 years experience, *J Laryngol Otol* 1970;84:403-412.