



CASE REPORT

An Unsafe Foreign Body at an Unsafe Site of Airway

¹Santosh Kumar Swain, ²Sidhartha Mohanty, ³Ishwar Chandra Behera

ABSTRACT

Aspiration of foreign bodies into the airway is a serious problem in childhood. Children with less attention at an early age are more prone to ingest or inhale foreign bodies. Diagnosis is often difficult due to parental ignorance and lack of a clear history. The present authors have come across a rare case of an open safety pin with its blunt end inside the larynx and sharp end penetrating the interarytenoid membrane and entering the upper part of esophagus. The foreign body was removed successfully without any complications.

Keywords: Foreign body, Direct laryngoscope, Larynx, Open safety pin, Esophagus.

How to cite this article: Swain SK, Mohanty S, Behera IC. An Unsafe Foreign Body at an Unsafe Site of Airway. *Int J Phonosurg Laryngol* 2014;4(1):17-19.

Source of support: Nil

Conflict of interest: None

INTRODUCTION

Foreign body is an object or a substance foreign to the location where it is found.¹ Since time immemorial, the problems of foreign bodies, their identification and management have posed a great challenge. Different types of foreign bodies have been reported in the airway, both organic and inorganic, metallic and nonmetallic. Safety pins are rare in the air passage, especially an open one. They account for less than 3% of all foreign bodies found in the tracheobronchial tree² and 1.5% of those found in the esophagus.³ Management of safety pins, particularly an open one is a challenging task which requires a very meticulous and cautious approach. Optimum care must be taken during removal to prevent dislodgment to distal areas and to prevent further injury. The correct management of an open safety pin in the air passage still remains an

enigma to the otorhinolaryngologists.⁴ Here, we report the case of an open safety pin, where the blunt end was inside the larynx and the sharp end was puncturing the interarytenoid area with the entering into the upper part of esophagus.

CASE REPORT

A 6-year-old, mentally retarded, girl presented in the ENT OPD with complaints of hoarseness of sudden onset. It was nonprogressive for the prior 3 days. She also complained of pain during swallowing over the same duration. There was no history of respiratory distress or of any choking spells.

Oral cavity and oropharyngeal examinations and indirect laryngoscopy were difficult to perform as she was highly uncooperative. On questioning, the parents gave no history of foreign body aspiration. X-ray neck, antero-posterior and lateral views, revealed a radio-opaque shadow corresponding to an open safety pin (Figs 1A and B), with blunt end inside the laryngeal inlet and sharp end penetrating into upper part of esophagus.

The patient was taken up for foreign body removal under general anesthesia. The anesthesiologist was planning to introduce a smaller size endotracheal tube by the side of the foreign body but due to fear of dislodgment of safety pin into trachea, patient was maintained on spontaneous respiration while sedation was deepened with intermittent intravenous propofol.

Direct laryngoscope was introduced and fixed in position. The safety pin was visualized and the radiological finding confirmed. The joint area of the open safety pin was visualized, which was then manipulated and removed (Fig. 2) using a crocodile forceps. Adrenaline (1:10,000) nebulization was done in the postoperative care unit. Hoarseness and throat irritation subsided within 72 hours. Patient was discharged on oral antibiotics and oral prednisolone for 1 week.

DISCUSSION

Airway foreign bodies should be considered in the differential diagnosis of a stridulous child and should be diagnosed promptly as they can lead to death.⁵ Impaction of foreign bodies in the larynx is commoner in children who usually present with acute respiratory distress. They usually lie in the trachea or in the bronchus. Foreign bodies in

^{1,3}Associate Professor, ²Professor

¹Department of ENT, Institute of Medical Sciences and SUM Hospital, Bhubaneswar, Odisha, India

²Department of Anesthesiology, Institute of Medical Sciences and SUM Hospital, Bhubaneswar, Odisha, India

³Department of Emergency Medicine, Institute of Medical Sciences and SUM Hospital, Bhubaneswar, Odisha, India

Corresponding Author: Santosh Kumar Swain, Associate Professor, Department of ENT, Institute of Medical Sciences and SUM Hospital, Bhubaneswar, Odisha, India, Phone: 06742386292 e-mail: santoshvoltaire@yahoo.co.in

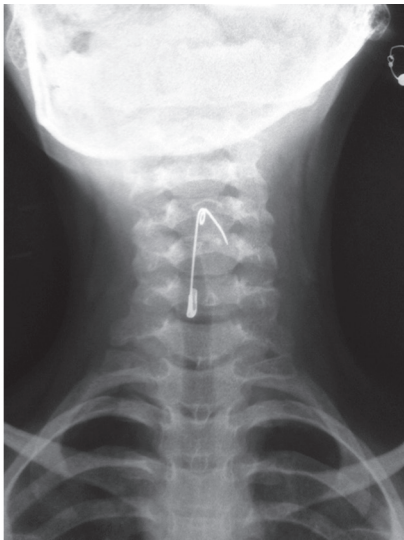


Fig. 1A: X-ray neck (AP view) showing open safety pin

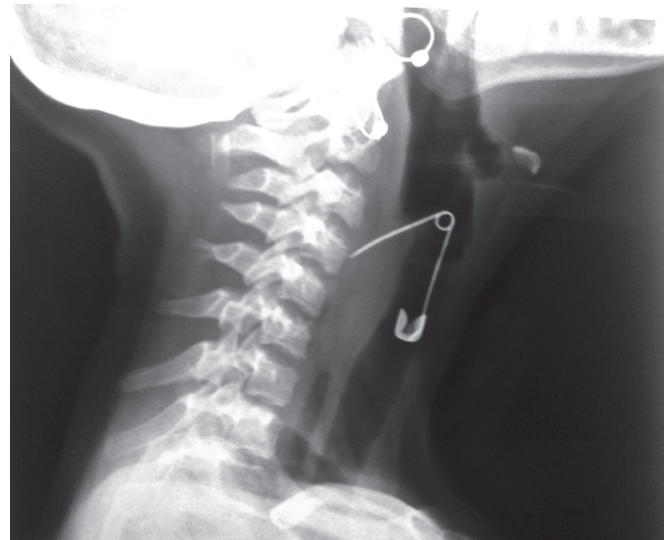

Fig. 1B: X-ray neck (lateral view) showing open safety pin

airways can present with varied symptomatology. Often history is not contributory and diagnosis depends on clinical suspicion, clinical signs and radiological findings.

Laryngeal foreign bodies are very rare as most inhaled objects pass into the bronchus (Kent and Watson 1990),⁶ Lima⁷ in a review of 91 inhaled foreign bodies found 11 to be at the true glottis. A total of five out of these 11 had fatal outcome and transient hypoxic encephalopathy occurred in another three patients. Similarly, Rothman and Boeckman⁸ found only 5 cases of laryngeal foreign bodies in a series of 225 patients. In many cases of laryngeal foreign bodies, history of choking followed by a transient cough was seen. A foreign body lodged in the larynx can lead to laryngospasm and complete respiratory obstruction.

Metallic foreign bodies in the larynx are rare. Hussain et al⁹ reported a case of open safety pin in the larynx in a 6-month-old boy, which was removed under inhalational anesthesia without intubation/tracheostomy. They have suggested the use of a suction tube into which the sharp end of the safety pin could be inserted, prior to being brought out, as a useful method.

Metallic foreign bodies of airways as compared to vegetative ones are inert and minimally reacting. As a result, these do not produce any immediate clinical manifestations unless obstructing the airway significantly. In contrast, vegetative foreign bodies are fast reacting. After lodging in the airway, they swell up, blocking the passage and producing chemical reaction leading to pneumonitis.¹⁰ Ambu et al¹¹ have reported a case of a laryngeal foreign body neglected for one and half months in a 3-year-old boy. This delay in diagnosis was because of paucity of symptoms. The foreign body was a bird bone, which was seen on plain X-ray of the neck and was removed by direct laryngoscopy partially. Tracheostomy

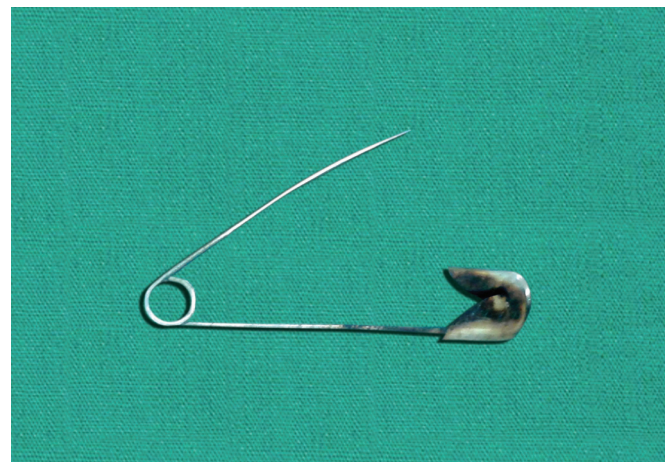


Fig. 2: Removed open safety pin

was required for stridor due to granulation tissue covering the laryngeal inlet. Remainder of the bone was removed through tracheostomy.

Difficulties during removal of airway foreign bodies are related to technical factors in grasping them, inaccessibility of site of their lodgement or inflammatory changes making their visualization difficult. If foreign body gets dislodged to the lower airway, it may cause complications like recurrent pneumonia, lung abscess, bronchiectasis, infiltrations and effusion.¹²

Incidence of foreign bodies is more among children. They explore their world by introducing objects in their mouth and nose.¹³ Children have the habit of putting things in their mouth to determine their taste and texture and also to chew on when teething. In the rural areas, the small children are in care of older siblings. Negligence and illiteracy, talking while eating, mental infirmity, alcohol ingestion, and wearing dentures when asleep are some of the contributing factors for foreign body aspiration.¹⁴

CONCLUSION

Aspiration of foreign body is a preventable mishap. Open safety pin is the most dangerous and challenging foreign body in the larynx. It can be prevented by imparting proper education to the parents and public at large. They should be told about dangers of these accidents and eventualities. Optimum care should be provided to the mentally retarded children by parents.

REFERENCES

1. Jackson, Chevalier. Bronchoesophagology. Philadelphia: WB Saunders Co; 1951; p. 13-34.
2. Casuey AL, Tallon DS, Miller RC, Warner ET. A reported safety pin requiring thoracotomy-report of a rare case and review. *PediatrEmerg Care* 1997;13(6):397-400.
3. Goel HC, Yadav SPS, Kohile GS, Singh J. Oesophagus foreign bodies. *Indian J Otolaryng Head Neck Surg* 1989;18:49-52.
4. Sen I, Sikder B, Sinha R, Paul R. Open safety pin in nasal cavity. *Indian J Otolaryngol Head Neck Surg* 2004;56(2):129-131.
5. Bakshi J, Mann SBS, Gupta AK. Unusual presentation of laryngeal foreign bodies-report of two rare cases. *Indian J Otolaryngol Head Neck Surg* 2007;59(3):252-254.
6. Kent SE, Watson MG. Laryngeal foreign bodies. *J LaryngolOtol* 1990;104(2):131-133.
7. Lima JA. Laryngeal foreign bodies in children: a persistent life-threatening problem. *Laryngoscope* 1989;99(4):415-420.
8. Rothmann BF, Boeckman CR. Foreign bodies in the larynx and tracheobronchial tree in children. A review of 225 cases. *Ann OtolRhinolLaryngol* 1980;89(5):434-436.
9. Hussain SS, Raine CH, Caldicott LD, Wade MJ. An open safety pin in the larynx: a case report. *J LaryngolOtol* 1994; 108(3):254-255.
10. Narwani S, Bora MK, Samdhani S, Sharma MP, Bapna AS. Foreign body in the bronchus: an unusual presentation. *Indian J Otolaryngol Head Neck Surg* 2005;57(2):161-162.
11. Ambu VK, Narayanan P, Rathnasingam V. Neglected laryngeal foreign body. *J Laryngol Otol* 2001;115(9):740-742.
12. Patnaik S, Raidu R. Inhaled foreign body. *Asian J Ear, Nose & Throat* 2004;2(3).
13. Freidman CM. Tracheobronchial foreign bodies. *Otolaryngol Clin North Am* 2000 Feb;33(1):79-83.
14. Dasgupta KS, Lanjewar KY, Joshi SV. Safety pin- The unsafe foreign body of air passage. *Indian J Otolaryngol Head Neck Surg* 2006;58(4):387-388.