

Laparoscopic Orchidopexy without Division of Spermatic Vessels using a Neinguinal Canal Approach: A Single Center Experience

Ved Bhaskar, Manash Ranjan Sahoo

ABSTRACT

Introduction: About 1 to 2% of boys at age of 1 year have an undescended testis (UDT); almost 20% of UDT are nonpalpable. Several surgical procedures have been described but there are no formal guidelines for the management of boys with nonpalpable testis. We report our experience with laparoscopic orchiopexy performed without dividing the spermatic vessels in this case series over a period of 4 years stating that the Fowler-Stephens technique is no longer indicated for the treatment of the intra-abdominal testis.

Materials and methods: Over a period of 7 years from 2005 to 2012, we carried out diagnostic laparoscopy on 50 nonpalpable intra-abdominal testis in 45 boys followed by laparoscopic orchiopexy without sectioning the spermatic vessels even in cases where testis was higher up (30 cases). The technique consisted in sectioning the gubernaculum, opening the peritoneum laterally to the spermatic vessels, and mobilizing the testicular vessels and the vas deferens in a retroperitoneal position for 8 to 10 cm. The testis was then brought down into the scrotum through a neo-inguinal ring created just lateral to medial umbilical ligament.

Results: Out of 45 cases with 50 undescended testis, 30 testes were abdominal, away from the internal ring out of which we were able to bring 28 testis in the scrotum without dividing the spermatic vessels, using a neo-inguinal ring. The other two patients had to undergo orchidectomy because of atretic testis. In the remaining 20 cases, the testis was at the inguinal ring or close to it and mobilized easily through the neo-inguinal ring to scrotum. The mean follow-up period has been 14 months (6 months to 2 years) and all the testes were found to be in scrotum with no atrophy.

Conclusion: On the basis of our experience, we believe that laparoscopic orchiopexy without division of the spermatic vessels should be the treatment of choice in the management of nonpalpable testes because it does not compromise the normal testicular vascularization. Creation of neo-inguinal canal lateral to the medial umbilical ligament has the advantage of gaining more length on the vessels and vas to bring the testis to scrotum and hence Fowler-Stephens procedure is no longer routinely indicated in management of high abdominal testis.

Keywords: Neo-inguinal ring, Laparoscopic orchidopexy, Undescended testis, Subdartos pouch.

How to cite this article: Bhaskar V, Sahoo MR. Laparoscopic Orchidopexy without Division of Spermatic Vessels using a Neo-inguinal Canal Approach: A Single Center Experience. *World J Lap Surg* 2013;6(3):121-126.

Source of support: Nil

Conflict of interest: None declared

INTRODUCTION

Cryptorchidism is a common urological problem with 1 to 2% of boys at age of 1 year having an undescended testis (UDT); this disorder is unilateral in about 90% of individuals and bilateral in about 10%. Almost 20% of undescended testes are nonpalpable.¹ Important potential long standing effect of cryptorchidism include infertility and testicular cancer.

The importance of a descended testis has been known since ancient times, but the mechanism of descent remained obscure until 1786 when Hunter dissected the human fetus and found the intra-abdominal testis connected to the inguinal-abdominal wall by a ligament called gubernaculum testis because it appeared to guide the testis to the scrotum.² Numerous factors interact to effect normal testicular development and descent including endocrine, paracrine, growth and mechanical factors. Any abnormality in this process can result in an undescended testis, which carries fertility and malignancy implications. Infact recent studies even show a relation of genitofemoral nerve to descent of testis in mice models.³

UDT is defined as a testis that cannot be manipulated to the bottom of the scrotum without undue tension on the spermatic cord. There is variability in nomenclature relating to UDT but the clearest classification is palpable and nonpalpable testis.⁴

UDT are usually evaluated and managed by imaging methods and surgery, respectively.¹ Management of the nonpalpable testis is a diagnostic and therapeutic challenge. The diagnostic difficulty involves determining if such a testis is present and, if so, its location and further management. Laparoscopy was first used in 1976 to locate UDT.⁵

Treatment of the patient with abdominal testis is controversial. Difficulty in mobilization, as well as significant complications including atrophy, have led to a multitude of approaches to this dilemma.⁶ This scenario is not new, and all pediatric surgeons are familiar with the numerous procedures available to treat these patients, including staged orchidopexy, transperitoneal or retroperitoneal orchidopexy via an extended inguinal or Pfannenstiel incision, Fowler-Stephens orchidopexy in 1 or 2 stages, microvascular transplantation and laparoscopic

vessel clipping followed several months later by extended inguinal or transabdominal orchidopexy.⁷ In our current series, laparoscopic management of these testes yielded success in 48 of the 48 cases (100%). Orchidectomy was done for the remaining two patients as they had atrophied testes and they belonged to postpubertal age group.

In our series, technique consisted in sectioning the gubernaculum (when present), opening the peritoneum laterally to the spermatic vessels, and mobilizing the testicular vessels and the vas deferens in a retroperitoneal position for 8 to 10 cm. In our technique the vas avoided going around the inferior epigastric vessels, thereby gaining at least 2 to 3 cm of extra length. This route gives a direct approach to the scrotum. So by using this neo-inguinal canal route we could mobilize all the testes to scrotum. The greater degree of success with the laparoscopic procedure may be because of the magnification used which may have led to better preservation of small collateral vasculature.

MATERIALS AND METHODS

This procedure was carried out in Department of General Surgery, SCB Medical College, Cuttack over a period of 7 years from 2005 to 2012 using laparoscopic approach and patients were followed up regularly. Then a retrospective analysis after collection of all the data from medical records was done. One important point to be noted here is that the main author being a general surgeon usually got cases which were of somewhat higher age group as compared to most other studies which are conducted in pediatric surgery departments. Most of the cases were postpubertal males in whom testis was nonfunctional. They had mainly come for psychological and cosmetic reasons.

A risk bond for surgery and a formal consent for orchidectomy were taken in all cases. The bladder was emptied using a urethral catheter. Diagnostic laparoscopy was then performed through an optic port introduced through 11 mm supraumbilical incision. The entire abdomen was inspected and various anatomical landmarks identified. The peritoneal cavity was insufflated with carbon dioxide to a maximum pressure of 12 mm Hg. If an intra-abdominal or 'peeping' testis was found, two accessory working trocars 6 mm were placed at the level of umbilicus in the midclavicular line on either side of the abdomen under direct vision.

With gentle traction on the testis, using the harmonic scalpel the most distal gubernacular attachment was divided (Fig. 1). The peritoneum overlying the spermatic vessels is then incised. This incision frees the testicular vessels from the posterior peritoneal attachments and provides the additional length for proper mobilization of the testis into

the scrotum. Dissection was continued cranially as far as necessary to gain enough length of the spermatic vessels to allow tension free orchiopexy (Fig. 2). Then the peritoneum superior to the vas deferens was incised to gain additional vasal length. Periodically the testis was moved toward the contralateral internal ring as an average estimate of whether sufficient length had been attained to move it to the scrotum (Fig. 3).

A neo-ring was then created just lateral to the medial umbilical ligament. The endodissector was driven out of the scrotal incision, guided by an index finger invaginating the scrotum (Fig. 4). A small scrotal incision was made and a dartos pouch developed. A Kelly's forceps was introduced from the scrotal incision through this new ring into the abdomen (Fig. 5), and grasped the testis, ensuring that only the gubernacular tissue was held (Fig. 6). It is inadvisable to grab the vas or the advential tissues around the epididymis, as this can crush the delicate blood supply (Fig. 7). The neo-ring was narrowed using one or two

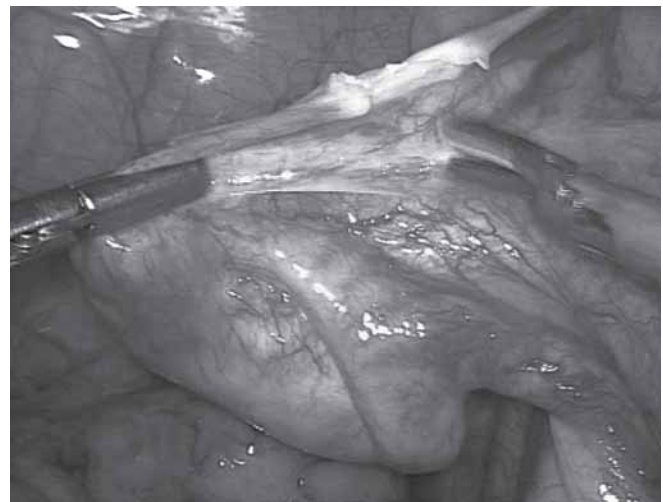

Fig. 1: Beginning of testicular mobilization

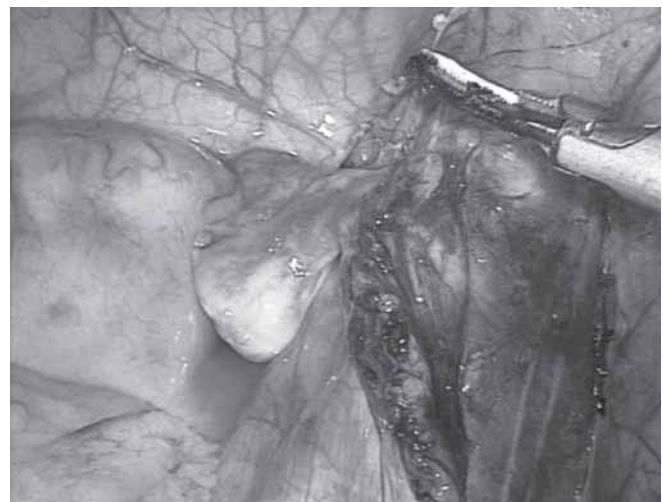

Fig. 2: Mobilization continued

intracorporeal suturing (Fig. 8). The testis was brought out into the scrotum and the length checked by deflating the abdomen (Fig. 9). Releasing the pneumoperitoneum gives

additional length that at times would obviate vessel ligation. Once the testis was freely lying in the newly created subdartos pouch, scrotal incision was closed with catgut

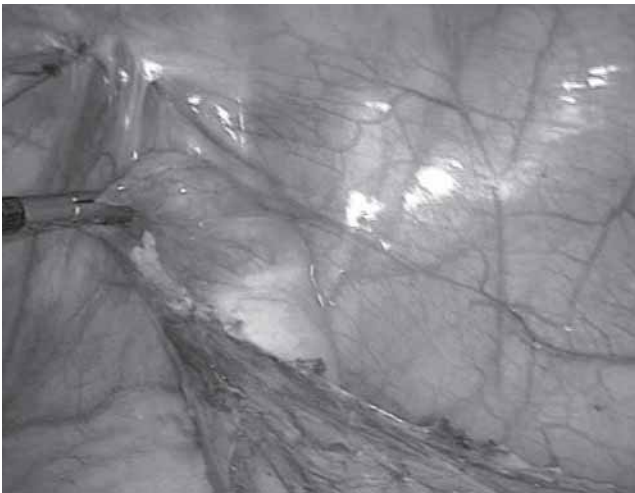


Fig. 3: Adequacy of mobilization being checked by pulling the testis to the opposite ring

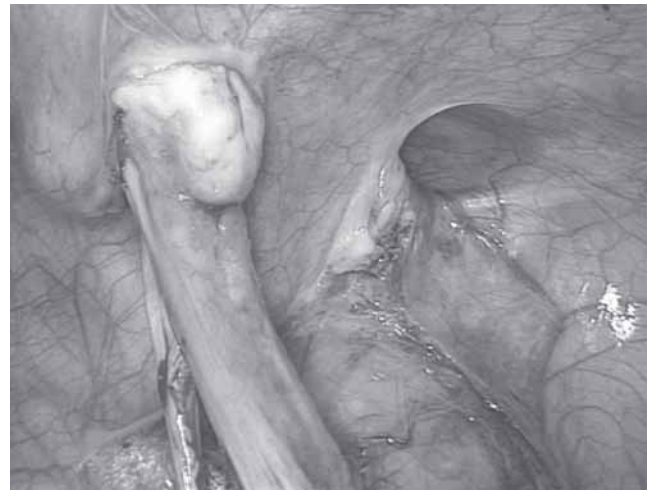

Fig. 6: Testis grasped and taken out through the new ring. The internal ring can be seen laterally

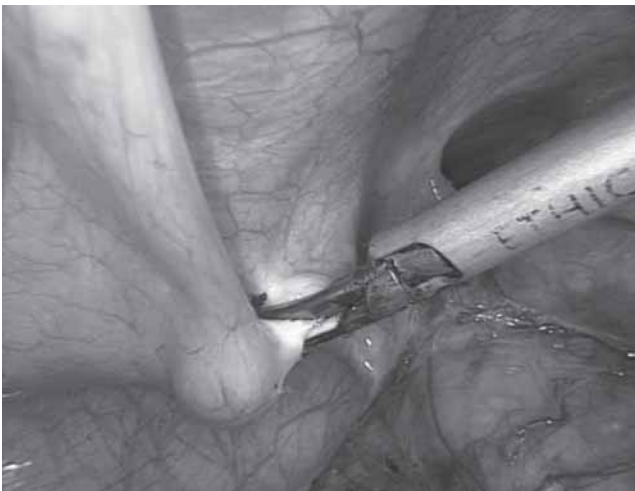


Fig. 4: Endodissector was driven out of the scrotal incision

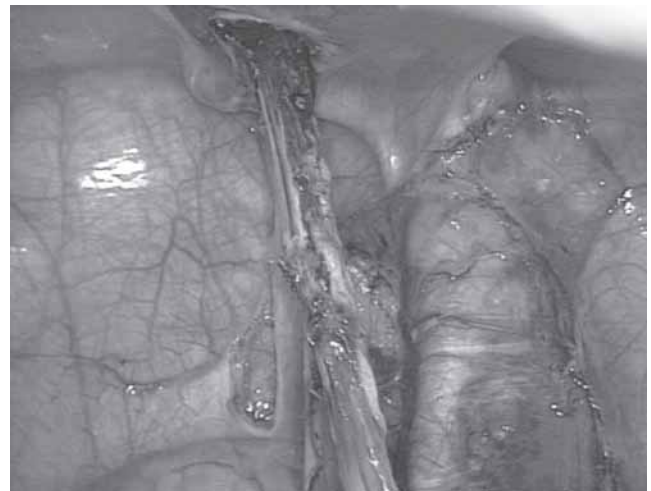

Fig. 7: Testis is entirely out through the new ring

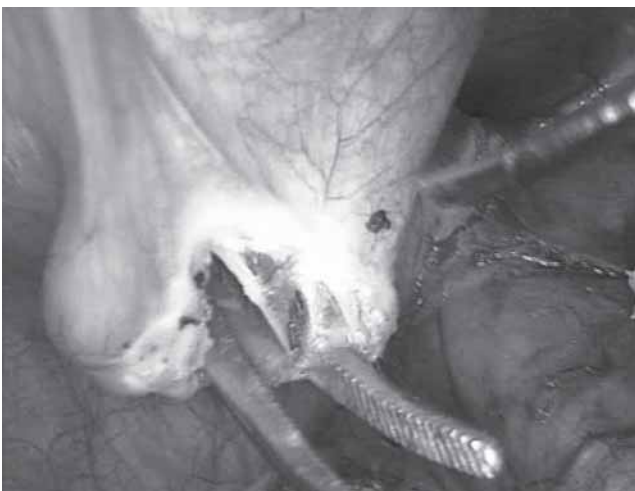

Fig. 5: Kelly's forceps was introduced from the scrotal incision through this new ring into the abdomen

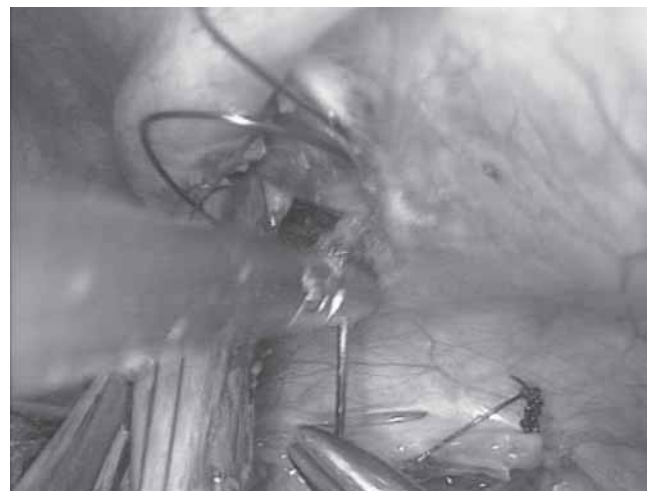

Fig. 8: The neo-ring narrowed using one or two intracorporeal suturing

(Fig. 10), and abdominal skin incision was closed with ethibond so that the patient need not come back for stitch removal. In bilateral cases, one side was dealt first followed by surgery for the other side 6 months later. Postoperatively they were started with oral feed on the next day and Doppler assessment of the gonadal vessels done to ensure good vascularity to the testis before the patient was discharged. Patients were followed up after 6 months and 1 year.

RESULTS

A total of 50 nonpalpable testes in 45 patients were taken up for diagnostic laparoscopy and the initial inspection revealed 24 testes on right side, 16 on left and 5 cases were bilateral. There were 20 testes which were in or around the internal ring while 30 were intra-abdominal with 8 testes lying proximal to iliac vessels. Two out of this 8 were atrophic and were found in postpubertal boys. Mean age of patients was 14.5 years (8-24 years). Mean operative time was 78 minutes (52-90 min). Surgery was considered successful if the testis was in scrotum without any atrophy after a period of minimum 6 months from surgery.

We could mobilize all the 48 testes to the bottom of scrotum in the subdartos pouch through the neo-inguinal ring by the above mentioned techniques and placed them securely without any tension. We did not require any spermatic vessel ligation or a two-stage operation even for testes which were located higher up, thus excluding any theoretical risk of testicular atrophy although there were difficulty mobilizing them. But with meticulous dissection higher up in the retroperitoneum and using the new route to scrotum which at least gives 2 to 3 cm extra by not going around the inferior epigastric and the inguinal canal we were successful in mobilizing even difficult cases. On two occasions we performed an orchidectomy where we found the testis to be atrophied.

We did not have any complications intraoperatively and patients were discharged next day. They were followed-up regularly. After 6 months of follow-up we did not find any retraction of testis or any atrophy. All the testis were well placed inside the scrotum and of normal size and shape.

DISCUSSION

The availability of a wide variety of therapeutic strategies to treat intra-abdominal testis indicates that the ideal technique to manage this type of pathology has not yet been found. The operations available are extended groin approach,⁸ preperitoneal exploration,⁹ two-stage or one-stage Fowler-Stephen method,^{10,11} microvascular transplantation¹² and laparoscopic orchiopexy.¹³ Orchiopexy by high division of testicular vessels may carry a high incidence (10%) of testicular atrophy.¹⁴ The experience with microvascular autotransplantation is less and the procedure is lengthy.¹² In recent years laparoscopic orchiopexy without division of spermatic vessels has been taken up by many centers.¹⁵⁻¹⁸ The main advantages of laparoscopic orchiopexy without division of spermatic vessels are that testicular vessels are well-preserved and mobilized for a longer length and that it is a minimally invasive procedure.

Scrotal testis resides in a specialized low-temperature environment with the pampiniform plexus, scrotal pigmentation, absence of subcutaneous fat. Low temperature is regulated by temperature-sensitive muscles—cremaster and dartos. All these ensure decreased temperature of the gonad. The scrotal testis in the human is maintained at 33°C compared with 34°C to 35°C noted in the inguinal region and 37°C intra-abdominally.¹⁹ The physiology of the testis is well-adapted to this lower temperature; therefore, in the undescended testis where the ambient temperature is increased the testis undergoes progressive alteration.²⁰ Germ

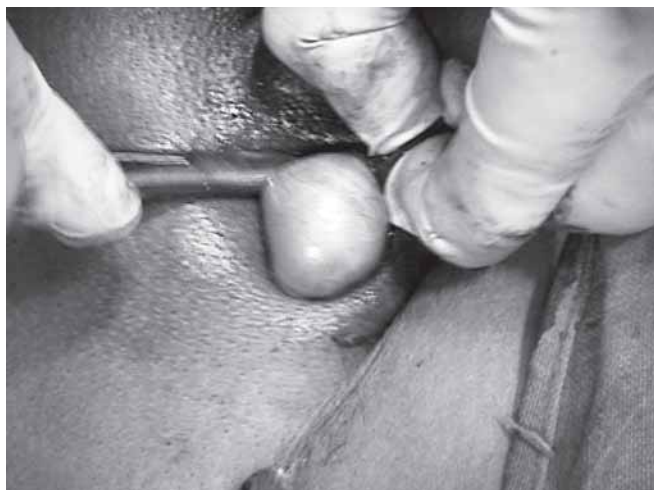

Fig. 9: Testis was brought out into the scrotum

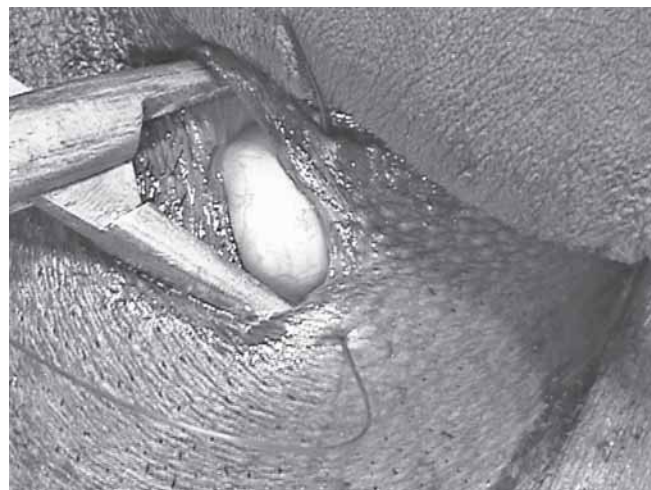


Fig. 10: Testis freely lying in the newly created subdartos pouch. Scrotal incision closed with catgut

cell deficiency in cryptorchidism was previously regarded as congenital.²¹ It has been observed that the histology of the testis is initially normal and becomes progressively abnormal with age.

More detailed studies showed impaired Leydig cells development in undescended testes in the first 2 to 6 months, whereas the Sertoli and germ cells appeared normal.²² By the end of the second year of life, nearly 40% of undescended testes had completely lost their germ cells. They concluded that germ cell deficiency in undescended testis is secondary.²² In previous generations, it was believed that the undescended testis suffered no adverse changes until after puberty and surgical intervention was not necessary until 12 to 15 years of age.²³ The evidence that germ cell maturation is already abnormal after 6 months of age has led clinicians to appreciate that not only is postnatal degeneration is important issue but also that early intervention may prevent it.

Paternity rates are not deficient in unilateral cryptorchidism; but with bilateral cryptorchidism, fertility is significantly impaired.²⁴ Data attempting to correlate fertility rates with timing of surgery are not yet available because there are no long-term studies of children undergoing orchiopey in the first year of life. The risk of developing testicular cancer is 5 to 60 times greater for men with cryptorchidism.²⁵ The increased risk may be due to an underlying genetic and hormonal etiology that causes both cryptorchidism and testicular cancer.²⁵ The association of orchiopey with decrease in cancer risk has not been demonstrated prospectively.²⁶ Nevertheless, orchiopey facilitates testicular examination and early cancer detection. Treatment of undescended testes improves fertility and endocrine function, reduces the risk of torsion and trauma, facilitates examination of testis and creates a normal-appearing scrotum.

The undescended testis is unlikely to descend after age of 9 to 12 month of age. For some years, orchiopey has been recommended in the second year of life, but now orchiopey is recommended at 6 months of age. This is because the first sign of damage to the testes are identified at about 6 months of age.²⁷ The mainstay of therapy for the palpable undescended testes is surgical orchiopey with creation of a subdartos pouch.

CONCLUSION

On the basis of our experience, we believe that orchidopexy without division of the spermatic vessels should be the treatment of choice even for the cases of high intra-abdominal testis because this procedure does not affect normal testicular vascularization and eliminates any theoretical risk of devascularization and later atrophy of the

testes so intimately related to Fowler-Stephens technique. And specially with the use of laparoscopy where extensive retroperitoneal dissection can be carried out under magnification and using the neo-inguinal ring we can easily mobilize all the testes to the scrotum without the need of division of spermatic vessels. Although the number of patients in our series is relatively small, our excellent success rate makes this procedure good alternative to the routine Fowler-Stephens procedure in patients with an abdominal testis.

REFERENCES

1. Abbas TO, Hayati A, Ismail A, Ali M. Laparoscopic management of intra-abdominal testis: 5-year single-centre experience—a retrospective descriptive study. *Minim Invasiv Surg* 2012; 2012:878509.
2. Hunter J. A description of the situation of the testis in the fetus, with its descend in to the scrotum. In observations on certain parts of the animal economy. London, Castle-Street Leicester Square; 1786.
3. McDougal, Scott W, Wein, Alan J, Kavoussi, Louis R, et al. *Campbell-Walsh Urology*. 10th ed. St Louis: Saunders; 2011:3543.
4. Kaplan GW. Nomenclature of cryptorchidism. *Eur J Pediatr* 1993;152 Suppl 2:S17-S19.
5. Cortesi N, Ferrari P, Zambarda E, Manenti A, Baldini A, Morano FP. Diagnosis of bilateral abdominal cryptorchidism by laparoscopy. *Endoscopy* 1976 Feb;8(1):33-34.
6. Lindgren BW, Franco I, Blick S, Levitt SB, Brock WA, Palmer LS, Friedman SC, Reda EF. Laparoscopic Fowler-Stephens orchiopey for the high abdominal testis. *J Urol* 1999 Sep;162(3 Pt 2):990-993.
7. Anand JJS, Kumaran V, Rajamani G, Kannan S, Mohan NV, Rengarajan R, Muthulingam V. Route to neo-inguinal canal: our experience. *J Minim Access Surg* 2011 Jul-Sep;7(3):178-180.
8. Kirsch AJ, Escala J, Duckett JW, Smith GH, Zderic SA, Canning DA, Snyder HM 3d. Surgical management of nonpalpable testis: the Children's Hospital of Philadelphia experience. *J Urol* 1998 Apr;159(4):1340-1344.
9. Canavase F, Cortese MO, Gennari F, Gesmundo R, Lala R, De Sanctis C, Costantino S. Nonpalpable testis: orchiopey at single stage. *Eur J Pediatr Surg* 1995 Apr;5(2):104-105.
10. Fowler R, Stephen FD. The role of testicular vascular anatomy in the salvage of the high undescended testis. *Aust N Z J Surg* 1959 Aug;29(1):92-96.
11. Esposito C, Garipoli V. The value of 2-step laparoscopic Fowler-Stephen orchiopey for intra-abdominal testes. *J Urol* 1997 Nov;158(5):1952-1955.
12. Harrison CB, Kaplan GW, Scherz HC, Packer MG, Jones J. Microvascular autotransplantation of the intra-abdominal testis. *J Urol* 1990 Aug;144(2 Pt 2):506-509.
13. Esposito C, Vallone G, Settimi A, Gonzalez Sabin MA, Amici G, Cusano T. Laparoscopic orchiopey without division of the spermatic vessel: can it be considered the procedure of choice in cases of intra-abdominal testis? *Surg Endosc* 2000 Jul; 14(7):658-660.
14. Baker LA, Docimo SG, Surer I, Peters C, Cisek L, Diamond DA, Caldamone A, Koyle M, Strand W, Moore R, et al. A multi-institutional analysis of laparoscopic orchiopey. *Br J Urol Int* 2001 Apr;87(6):484-489.

15. Diamond DA. Laparoscopic orchiopexy for intra-abdominal testis. *J Urol* 1994 Oct;152(4):1257-1260.
16. Docimo SG. The results of surgical therapy for cryptorchidism: a literature review and analysis. *Urol* 1995 Sep;154(3):1148-1152.
17. Humphrey CB, Najmaldin AS, Thomas DF. Laparoscopy in the management of the impalpable undescended testis. *Br J Surg* 1998 Jul;85(7):983-986.
18. Gaur DD, Agarwal DK, Purohit KC, Darshane AS. Laparoscopic, orchiopexy for intra-abdominal testis. *J Urol* 1995;153:479-482.
19. Mieusset R, Fouda PJ, Vaysse P, Guitard J, Moscovici J, Juskiwenski S. Increase in testicular temperature in case of cryptorchidism in boys. *Fertil Steril* 1993 Jun;59(6):13-19.
20. Job JC, Toublanc JE, Chaussain JL, Gendrel D, Garnier P, Roger M. Endocrine and immunological findings in cryptorchid infants. *Horm Res* 1988;30(4-5):167-172.
21. Scorer CG, Farrington GH. Congenital deformities of the testis and epididymis. London: Butterworths; 1971. 45 p.
22. Hadziselimovic F, Herzg B, Girard J. Cryptorchidism: histology, fertility and treatment. *Prog Reprod Bio Med* 1984;10:1-15.
23. Pike MC, Chilvers C, Peckham MJ. Effect of age at orchidopexy on risk of testicular cancer. *Lancet* 1986 May;1(8492):1264-1268.
24. Lee PA, Coughlin MT, Bellinger MF. Paternity and hormone levels after unilateral cryptorchidism: Association with pre-treatment testicular location. *J Urol* 2000 Nov;164(5):1697-1701.
25. Herrinton LJ, Zhao W, Husson G. Management of cryptorchidism and risk of testicular cancer. *Am J Epidemiol* 2003 Apr;157(7):602-605.
26. Giwereman A, Muller J, Shakkeback NE. Cryptorchidism and testicular neoplasia. *Horm Res* 1988;30(4-5):157-163.
27. Huff DS, Hadziselimovic F, Snyder HM 3d, Blyth B, Duckett JW. Early postnatal testicular maldevelopment in cryptorchidism. *J Urol* 1991 Aug;146(2 (Pt 2)):624-626.

ABOUT THE AUTHORS

Ved Bhaskar

Junior Resident, Department of General Surgery, SCM Medical College Cuttack, Odisha, India

Manash Ranjan Sahoo (Corresponding Author)

Associate Professor, Department of Surgery, SCB Medical College Cuttack, Odisha, India, e-mail: manash67@gmail.com