REVIEW ARTICLE

Role of Imaging in Dental Implants

[1]Divya Kalra, [2]Geetika Jain, [3]Abhijeet Deoghare, [4]Pravin Lambade

[1]Associate Professor, Department of Prosthodontics, Government Dental College, Rohtak, Haryana, India

[2]Postgraduate Student, Department of Prosthodontics, Government Dental College, Rohtak, Haryana, India

[3]Lecturer, Department of Oral Medicine, Chhattisgarh Dental College and Research Institute, Rajnandgaon, Chhattisgarh, India

[4]Professor, Department of Oral and Maxillofacial Surgery, Chhattisgarh Dental College and Research Institute, Rajnandgaon Chhattisgarh, India

Correspondence: Divya Kalra, Postgraduate Institute of Medical Sciences, 48/9 J, Medical Campus, Rohtak-124001, Haryana India, Phone: 09996627398, e-mail: drdivyaprostho@gmail.com

Abstract

Dental implants have become an accepted form of permanent tooth replacement. Nearly all implants currently being placed are of the osseointegrated type. These typically consist of three parts: a fixture, an abutment, and a screw or threaded rod. The fixture, usually composed of titanium, can be placed in either a surgically created site in the alveolar ridge or a fresh extraction socket. Diagnostic imaging can play an important role in evaluating patients with such implants. Useful imaging studies include plain panoramic radiography, computed tomography, and computer-reformatted cross-sectional, panoramic, and three-dimensional imaging. Advanced imaging studies can be used to determine the suitability of implant placement, appropriate sites for implant placement, the size of the implant that can be placed, and the need for preimplantation ridge surgery. Postoperatively, advanced imaging studies can show failure of an endosseous implant to osseointegrate, improper placement of an implant, and violation of important structures. This paper gives a brief insight into the various imaging modalities, which have been applied in implantology.

Keywords: Osseointegrated, fixture, endosseous implant.

INTRODUCTION

The widespread use of dental implants in partially and completely edentulous patients has brought about a need to preoperatively depict and quantify accurate bone height and contour by radiographic examination. These examinations also provide information about the locations of vital anatomic structures. The choice of radiologic technique appropriate for a given patient depends on a number of factors, including the type of implant to be used, the position of the remaining dentition and the extent to which bone quality or quantity is in question. Maximizing the ratio of the benefit/risk for imaging examinations is a fundamental tenet of radiology. These imaging modalities can be described as either analog or digital and two-dimensional or three-dimensional.[1]

DIAGNOSTIC IMAGING TECHNIQUES

Periapical Radiography (Fig. 1)

Periapical radiographs produce a high resolution planar image. Periapical radiographs may suffer from both distortion and magnification which is limited by using long cone paralleling technique. In terms of the objectives of preprosthetic imaging, periapical radiography is:[2]

1. A useful for ruling out local bone or dental disease.
2. Of limited value in determining quantity because the image is magnified, may be distorted, and does not depict the third dimension of bone width.
3. Of limited value in determining bone density or mineralization.
4. Of value in identifying critical structures, but of limited value in depicting the spatial relationship between the structures and the proposed implant site.[2]

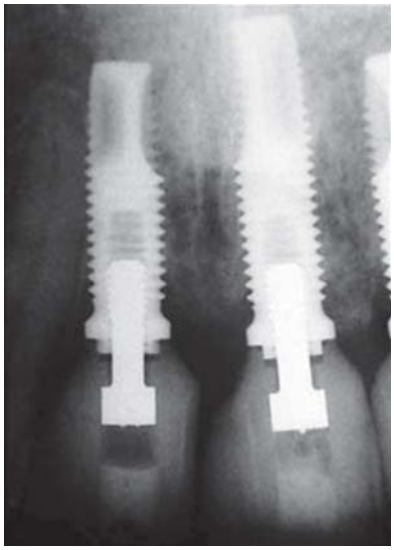

Fig. 1: Periapical radiographs: Implants 11, 21, 22, screw-retained ceramic abutments

5. Most often used for single tooth implants in regions of abundant bone width.

Occlusal Radiography (Fig. 2)

Occlusal radiographs are planar radiographs. Occlusal radiography produces high resolution images. Produces an oblique and distorted image of the mandibular and maxilla , which is of little use. In addition, it shows the widest width of bone *vs* the width at the crest, where diagnostic information is needed most. The degree of mineralization of trabecular bone can be not determined, and the spatial relationship between the critical structures and the proposed implant site is lost. Rarely

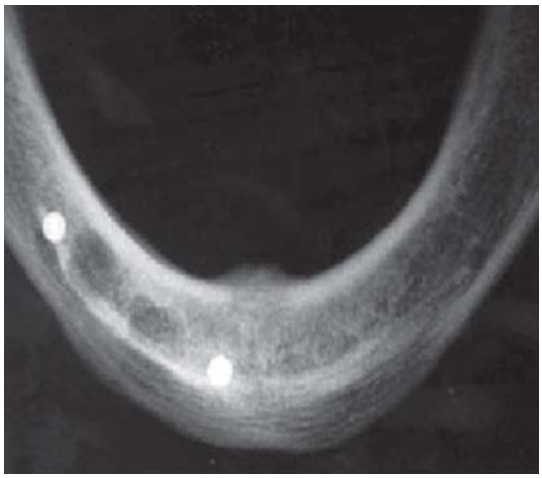

Fig. 2: Occlusal radiograph showing surgical guide

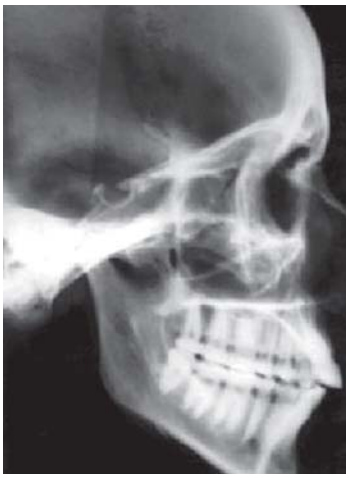

Fig. 3: Lateral cephalometric

indicated for diagnostic preprosthetic phases in implant dentistry.

Lateral Cephalometric Radiographs (Fig. 3)

Cephalometric radiographs are oriented planar radiographs of the skull. The skull is oriented with respected to the X-ray device and the image receptor using a cephalometer, which physically fixes the position of the skull with projections into the external auditory canal. The geometry of cephalometric imaging devices results in a 10% magnification of the image with a 60 inch focal object and 6 inch object to film distance. A cross-sectional image of the alveolus in the midsagittal plane is demonstrated by this lateral cephalometric radiograph. The cross-sectional view of the alveolus demonstrates the spatial relationship between occlusion and esthetics with the length, width, angulation, and geometry of the alveolus and is more accurate for bone quantity determination. The lateral cephalometric radiograph is useful because it demonstrates the geometry of the alveolus in the anterior region and the relationship of the lingual plate to the patient's skeletal anatomy. The width of the bone in the symphysis region and the relationship between the buccal cortex and the roots of the anterior teeth may also be determined before harvesting this bone for ridge augmentation. Spatial information is available to demonstrate the geometry of the implant site and the critical structures. Loss of vertical dimension, skeletal arch interrelationship, anterior crown-implant ratio, anterior tooth position in the prosthesis and resultant moment of forces. As a result, cephalometric radiographs are a useful tool for the development of an implant treatment plan, especially for the completely edentulous patient. However, this technique is not useful for demonstrating bone quality. It provides more accurately the information on inclination, height and width of alveolar bone at the midline, when compared to panoramic radiographs.[1] Image resolution is less when compared to intraoral radiographs.[2]

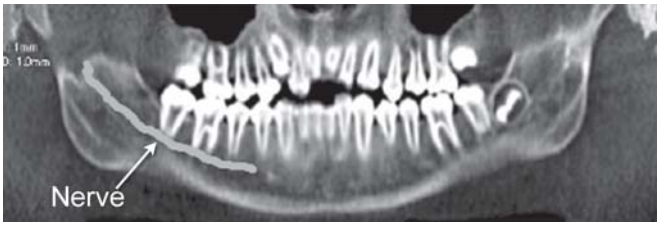

Fig. 4: Panaramic view (2-dimension)

Panoramic Radiography (Fig. 4)

Panoramic radiography is a curved plane tomographic radiographic technique used to depict the body of the mandible, maxilla, and the lower one half of the maxillary sinuses in a single image. This is the most utilized diagnostic modality in implant dentistry. This radiographic technique produces an image of a section of the jaws of variable thickness and magnification. Panoramic images offer the following advantages:

1. Opposing landmarks are easily identified.
2. Vertical height of bone initially can be assessed.
3. Can be performed with convenience, ease and speed.
4. Gross anatomy of the jaws and any related pathologic findings can be evaluated.

Shortcomings of Panoramic Imaging

1. Does not demonstrate bone quality/mineralization.
2. Misleading quantitatively because of magnification and because the third dimension, cross-sectional view is not demonstrated.
3. Of some use in demonstrating critical structures but of little use in depicting the spatial relationships between the structures and dimensional quantification of the implant site. Shows 10% magnification.

Zonography

Recently, a modification of the panoramic X-ray machine has been developed with the capability of making a cross-sectional

images of jaws. The tomographic layer is approximately 5 mm. This technique enables the appreciation of spatial relationship between the critical structures and the implant site. The tomographic layers are relatively thick and have adjacent structures that are blurred and superimposed on the image, limiting the usefulness of this technique for individual sites, especially in the anterior regions where the geometry of the alveolus changes rapidly. This technique is not useful for determining the differences in most bone densities or identifying disease at the implant site.

Fig. 5: The third-dimension "Slices" of the 2-D image turned 90°

Tomography

Tomography is a generic term formed by the Greek words 'Tomo' (slice) and 'Graph' (picture). Body section radiography is a special X-ray technique that enables visualization of a section of the patient's anatomy by blurring regions of the patient's anatomy above and below the section of interest. Different tomographic sections are produced by adjusting the position of the fulcrum or the position of the patient relative to the fulcrum in fixed geometry systems. An expert radiologist is needed to interpret the image.[3]

Linear tomography is the simplest form of tomography where the X-ray tube and film move in a straight line. This tomographic motion is one-dimensional and produces blurring of adjacent sections in one-dimension resulting in linear steak artifacts in the resulting image, which may obfuscate the section of interest. Complex motion, high quality tomography is described by two-dimensional motion of the tube and film and results in relatively uniform blurring of the regions of the patient's anatomy adjacent to the tomographic motion. The diagnostic quality of the resulting tomographic image is determined by the type of tomographic motion, the section thickness, and the degree of magnification. Hypocycloidal motion is generally accepted as the most effective blurring motion. Magnification varies from approximately 10 to 30% with higher magnification generally producing higher quality images. Dense structures may persist in the tomographic image even though they are 3 or 4 times the tomographic layer thickness distant from the tomographic section and will serve to obfuscate the structures of interest in the tomographic section. For dental implant patients, high-quality complex motion tomography demonstrates the alveolus, and taking magnification into consideration enables quantification of the geometry of the alveolus. This technique also enables determination of spatial relationship between the critical structures and the implant site. Ideally, tomographic sections spaced every 1 or 2 mm enable evaluation of the implant site region, and with mental integration, enable appreciation of the three-dimensional appearance of the alveolus. The quantity of alveolar bone available for implant placement can be determined by compensating for magnification. Aid in the determination of alveolar bone for implant placement. Image enhancement can aid in identifying critical structures. Complex tomography is not particularly useful in determining bone quality or identifying bone and dental disease.

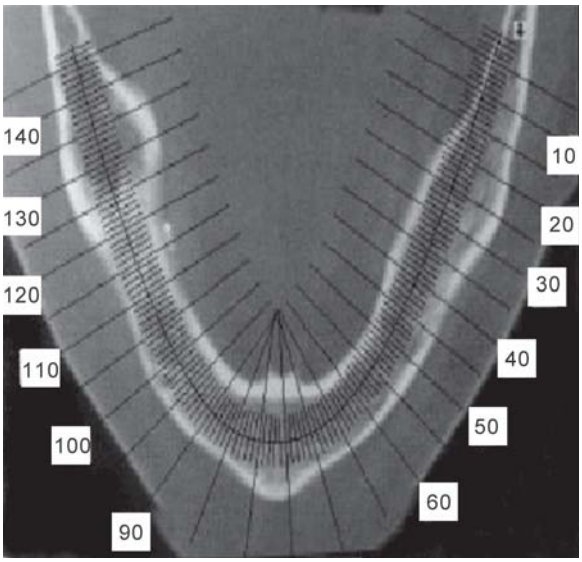

Fig. 6: CT scan showing reformatted images

Computed Tomography (Figs 5 and 6)

Computed tomography (CT) is a digital and mathematical imaging technique that creates tomographic sections where the tomographic layer is not contaminated by blurred structures from adjacent anatomy. Additionally, and probably most important, computed tomography enables differentiation and quantification of both soft and hard tissues without performing an invasive procedure on a patient. CT produces axial images of a patient's anatomy. CT images are inherently three-dimensional digital images typically 512 by 512 pixels with a thickness described by the slice spacing of the imaging technique. The individual element of the CT image is called a voxel, which has a value referred to in Hounsfield units, that describes the density of the CT image at that point. Each voxel contains 12 bits of data and ranges from –1000 (air) to + 3000 (enamel/dental materials) Hounsfield units. CT scanners are standardized at a Hounsfield value of 0 for water. CT can be used for imaging the temporomandibular joint, evaluating dental/bone lesions, assessing maxillofacial deformities, and for pre- and postsurgical evaluation of the maxillofacial region. CT provides reformatted image data to create tangential and cross-sectional tomographic images of the implant site. With current generation CT scanners, reformatted images are characterized by a section thickness of 1 pixel (0.25 mm) and an in-plane resolution of 1 pixel by the scan spacing (0.5 to 1.5 mm) producing a geometric resolution similar to that of planar imaging. The density of structures within the image is absolute and

quantitative and can be used to differentiate tissues in the region and characterize bone quality. The information provided is a life size image, which is highly desirable for ease of measurements.[2,4-6]

Recent Advances in Computed Tomography

Cone beam CT: It uses a conical beam and reconstructs the image in any direction using special software. It gives all the information of a CT but, at 1/8 th the radiation dose and at a lower cost 9.

Microtomograph, another modification of CT is especially useful in acquiring serial sections of bone-implant interface.[7]

Multislice helical CT: It offers higher accuracy of images when compared to CT< 150[8] the advantages of this type of imaging were evident and the limitations of delivery clear, which spawned the development of a number of techniques, referred to generically as 'Dentascan Imaging'.

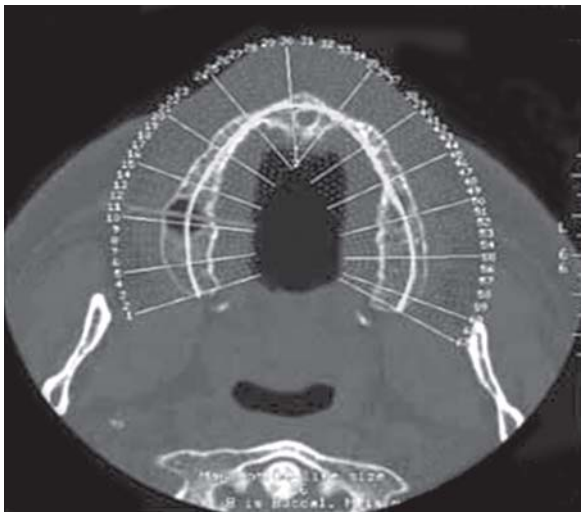

Fig. 7: Dentascan

Dentascan Imaging (Fig. 7)

Dentascan imaging provides programmed reformation, organization, and display of the imaging study. The radiologist or technologist simply indicates the curvature of the mandibular or maxillary arch and the computer is programmed to generate referenced cross-sectional and tangential/panoramic images of the alveolus along with three-dimensional images of the arch. The cross-sectional and panoramic images are spaced 1 mm apart and enable accurate preprosthetic treatment planning. Limitations of dentascan imaging include images that may not be true size and require compensation for magnification and determination of bone quality. Dentascan images only include a limited range of the diagnostic gray scale of study. This technique provides a wealth of diagnostic information that is accurate, detailed and specific. Usually, a diagnostic template is necessary to take full advantage of the technique which enables the clinician to incorporate the three-dimensional treatment plan of the final prosthetic result into the imaging examination, evaluate the patient's anatomy relative to the proposed implant sites, esthetics and occlusion, and record and transfer these findings to the patient at the time of surgery. CT enables identification of disease, determination of bone quantity and quality, identification of critical structures at the proposed regions, and determination of the position and orientation of dental implants. CT is capable of determining all five of the radiologic objectives of pre-prosthetic implant imaging.

Interactive Computed Tomography

This technique enables the radiologist to transfer the imaging study to the clinician as a computer file and enables the clinician to view and interact on their own computer. It can be used to measure the length and width of the alveolus, measure bone quality, and change the window and level of the gray scale of the study to enhance the perception of critical structures. Regions of the patient's anatomy can be selected for display normally, with magnification, or with a number of gray scale depictions facilitating the appreciation of anatomical structures or disease. An important feature of ICT is that the clinician and radiologist can perform "electronic surgery" (ES) by selecting and placing arbitrary size cylinders that simulate root form implants in the images. With an appropriately designed diagnostic template, ES can be performed to electronically develop the patient's treatment plan in three-dimensions. Electronic implants can be placed at arbitrary positions and orientations with respect to each other, the alveolus, critical structures, the prospective occlusion and esthetics. ES and ICT enable the development of a three-dimensional treatment plan that is integrated with the patient's anatomy and can be visualized before implant surgery by the members of the implant team and the patient for approval or modification. ICT enables the determination of bone quality adjacent to the prospective implant sites. With the number and size of implants accurately, determined, along with the density of bone at the proposed implant sites, characteristics of the implants can be accurately determined before surgery. Currently ICT is the most accurate imaging technique for implant imaging and surgery but suffers some limitations. ES enables placement of electronic implants in the imaging study but refinement and exact relative orientation of the implant positions is difficult and cumbersome. For instance, three consecutive implants may require parallelism and interproximal spacing of 2.7 mm. The clinician may struggle in achieving the exact relative spacing and orientation with ES and ICT. Parallelism is difficult to appreciate in ICT using orthogonal rather than three-dimensional images. The precision and accuracy of the treatment plan developed using ICT and ES for the implant position, size, orientation, relative spacing, and spatial relationship to the critical structures and proposed esthetics, and occlusion becomes a major challenge at the time of surgery. Transfer of the plan to the patient at the time of surgery can be accomplished by simple visualization and comprehension by a skilled and experienced surgeon, using positions and orientations obtained from ICT and ES to convert the diagnostic template into a surgical template, or the production of a computer generated three-dimensional stereotactic surgical template from the digital ICT an ES data.

Magnetic Resonance Imaging

Magnetic resonance imaging (MRI) is used to image the protons of the body by employing magnetic fields, radio frequencies, electromagnetic detectors, and computers. First described in 1946, its application in implantology is however, of recent origin.[9]

MR imaging is a three-dimensional imaging technique with an electronic image acquisition process and a resulting digital image. Digital MR images are characterized by voxels with an in-plane resolution measured in pixels and millimeter and a section thickness measured in millimeters (2 to 3 mm) for high-resolution imaging and acquisitions. The image sequences employed to obtain MR images can be varied to obtain fat, water, or balanced imaging of the patient's anatomy. Resulting MR images are the antithesis of CT images with cortical bone appearing dark or black and fat or water appearing bright or white. Like CT, MR is a quantitatively accurate technique with exact tomographic sections and no distortion. Failure to differentiate the inferior alveolar canal may be caused by osteoporotic trabecular bone and poorly corticated inferior alveolar canal. MR visualizes the fat in the trabecular bone and differentiates the inferior alveolar canal and neurovascular bundle from the adjacent trabecular bone. Double scout MR imaging protocols produce orthogonal quantitative contiguous images of the proposed implant sites. Oriented MR imaging of the posterior mandible is dimensionally quantitative and enables spatial differentiation between critical structures and the proposed implant site. MR is not useful in characterizing bone mineralization.

CONCLUSION

Today's clinician has a wide array of diagnostic tools at his disposal. The clinician has to carefully weight the pros and cons of each modality and choose particular technique accordingly.

REFERENCES

1. Frederiksen NL. Diagnostic imaging in dental implantology. Oral Surgery Oral Medicine Oral Pathology 1995;80:540-54.
2. Potter BJ, Shrout MK. Implant site assessment using cross-sectional tomographic image. Oral Surgery Oral Medicine Oral Pathology 1997;84:436-41.
3. Kassebaum DK, McDowell JD. Tomography. DCNA 1993;37: 567-74.
4. Reiskin AB. Implant imaging. DCNA 1998;42:47-56.
5. Brooks SL. Computed tomography. DCNA 1993;37:575-90.
6. Webber RL, Horton RA. Comparison of film, direct digital and TACT images to identify the location of crestal defects around endosseous titanium implants. Oral Surgery Oral Medicine Oral Pathology 1996;81:480-90.
7. Sennerby L, Wennerberg A. A new microtomographic technique for non-invasive evaluation of the bone structure around Implants. Clin Oral Implants Res 2001;12:91.
8. Naitoh M, Katsumata A. Measurement accuracy of reconstructed 2-D images obtained by multi-slice helical computed tomography: Clin Oral Implants Res 2004;15:570.
9. Mallya SM, Potluri A. Diagnostic imaging for implants. JIAOMR 2004;16:174-80.