

Angioleiomyoma of the Hypopharynx: A Rare Entity

Raghavendra Suresh, AM Balasubramanya, Vidya Bhushan Rangappa

ABSTRACT

Leiomyomas are benign soft tissue neoplasms that arise from smooth muscle. Cases have been reported in the gastrointestinal tract, brain, oral cavity and other sites. Laryngeal angioleiomyomas are infrequently reported. Literature search revealed no case reported in the hypopharynx. We report a case of 40-year-old female with angioleiomyoma of the hypopharynx. External approaches have been described in the literature for laryngeal leiomyomas. We discuss the endolaryngeal approach for removal of these tumors.

Keywords: Angioleiomyoma, Hypopharynx, Leiomyoma.

How to cite this article: Suresh R, Balasubramanya AM, Rangappa VB. Angioleiomyoma of the Hypopharynx: A Rare Entity. *Int J Phonosurg Laryngol* 2013;3(1):28-30.

Source of support: Nil

Conflict of interest: None declared

INTRODUCTION

Vascular leiomyoma is an uncommon type of smooth muscle tumor. It is rarely seen in the head and neck region, including the involvement of the larynx.¹ Angioleiomyomas occur more frequently in women, although tumors located in the upper extremity and the head and neck appear more frequent in men than in women. The lesions usually develop between the 4th and 6th decades of life.²

Symptoms may vary according to the site of origin of the lesion. Angioleiomyoma of the hypopharynx has not been reported in the world literature so far. We report a rare case of angioleiomyoma in a unique location emphasizing the diagnostic and treatment options.

CASE REPORT

A 40-year-old lady presented to the outpatient Department of ENT, Head and Neck Surgery with foreign body sensation in the throat since 2 years. She also complained of discomfort and mild pain during swallowing mainly on the right side. There was no history of dysphonia, dyspnea, chronic cough and hemoptysis. She was nonsmoker, nonalcoholic. On examination, there was bluish ovoid-shaped, smooth surfaced mass measuring about 2 × 1 cm involving medial wall of right pyriform fossa. Dilated vessels were seen over the surface of the mass (Fig. 1). Rest of visualized larynx was normal, with normal vocal fold mobility. Contrast enhanced computed tomographic (CT) scan of the neck revealed well defined nonenhancing hypodense mass in the medial wall of right side of

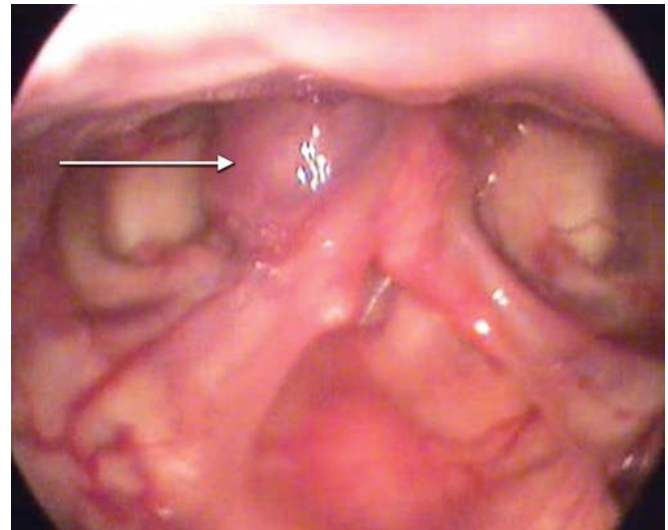


Fig. 1: Arrow mark pointing at the lesion

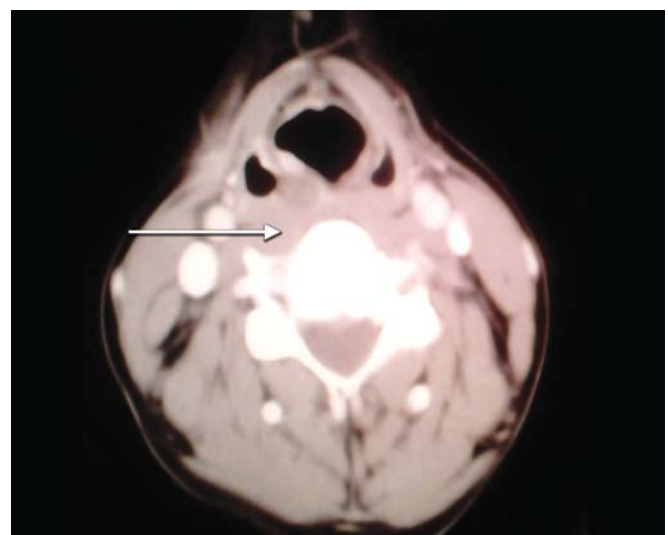


Fig. 2: Arrow mark pointing at the lesion

hypopharynx (Fig. 2). With a provisional diagnosis of mucus retention cyst, she was planned for microlaryngeal surgery under general anesthesia. Intraoperatively 2 × 2 cm mass was found to be arising from medial wall of right pyriform fossa. Linear incision was given over the superior surface of the lesion. Submucosal dissection and enbloc resection of the mass was done. Mucosal flaps were repositioned. Postoperatively patient was started on liquid feeds and subsequently normal diet. Histopathological examination showed a well-circumscribed neoplasm composed of medium-sized thin-walled blood vessels surrounded by a prominent cuff of mature smooth muscle cells. This proliferation of smooth muscle cells was seen to compress

a few blood vessels into slit like spaces. Intervening focal edema was also noted. Findings were consistent with angioleiomyoma. In the follow-up period after 2 weeks, patient was symptom free. Laryngeal examination showed healed mucosa in the operative site.

DISCUSSION

Tumors of smooth muscle origin are rare in the upper aerodigestive tract, due to the paucity of smooth muscle in the area. A review of the literature confirm that this kind of neoplasm is extremely rare in the larynx and not many cases were described in the literature so far.³

Angioleiomyoma is a benign tumor arising from smooth muscle within blood vessel walls. They may express smooth muscle vimentin, desmin, and actin.⁴ This tumor is usually a slow growing painless submucosal mass which can have several clinical diagnosis and just can be diagnosed histologically.⁵

The etiology of vascular tumor is uncertain, but it may be related to trauma, infection, hormones and arteriovenous malformations. More recent research has identified some chromosome abnormalities using genome mapping or DNA screening techniques in patients with angioleiomyomas. Nevertheless, as in most neoplasms, the angioleiomyoma formation mechanism remains obscure.⁶ Three theories have been put forward for the origin of angioleiomyomas: from aberrant undifferentiated mesenchyme, from aberrant undifferentiated mesenchyme, from smooth muscle in the wall of blood vessels, or from both.⁷

Histological classification of leiomyomas by the World Health Organization includes: Leiomyoma, Angioleiomyoma (vascular leiomyoma or angiomyoma) and epithelioid leiomyoma (bizarre leiomyoma and leiomyoblastoma).⁸

The incidence of the lesion was male predominant in head and neck region. Their ages ranged from 11 to 78 years, with a mean of 53.2, and nearly half of the patients were between 40 and 60 years old.¹ In contrast ours was a female patient aged 40 years. The most frequent site of the appearance of angiomyoma is the skin of lower extremities.⁵ Common head and neck sites include the submandibular area, lower lip, oral cavity, nasal cavity, auricle and the skin of the occipital area. Laryngeal tumors are rare; when they do occur, they may be located in either the supraglottic or subglottic space.⁹ In our patient, the lesion was in the pyriform fossa. The common symptoms are hoarseness, dyspnea, dysphagia and sensation of a foreign body in the throat.⁴

CT imaging of the neck demonstrates a homogenous soft tissue mass. Enhanced imaging of the lesions was not

uniform.¹ The lesions typically appeared homogeneous and isointense to skeletal muscle on T1W SE (T1-weighted spin echo) images. T2W FSE (T2-weighted fast spin echo) FS (fat-suppressed) and STIR (short tau inversion recovery) images showed a characteristic appearance of a lesion that was predominantly isointense to surrounding fat but had extensive areas of internal linear and branching hyperintensity. The features on T1W SE images are nonspecific.⁹ The varied proportions of the different components may result in different signal intensity (SI) characteristics on magnetic resonance imaging (MRI).⁹

Histopathologically, the tumor cells are composed of numerous variform blood vessels, lacking mitosis and well-differentiated smooth muscle bundles. Whorls of smooth muscle fibers are observed surrounding the blood vessel endothelium, sometimes with mucoid change. Malignant transformation of vascular leiomyoma is highly unlikely.¹ Preoperative histologic findings on biopsy may be confusing because of the tumor's submucosal location; evaluation may also be complicated by bleeding.²

The treatment of laryngeal vascular leiomyoma has not been standardized due to their rarity. Therapeutic decisions have thus far frequently been made empirically from case to case. The most recommended treatment for laryngeal vascular leiomyomas is complete surgical excision via endoscopic or external approach.¹ These lesions can be excised completely by endolaryngeal approach thereby avoiding complications associated with external approach. It suggests that complete resection of these lesions is important and that the patients should be monitored for recurrence on a regular basis after surgery.¹⁰

CONCLUSION

Laryngeal leiomyoma is a very infrequent neoplasm. Vague symptomatology in throat mandates adequate evaluation of the upper aerodigestive tract. Surgical extirpation is the best choice for treatment of vascular leiomyoma. Patients should be monitored for recurrence regularly after surgery.

REFERENCES

1. Xu Y, Zhou S, Wang S. Vascular leiomyoma of the larynx: A rare entity. Three case reports and literature review. *ORL J Otorhinolaryngol Relat Spec* 2008;70:264-67.
2. Hashimoto H, Quade B. Angioleiomyoma; Chapter 4. In: Christopher DM (Ed). *Pathology and genetics of tumors of soft tissue and bone*. France: IARC 2006:128-29.
3. Burzej-Uchto M, Nowak-Makiela Z, Lapińska-Skowron K, Kosowski B. A rare case of laryngeal leiomyoma. *Otolaryngol Pol* 2006;60(2):207-09.
4. Jun F, Li L, Ning L, Yan L, Siquan T, Shixi L. Giant laryngeal angioleiomyomas: A case report with review of literature. *Am J Otolaryngol* 2009;30:219-20.

5. Motahhary P, Ghazi M, Jabbarian R. Angiomyoma of the hard palate. *Iran J Pathol* 2012;7(1):48-52.
6. Kai-Feng Hung, An-Han Yan, Shou-Yen Kao, Che-Shoa Chang. Angioleiomyoma in right lingual gingiva: A case report. *Chin J Oral Maxillofac Surg* 2005;16:179-87.
7. Meher R, Varshney S. Leiomyoma of the nose. *Singapore Med J* 2007;48:275-76.
8. Manuele C, Yuri E, Filomena O, Antonino I, Carla R, et al. Naso-ethmoidal angioleiomyoma: A mini-invasive combined endoscopic and microscopic surgical approach. *Otolaryngol* 2012;2:110.
9. Gupte C, Butt SH, Tirabosco R, Saifuddin A. Angioleiomyoma: Magnetic resonance imaging features in ten cases. *Skeletal Radiol* 2008;37:1003-09.
10. Keiko S, Toshio Y, Kuniko O, Akio S. A case of angioleiomyoma of the larynx. *Larynx Japan* 2002;14(2):137-42.

ABOUT THE AUTHORS

Raghavendra Suresh (Corresponding Author)

Senior Resident, Department of ENT, St Johns Medical College Bengaluru, Karnataka, India, e-mail: ragsur99@gmail.com

AM Balasubramanya

Professor and Head, Department of ENT, Head and Neck Surgery St Johns Medical College and Hospital, Bengaluru, Karnataka, India

Vidya Bhushan Rangappa

Postgraduate Student, Department of ENT, Head and Neck Surgery St Johns Medical College and Hospital, Bengaluru, Karnataka, India