

Surgical Management of Recurrent Laryngeal Glomus

John Samuel, Sanjeev Mohanty, Gopinath Maraignanam

ABSTRACT

A 51-year-old male presented to the ENT outpatient department with complaints of pain, irritation and foreign body sensation in the throat for 3 months. There was history of being diagnosed to have laryngeal paraganglioma for which the patient had undergone microlaryngeal surgical excision twice during the preceding 9 years. Clinical examination revealed a reddish proliferative mass of about 2 cm involving the laryngeal surface of the epiglottis and extending to the right aryepiglottic fold. Vocal cords were normal in structure and function.

With the previous history of endolaryngeal excision of the tumor and its recurrence, the patient underwent laryngofissure approach with median thyrotomy and left lateral pharyngotomy. The tumor was excised *in toto* and histopathologically confirmed as paraganglioma. Postoperative period was uneventful. Patient is on continued follow-up with no recurrence till date.

Keywords: Laryngeal glomus, Median thyrotomy, Lateral pharyngotomy.

How to cite this article: Samuel J, Mohanty S, Maraignanam G. Surgical Management of Recurrent Laryngeal Glomus. Int J Phonosurg Laryngol 2013;3(1):12-14.

Source of support: Nil

Conflict of interest: None declared

INTRODUCTION

Paragangliomas are benign tumors of neural crest origin located in different parts of the body. The superior and inferior laryngeal paraganglia were first described by Watzka¹ and Kleinsasser² respectively. Subsequently several cases of laryngeal paraganglioma have been reported. These tumors often elicit nonspecific symptoms and hence the diagnosis is often delayed. Recurrences are not infrequent after surgery as complete excision is often precluded by bleeding and difficulty of surgical approach. We report a relatively uncommon case of recurrent supraglottic laryngeal paraganglioma in an adult male which was managed surgically.

CASE REPORT

A 51-year-old male presented to the ENT outpatient department of a tertiary care referral hospital with complaints of pain, irritation and foreign body sensation in the throat of 3 months duration. There was an earlier history of being diagnosed to have laryngeal paraganglioma for which the patient had undergone microlaryngeal surgical excision twice during the preceding 9 years. Clinical examination revealed a reddish lobulated mass of about 2 cm involving the laryngeal surface of the epiglottis and

extending to the right aryepiglottic fold. The vocal cords were normal in structure and function. Neck examination was unremarkable. Patient had no other comorbid illness. The laryngeal findings were confirmed on video laryngoscopy (Fig. 1).

With the previous history of endolaryngeal excision of the tumor and its recurrence, the patient underwent endoscopic-assisted left lateral pharyngotomy in combination with a laryngofissure approach for accessing the tumor. Under general anesthesia, through a horizontal skin crease incision, the thyroid ala was skeletonized and median thyrotomy was done. After retracting the left thyroid ala, a lateral pharyngotomy was done to provide access to the lesion on the right side (Fig. 2). The complete visualization and removal of the tumor was aided by the use of a 0° nasal endoscope introduced through the pharyngotomy. The tumor was excised *in toto* (Fig. 3). The lateral pharyngotomy was closed in layers and the patient was on nasogastric feeds postoperatively to promote healing of the pharyngotomy and a tracheostomy was avoided. Histopathological examination showed the typical 'zellballen' arrangement of chief cells and sustentacular cells. Immunohistochemistry was confirmative of paraganglioma. Postoperative period was uneventful. Patient is on continued follow-up with no recurrence 1 year postoperatively, as evidenced by video laryngoscopy (Fig. 4).

CONCLUSION

Laryngeal paragangliomas are uncommonly reported lesions especially among males. Endoscopic excisions have resulted

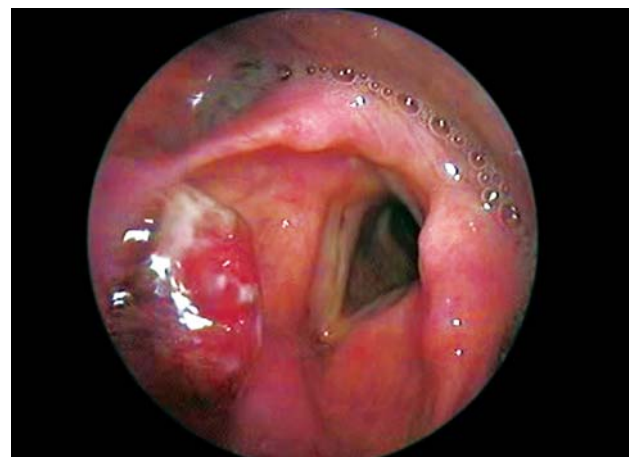

Fig. 1: Preoperative video laryngoscopy showing a red, lobulated mass in the right aryepiglottic fold

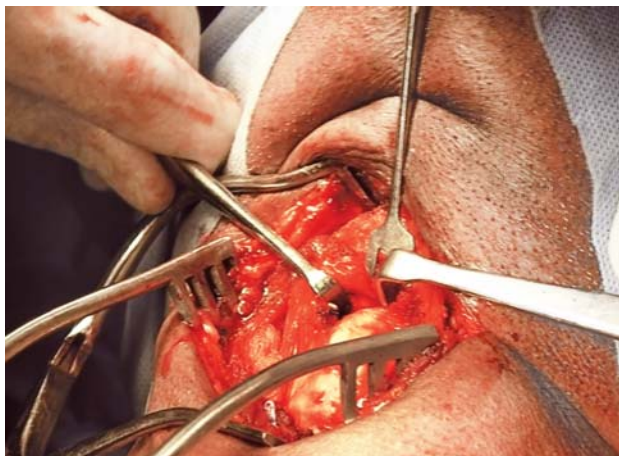


Fig. 2: Left lateral pharyngotomy and median thyrotomy approach

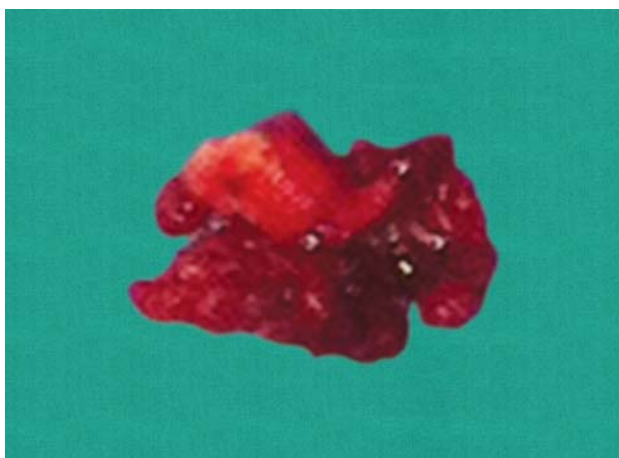


Fig. 3: The excised tumor mass

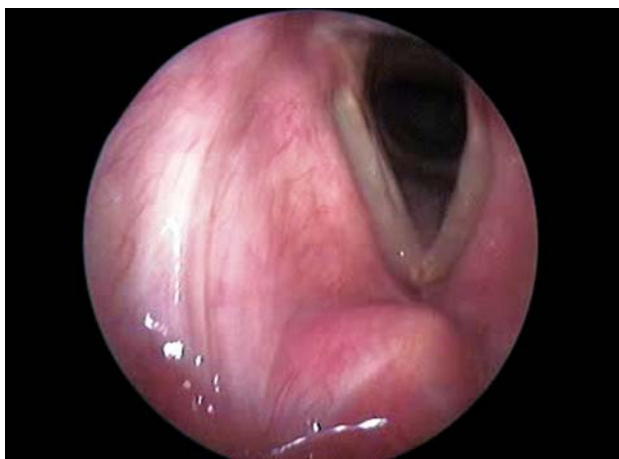

Fig. 4: Video laryngoscopy at 1 year showing well-healed scar with no recurrence

in recurrences on follow-up.³ Open surgical procedures like thyrotomy and pharyngotomy ensure complete removal and minimize recurrences. This case is being reported for its rarity of occurrence that too in a male patient, with repeated

endolaryngeal excision proving unsuccessful, necessitating an open surgical approach.

DISCUSSION

Nearly 82% of laryngeal paragangliomas arise from supraglottic larynx⁴ with a female to male preponderance of 3:1.⁵ Laryngeal paragangliomas are common during the fourth to sixth decades of life.⁵ Right-sided tumors are more common than left-sided tumors by a ratio of 2.3:1.⁴ Supraglottic paraganglia are located in the false vocal cord and the tumor causes a foreign body sensation in the throat. The supraglottic paragangliomas are supplied by the superior laryngeal artery. The incidence of malignant transformation is less than 2%.⁵

Laryngeal paragangliomas can be diagnosed by gadolinium enhanced magnetic resonance imaging (MRI)⁶ complemented by ¹¹¹Indium pentetreotide scintigraphy.⁷ This obviates the need for superselective angiography in diagnosis.⁸ The zellballen pattern of cell arrangement is not pathognomonic of paraganglioma. Immunohistochemistry is confirmative. The cells are argyrophil positive and argentaffin negative and express all neuroendocrine markers.⁹ The differential diagnoses are typical carcinoid, atypical carcinoid, small cell neuroendocrine carcinoma and malignant melanoma. Immunohistochemistry aids in differentiation between these conditions.

Treatment includes endoscopic removal of these lesions. However, recurrences are common with endoscopic removal (17%) as reported in this case. Open surgical approaches help in complete tumor removal. Supraglottic laryngectomy has been reported to ensure successful removal of the tumor. Laryngofissure approach with lateral pharyngotomy provides good access to tumor removal preserving swallowing and avoiding tracheostomy.¹⁰

REFERENCES

1. Watzka M. Uber die Paraganglien in der Plica ventricularis des menschlichen Kehlkopfes. *Dtsch Med Forsch* 1963;1:13-20.
2. Kleinsasser O. Das Glomus laryngicum inferior. *Arch Klin Exp Ohren Nasen Kehlkopfgeilkd* 1968;192:100-05.
3. Konowitz PM, Lawson W, Som PM, et al. Laryngeal paraganglioma: Update on diagnosis and treatment. *Laryngoscope* 1988;98:40-49.
4. Barnes L. Paraganglioma of the larynx: A critical review of the literature. *ORL J Otorhinolaryngol Relat Spec* 1991;53:220-34.
5. Ferlito A, Barnes L, Wenig BM. Identification, classification, treatment and prognosis of laryngeal paraganglioma: Review

- of the literature and eight new cases. *Ann Otol Rhinol Laryngol* 1994;103:525-36.
6. Eustrin ES, Palestro C, Vaheesan K. Radiographic evaluation and assessment of paragangliomas. *Otolaryngol Clin North Am* 2001;34:881-906.
 7. Myssiorek D, Palestro CJ. ¹¹¹Indium pentetreotide scan detection of familial paragangliomas. *Laryngoscope* 1988;108:228-31.
 8. Ferlito A, Barnes L, Rinaldo A, et al. A review of neuroendocrine neoplasms of the larynx: Update on diagnosis and treatment. *J Laryngol Otol* 1998;112:827-34.
 9. Myssiorek D, Rinaldo A, Barnes L, et al. Laryngeal paraganglioma: An updated critical review. *Acta Otolaryngol* 2004;124:995-99.
 10. Rubin JS, Silver CE. Surgical approach to submucosal lesions of the supraglottic larynx. *J Laryngol Otol* 1992;106:416-19.

ABOUT THE AUTHORS

John Samuel (Corresponding Author)

Associate Professor, Department of ENT, Head and Neck Surgery
Sri Ramachandra University, Chennai, Tamil Nadu, India
e-mail: johnsam71@yahoo.co.in

Sanjeev Mohanty

Professor, Department of ENT, Head and Neck Surgery, Sri
Ramachandra University, Chennai, Tamil Nadu, India

Gopinath Maraignanam

Associate Professor, Department of ENT, Head and Neck Surgery
Sri Ramachandra University, Chennai, Tamil Nadu, India