

# Cerebrospinal Fluid Rhinorrhea: The Place for Endoscopic Surgery

Arvind Soni

Senior Consultant, Indraprastha Apollo Hospitals, New Delhi, India

**Correspondence:** Arvind Soni, Senior Consultant, Indraprastha Apollo Hospitals, New Delhi, India

## Abstract

Transnasal endoscopic repair of CSF rhinorrhea is an effective and safe procedure. A retrospective follow-up of nineteen patients who underwent transnasal endoscopic repair was done. A variety of graft materials and grafting techniques were used. None of the patients had any complications or required revision surgery.

**Keywords:** CSF rhinorrhea, fascia lata, underlay.

## INTRODUCTION

Cerebrospinal fluid (CSF) rhinorrhea has been managed by both neurosurgeons and otorhinolaryngologists, with neurosurgeons often choosing an intracranial approach and otorhinolaryngologists an extracranial approach. Recently, transnasal endoscopic techniques have been introduced that significantly reduce the morbidity of surgical repair when compared with previous techniques.<sup>1</sup> The sense of smell was preserved in all patients who underwent an endoscopic repair of their CSF leak where it was present preoperatively. The results of transnasal endoscopic repair now make it the treatment of choice for most anterior cranial and sphenoid CSF leaks, with the exception of defects in posterior wall of the frontal sinus. It is vital that a diagnosis of a CSF leak is confirmed by preoperative examination including computed tomographic scans; nasal endoscopy; measurement of glucose concentration in the nasal discharge; and, in some cases, cisternographic evaluation via computed tomography and/or magnetic resonance imaging. Telescopes, conventional endoscopic sinus surgery instruments, and a microdebrider were used for all patients who underwent endonasal surgery. A combination of abdominal fat, fascia lata, cartilage and fibrin glue, were used for fistula repair. This article illustrates our experience with nineteen patients who were referred with a diagnosis of CSF rhinorrhea by neurosurgeons of our institution.

## OBJECTIVE

To summarize our experience in managing cerebrospinal fluid (CSF) rhinorrhea.

## OBJECTIVES/HYPOTHESIS

Many reports<sup>2-4</sup> have advocated the feasibility of using an endoscope for the treatment of cerebrospinal fluid (CSF) rhinorrhea and skull base defect, and diversified endoscopic techniques and repair materials have recently been proposed. This study determined the effectiveness of endoscopic repair of CSF leaks and interpreted the indications of the lumbar drain.

## STUDY DESIGN

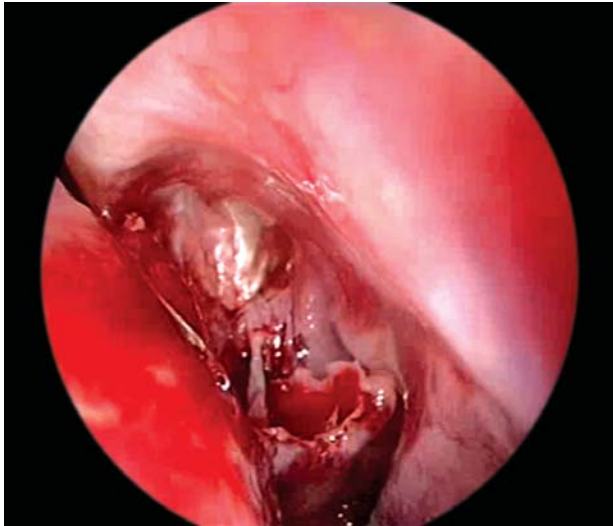
Retrospective follow-up.

## METHODS

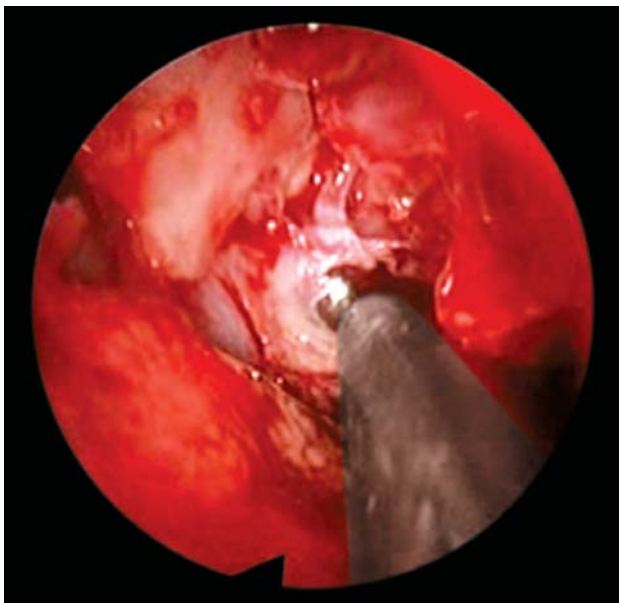
A total of 19 patients with CSF rhinorrhea (Table 1) were treated in our institution over a 2-year period. An underlay procedure was used to perform 16 (84.21%) repairs using fascia lata free graft (Fig. 1), two (10.5%) repairs by way of septal cartilage free graft (Fig. 2), one (5.26%) by abdominal fat (Table 2). In 16 patients, underlay technique was used while 2 repairs were performed using overlay technique and in one fat was used as dumb-bell to fill the defect (Table 3). Fibrin glue was used in all overlay grafts and 14 of underlay grafts.

**Table 1:** The patient distribution according to etiology

<i>Etiology</i>	<i>Number of patients</i>
Traumatic	2
Iatrogenic	3
Spontaneous	14



**Figure 1:** Underlay fascia lata used to repair defect in ethmoid roof



**Figure 2:** Cartilage underlay to repair the defect in fovea ethmoidalis

**Table 2:** The various graft materials used for repair

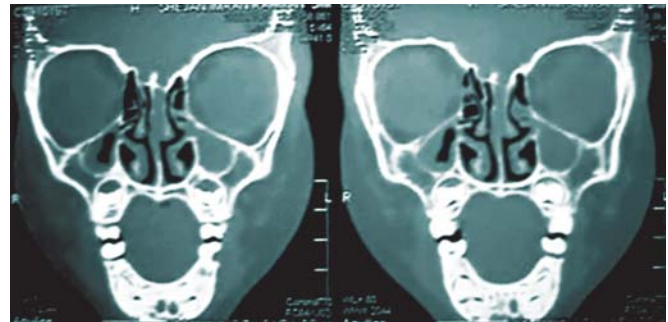
Graft position	Number of patients
Underlay	16
Overlay	2
Dumb-bell fat	1

**RESULTS**

Defects in the cribriform plate and anterior ethmoid sinus comprised the majority 12 (63.15%) of all lesions. The successful rates for overlay, underlay, and fat obliteration

**Table 3:** The various techniques used for repair

Graft material	Number of patients
Fascia lata	16
Cartilage	2
Fat	1



**Figure 3:** CT scan of meningocele

procedures were 100% (2/2), 100% (16/16), and 100% (1/1), respectively. There was no statistical difference between underlay and overlay techniques. Lumbar drainage was performed in 15 of 19 (78.94%) cases. Most patients required nasal packing (89.7%) and prophylactic parenteral antibiotics (97.4%). CSF rhinorrhea resolved during the first attempt in all of 19 (100%) patients. There was no need for a second attempt. No major complications were encountered.

**CONCLUSION**

The endoscopic approach is safe and effective for the treatment of CSF rhinorrhea, even in the cases not successfully treated by previous neurosurgical approaches. Lumbar drain was suggested for defects in the frontal and sphenoid sinus and defects associated with meningocele (Fig. 3) or encephalocele. Complete exposure of the defect, appropriate selection of a fitting graft, as well as accurate placement and stabilization of the graft are critical to the success of repair.

**REFERENCES**

1. Marshall AH, Jones NS, Robertson IJ. CSF rhinorrhoea: The place of endoscopic sinus surgery. *Br J Neurosurg* 2001;15(1): 8-12.
2. Bibas AG, Skia B, Hickey SA. Transnasal endoscopic repair of cerebrospinal fluid rhinorrhoea. *Br J Neurosurg* 2000;14(1):49-52.
3. Gupta AK, Gupta AK, Verma M. Cranionasal fistula in pediatric population: Is endonasal endoscopic approach effective? *Int J Pediatr Otorhinolaryngol* 2007;71(10):1537-41. Epub 2007.
4. Gendeh BS, Mazita A, Selladurai BM, Jegan T, Jeevanan J, Misiran K. *J Laryngol Otol*. Endonasal endoscopic repair of anterior skull-base fistulas: The Kuala Lumpur experience 2005;119(11):866-74.