

# Hemostatic Effect of the CO<sub>2</sub> Laser Over Excision of an Intraoral Hemangioma

Girish Rao, PS Tripathi, Kritika Srinivasan

## ABSTRACT

Hemangiomas are benign vascular tumors of the endothelial cells and characterized by increased number of normal or abnormal vessels filled with blood. Most true hemangiomas involute with time, but a certain small percentage does not, which may present with complications that require treatment. An estimated 10 to 20% of the true hemangiomas incompletely involute and require ablative treatment. Hemangiomas are probably one of the most underestimated and misunderstood vascular tumors and it is every diagnostician and clinician's imperative to have a sound knowledge of these tumors to thus provide successful treatment to the patients.

Conventional surgical excision of hemangioma can cause severe bleeding in the operative site, which on the other hand can be well controlled by the coagulative effect of the CO<sub>2</sub> laser, by virtue of a painless vaporization of the tissue. The purpose of this case study is to understand hemangiomas and the importance and efficacy of the minimally invasive, hemostatic effect of a CO<sub>2</sub> and little postoperative scarring and morbidity in comparison to the conventional surgical techniques.

**Keywords:** Intraoral hemangioma, Laser excision, CO<sub>2</sub> laser, Hemostasis.

**How to cite this article:** Rao G, Tripathi PS, Srinivasan K. Hemostatic Effect of the CO<sub>2</sub> Laser Over Excision of an Intraoral Hemangioma. *Int J Laser Dent* 2012;2(3):74-77.

**Source of support:** Nil

**Conflict of interest:** None declared

## INTRODUCTION

In the past, our understanding of vascular anomalies had been hampered by confusing nosology. This confusion had been responsible for improper diagnosis, illogical treatment and misdirected research efforts.<sup>1</sup> Mulliken et al in 1982, categorized these conditions into two families: A family of self-involuting tumors, growing lesions that eventually disappear and enlarged or abnormal vessels present at birth and essentially permanent.

Treatment of vasoformative tumors represents a challenge because the morbidity can range from minor bleeding and swelling to life-threatening hemorrhage and airway embarrassment.

Conservative surgical management consists of periodic visits, parental support and photo documentation. It is the most common and longest established method of treatment followed.

It provides the advantage of ease of surgeon's skill and training, ease in handling of instruments and is cost-

effective. However, excessive bleeding, considerable wound contraction leading to restriction of oral functions and constant need for cleaning and sterilization lowers the efficacy of this procedure.<sup>2</sup>

Electrosurgery and cryosurgery are two other modalities which have high restrictions as a result of unpredictability, normal tissue damage, delay in healing as a result of presence of tissue debris and so.<sup>2</sup>

After the development of the first laser, a ruby laser, by Theodore H Maiman (Nature; 1960), based on the concept of spontaneous and stimulated emission of radiation, medical and dental researchers soon began to study different types of lasers for extra- and intraoral surgical procedures. The earliest reports of use of laser were in 1977 by Lenz et al and in radiation therapy by Goldman in 1965.

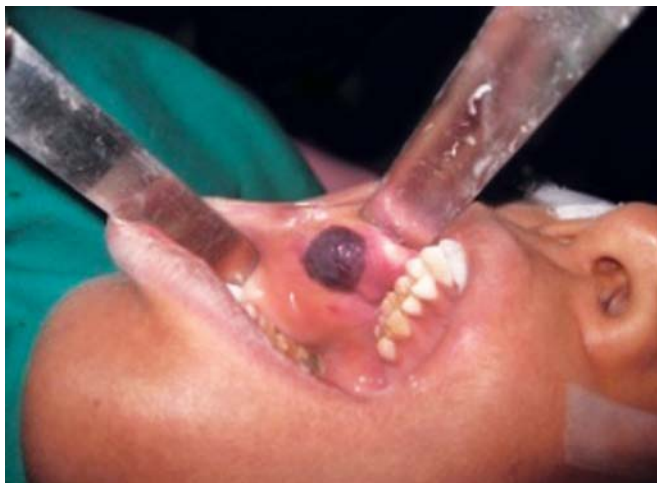Due to its affinity for water-based tissues, the carbon dioxide (CO<sub>2</sub>) laser has become a favorite instrument of oral surgeons for treatment of pathologic conditions of the oral mucosa (Sulewski 2000, Bornstein et al 2003a). Excising treatments can be performed faster with better comfort and clinical results as an outpatient procedure. The surgical interventions are sterile, hemostatic and without the requirement of any suturing depending on the size of the lesion.<sup>3</sup>

## MATERIALS AND METHODS

A 32-year-old female patient reported to the dental unit with the swelling and growth on the inner side of the right cheek, between the middle and back teeth. She complained of a localized, recurrent blood-filled swelling since 3 years, which grew larger on each recurrence and would bleed spontaneously and cause discomfort on eating and talking.

On general physical examination, it was found that the patient was normally built for her age with no defect in gait or stature, and there was no relevant medical history. Family history was also non-contributory.

A comprehensive intraoral examination revealed a sessile purplish swelling of the right buccal mucosa, in the region between the maxillary right canine and first molar, approximately 3 cm in diameter. It was bluish red in hue and soft on palpation, well defined, with absence of any prominent pulsation (Fig. 1).

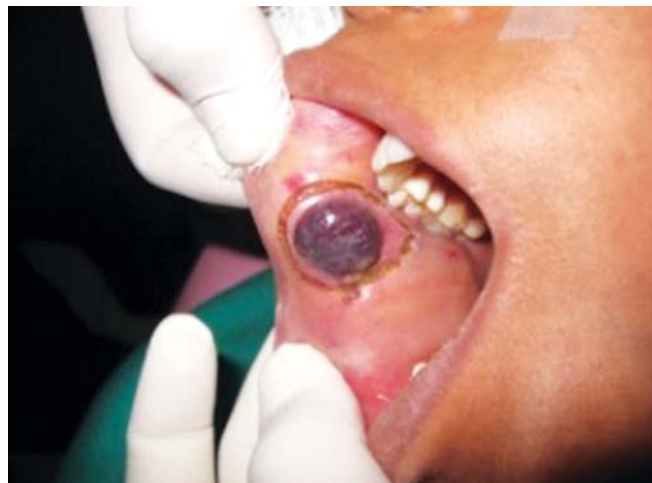

**Fig. 1:** Vascular lesion examined on the buccal mucosa

The laboratory investigations of blood and urine were within normal limits that ruled out any condition varying from diabetes mellitus, HIV, HBs, VDRL and Mantoux test were negative and possibility of any infectious involvement. Due to the irregular nature of the lesion, an ultrasound diagnostic device was utilized, to confirm the diagnosis of a vascular lesion devoid of any substantial feeding artery (Fig. 2).

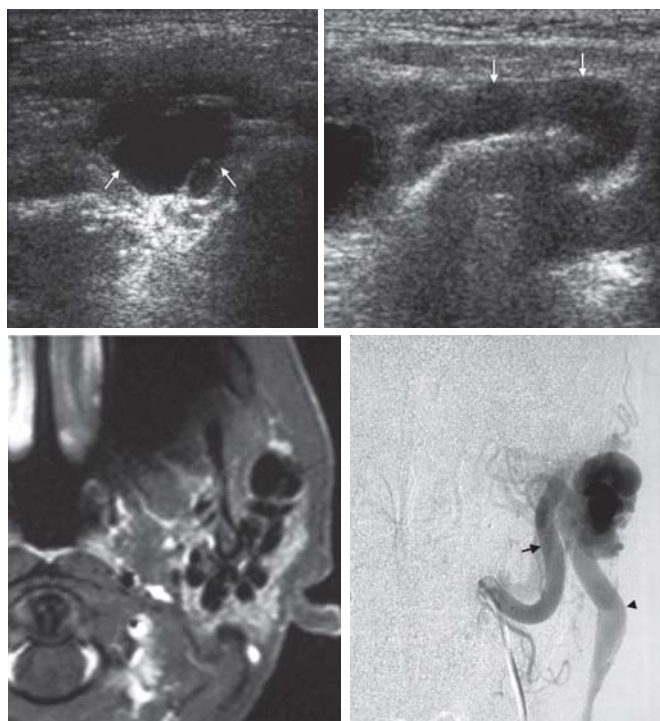
Since the lesion was a cause of spontaneous bleeds and interfered with the normal bite of the patient, an informed consent for the excision of the lesion was taken after thoroughly explaining the procedure.

The lesion's margins were first marked out (Fig. 3) to aid in determining the extent of the lesion for precision in

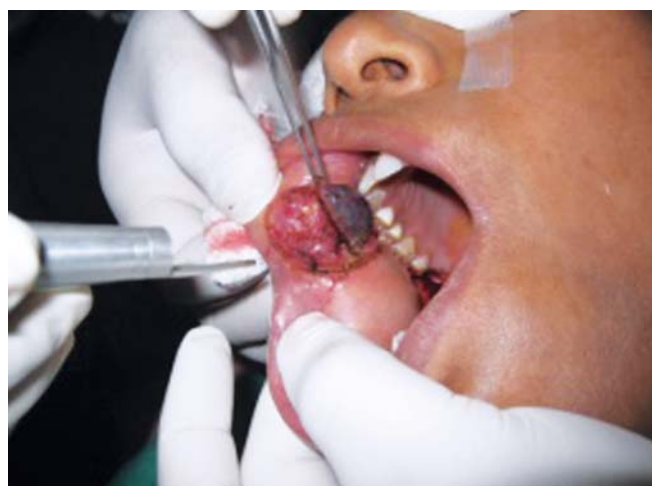

**Fig. 3:** Margins of the lesion marked with the laser

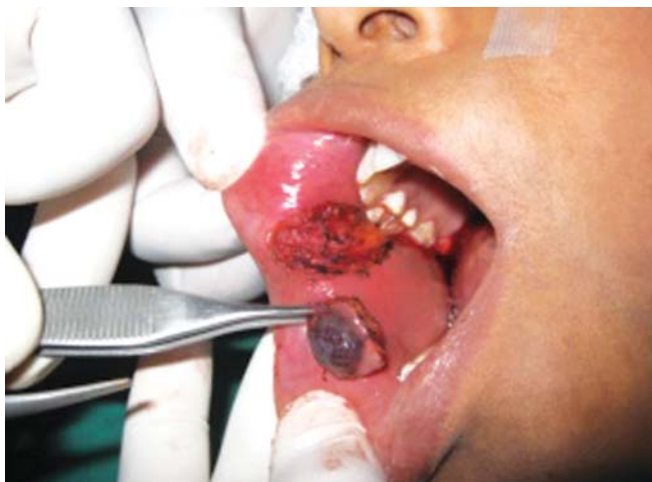laser excision. A spot size CO<sub>2</sub> laser, with a power of 5W (A) in the continuous mode, 140 Hz of frequency, pulse duration of 400  $\mu$ m and pulse energy 33 mJ was used to excise the tumor (Figs 4 to 6) along the margins and sutures were placed (Fig. 7).



**Fig. 2:** An ultrasound helped to confirm the diagnosis



**Fig. 4:** Absolutely bloodless field during excision



**Fig. 5:** Lesion excised *in toto*



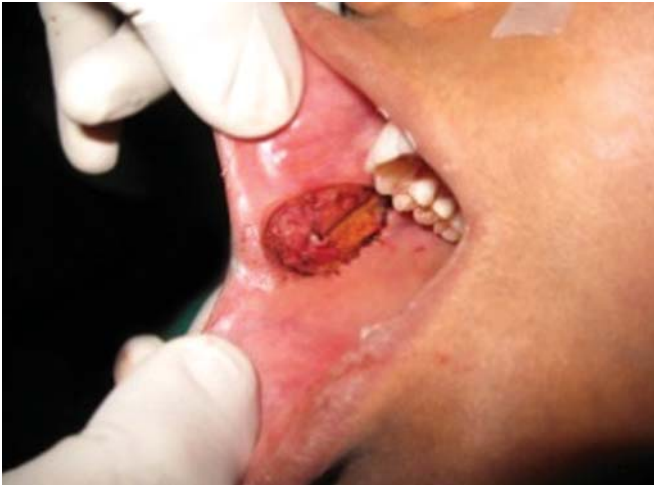

Fig. 6: Absence of any bleeding complications

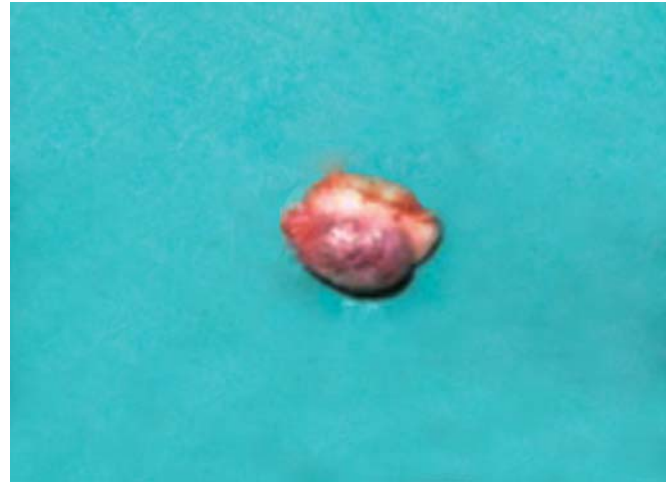


Fig. 8: Clinical presentation of the lesion post-excision for biopsy

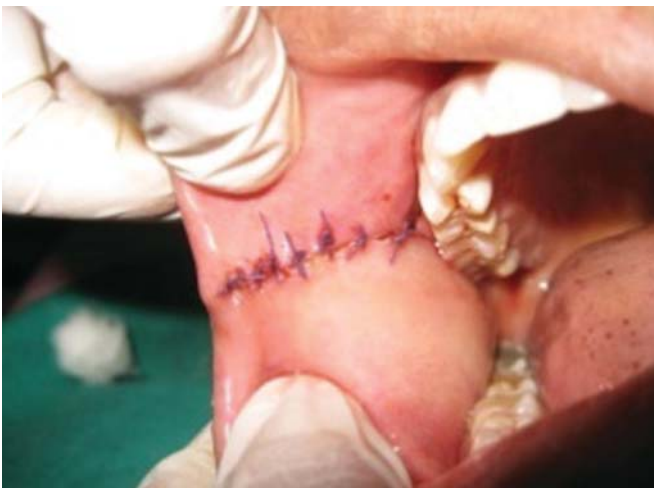

Fig. 7: Sutures placed, post-excision

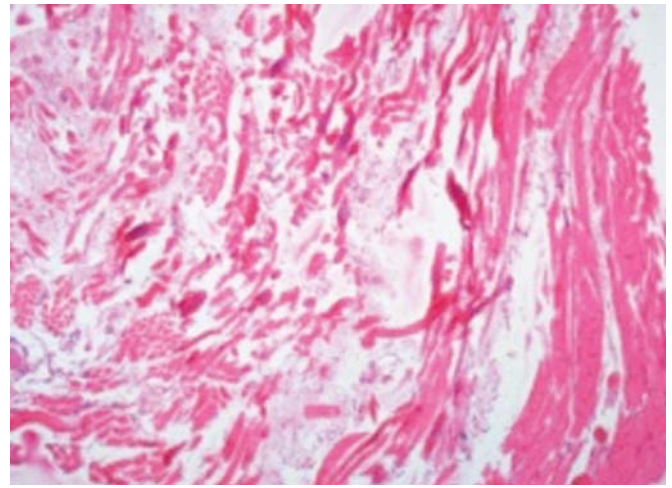


Fig. 9: Histological image of the biopsied lesion

On performing a histopathological study, the excised lesion (Fig. 8) was characterized as a 'traumatic angiomatosis' lesion (Fig. 9). Having achieved an infection-free wound area 3 days postsurgically, the patient was recalled 3 months postoperatively for observation. Minimum scarring was then observed at the healed wound site (Fig. 10).

### DISCUSSION AND CONCLUSION

The use of CO<sub>2</sub> lasers for the surgical management of a hemangioma provides a wide aspect of advantages. In the past, it has been reported in literature for the successful treatment of various conditions, ranging from benign lesions, like hemangioma, lymphangioma, pyogenic granuloma, mucocele, ranula, malignant and premalignant lesions<sup>4</sup> and others early applications in gynecology and otolaryngology.

In the present case report, the advantage of a CO<sub>2</sub> laser usage has been in terms of a virtually bloodless surgical field as a result of the hemostatic mechanism of the laser, providing an excellent visualization of the area and

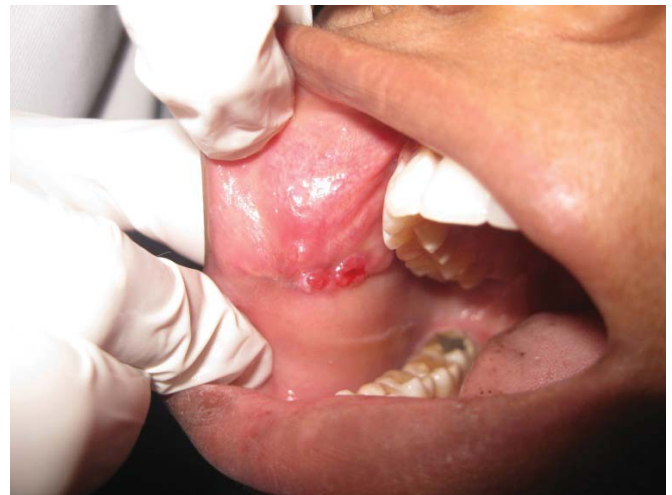

Fig. 10: Wound site 3 months postoperative

facilitates an accurate resection of the lesion with suitable margins. The ability of a CO<sub>2</sub> laser to negotiate curvatures and folds within the tissue contours; tissue surface sterilization and, therefore, reduction in bacteremia; decreased swelling, edema and scarring, due to sealing of

small lymphatic vessels and less inflammatory response; decreased pain also due to effects on the nerve endings; faster healing response and increased patient acceptance.<sup>2,3,5</sup>

Surprisingly, there is little data to support other contentions, such as faster healing response or decreased scarring, although it has been noted that there are smaller number of myofibroblasts in the laser excised wound regions. Also, claims of faster healing of laser soft tissue wounds appear to be wavelength specific and highly sensitive to energy density.<sup>6,7</sup>

The dye lasers although, was the first laser to work on the basis of selective photothermolysis, primarily constructed as an effective means with few side effects for the treatment of superficial pigmentation and vascular changes.<sup>8</sup> They are thus mainly adapted to remove so-called port wine stains and superficial skin changes and thus inferior to the CO<sub>2</sub> lasers, which can successfully treat hemangioma extending into subepidermal tissue regions.<sup>8</sup>

While the major disadvantage of the Nd:YAG laser over CO<sub>2</sub>, each method of operation requires a separate appliance. Furthermore, electromagnetic spectrum of 1,064 nm exhibits rather insignificant absorption affinity to water and hemoglobin so that the laser penetrates the oral mucosa relatively unimpaired.<sup>9</sup> This coagulation effect renders the Nd:YAG laser appropriate for treating low lying hemangioma but with greater risk of side effects and marked scarring as a result of a higher penetration depth.<sup>8,10</sup>

Surgical excision or resection with a laser, especially the CO<sub>2</sub>, has an advantage of not only spontaneous hemostasis but also preventing the mobility of tumor or infection entities along the flow of the blood, to other bodily locations. The use of CO<sub>2</sub> lasers has been ascribed to minimal requirements of medication postoperatively and short hospital stay, very frequently leading to outpatient procedures.<sup>11</sup>

A matter of contention in terms of safety precautions for the operators, during laser surgery, is that the ocular tissues of medical attendants are in danger of absorbing laser light. This could occur if the laser beam were inadvertently reflected from a shiny metal surface in the surgical field. The intensity of the injury would be less from a reflected beam, as the light would be divergent and incoherent, than from a direct beam.<sup>12</sup> Nevertheless, to prevent corneal injury, it is frequently recommended that personnel in the operating theater wears spectacles since the laser energy at a wavelength of 10.6 nm is stopped by glass. During microsurgical procedures, there is no danger to the surgeon since the glass optics of the operating scope absorb any reflected CO<sub>2</sub> laser energy. Explosive or inflammable gases

and liquids, including esthetic gases and solutions used to prepare the surgical site that contain alcohol, cannot be used near the laser beam. Tissues surrounding the impact site can be protected by saline-soaked sponges, since CO<sub>2</sub> laser light is absorbed by water.<sup>3</sup>

## REFERENCES

1. McGill T, Mulliken J. Vascular anomalies of the head and neck. Chapter 20: Otolaryngology Head and Neck Surgery. Baltimore, MD: Mosby-Year Book 1993;333-46.
2. Pinheiro AB, Frame JW. An audit of CO<sub>2</sub> laser surgery in the mouth. *Braz Dent J* 1994;5(1):15-25.
3. Wright VC. Laser surgery: Using the carbon dioxide laser. *Can Med Assoc J* 1982 May 1;126:1035-39.
4. Pinheiro AB, Frame JW. Surgical management of premalignant lesions of the oral cavity with the CO<sub>2</sub> laser. *Braz Dent J* 1996;7(2):103-08.
5. Apfelberg DB, Maser MR, Lash H, White DN. Benefits of the CO<sub>2</sub> laser in oral hemangioma excision. *Plast Reconstr Surg* 1985 Jan;75(1):46-50.
6. Baschongh W, Schiel J, Imholz M, Suetterlin R. Visualization of subcellular changes induced by CO<sub>2</sub> laser surgery in vitro. *Schweiz Monatsschr Zahnmed* 2001;111:545-51.
7. Malik AM, Bajwa R. Initial tissue response after partial glossectomy by 3 Watt, 6 Watt CO<sub>2</sub> laser and scalpel. *ANNALS* 2011 Apr-Jun;17(2):187-95.
8. Suter VGA, Altermatt HJ, Sendi P, Mettraux G, Bornstein MM. CO<sub>2</sub> and diode laser for excisional biopsies of oral mucosal lesions. *Research and Science* 2010;120(8):664-71.
9. Cob CM. Lasers in periodontics: A review of the literature. *J Periodontol* 2006 Apr;77(4):545-64.
10. Crisan BV, Baciut M, Baciut G, Campian RS, Crisan L. Laser treatment in oral and maxillofacial hemangioma and vascular malformations. *TMJ* 2010;60(1):34-38.
11. Lambrecht JT, Stubinger S, Hodel Y. CO<sub>2</sub> laser therapy for intraoral Hemangiomas. *J Oral Laser Applications* 2004;4: 89-96.
12. Colluzi DJ. Fundamentals of lasers in dentistry: Basic science, tissue interaction and instrumentation. *J Laser Dent* 2008;16(Spec. Issue):4-10.

## ABOUT THE AUTHORS

### Girish Rao

Professor and Head, Department of Oral and Maxillofacial Surgery DAPMRV Dental College and Hospital, Bengaluru, Karnataka, India

### PS Tripti

Postgraduate Student, Department of Oral and Maxillofacial Surgery DAPMRV Dental College and Hospital, Bengaluru, Karnataka, India

### Kritika Srinivasan (Corresponding Author)

Research Associate, Department of Oral and Maxillofacial Surgery DAPMRV Dental College and Hospital, Bengaluru, Karnataka, India  
e-mail: kritika.r.srinivasan@gmail.com