

The Efficacy of Treatment for Vocal Fold Bowing with Pulsed Dye Laser

Yong Cheol Koo, Hyo Jin Chung, Michelle J Suh, Hong-Shik Choi

ABSTRACT

Bowing of the vocal folds can result from aging, atrophy or idiopathic causes, such as an injudicious vocal cord surgery. Bowing results in dysphonia due to inadequate approximation of the vocal folds.

A number of treatments have been proposed for this condition. Intracordal injection of biological materials including liquid silicon and Teflon and various types of thyroplasty have been utilized. However, full voice recovery has never been fully achieved.

We present a case involving a 64-year-old Asian man with dysphonia for 30 years. The patient's vocal fold bowing was examined on laryngoscopy. The disease was effectively treated with pulsed dye laser (PDL) followed by speech therapy.

Observation of the patient over 1 year did not show any signs of recurrence. Our analysis revealed voice quality improvement.

Keywords: Vocal cords, Laser therapy, Male, Voice disorders.

How to cite this article: Koo YC, Chung HJ, Suh MJ, Choi HS. The Efficacy of Treatment for Vocal Fold Bowing with Pulsed Dye Laser. *Int J Phonosurg Laryngol* 2012;2(1):46-48.

Source of support: Nil

Conflict of interest: None

INTRODUCTION

Vocal fold bowing, formation of a small gap between vocal folds, results from aging secondary to atrophy of the true vocal fold and causes incomplete closure of vocal folds and subsequent voice change.¹

Vocal fold bowing can occur from intubation injury to the vocal mucosa, vocal fold paralysis, or a senile larynx.²

Treatment methods, such as voice rehabilitation, intracordal injection for narrowing glottic gap, and various thyroplasties have been introduced to resolve such bowing. However, we were not able to identify the most effective method of treatment.³⁻⁵

We report a case and literature review of treatment using pulsed dye laser (PDL), a new therapy using light fibers, and demonstrate good results in a 64-year-old male patient with vocal fold bowing.

CASE REPORT

A 64-year-old man with dysphonia visited the outpatient clinic at our institution.

On physical examination, laryngoscopy and stroboscopy demonstrated normal vocal fold mobility without sulcus but

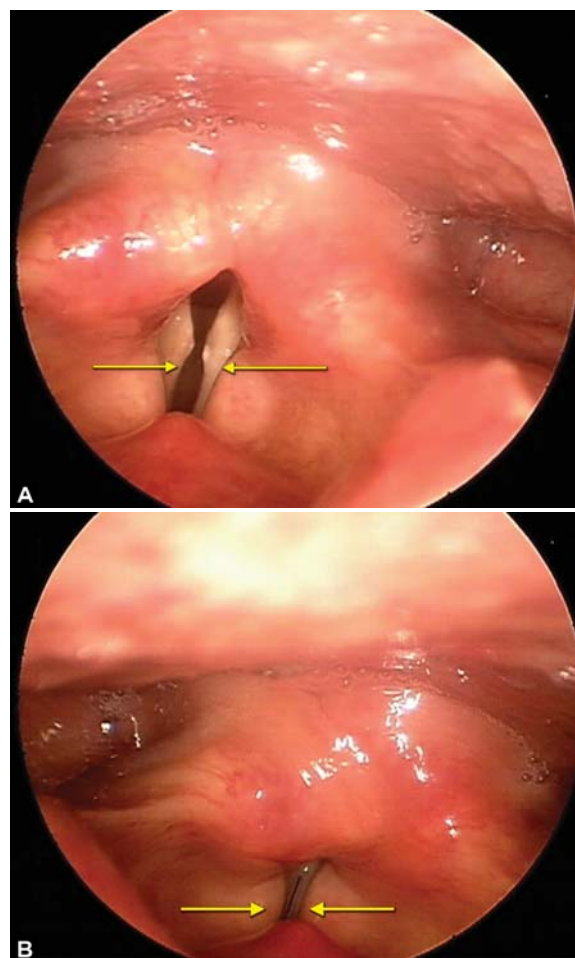
bowed, atrophic vocal folds resulting in a glottal gap during phonation (Figs 1A and B).

After voice therapy, there was no significant improvement, so surgery was planned.

Under general anesthesia, PDL was used for vocal fold surgery. Both sides of the vocal fold lesions were irradiated by 585 nm PDL (right: 66 fractions, left: 43 fractions). The fiber was positioned at a fixed distance of 1 to 3 mm from the bowing mucosa (Fig. 2).

The patient was discharged without complications, such as bleeding or dyspnea.

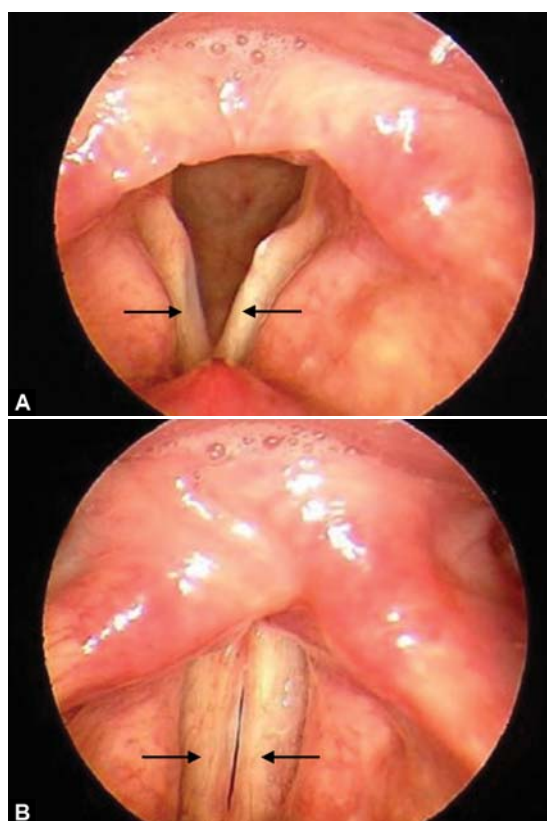
During the 1 year follow-up with voice therapy, patient improvement was observed on physical examination (laryngoscopic finding (Figs 3A and B), voice analysis (Figs 4A and B, Table 1) and also for the subjective aspects.



Figs 1A and B: Preoperative laryngoscopic view revealed bowing of true folds (arrows). (A) Fully abducted position, (B) fully adducted position

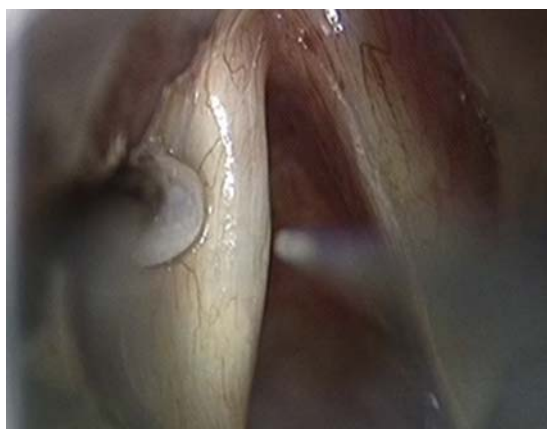

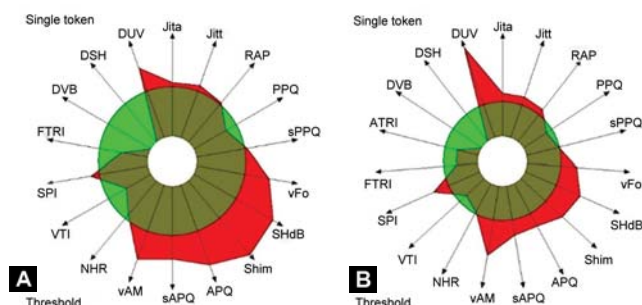
Fig. 2: Use of PDL for treatment of bowing (arrow: PDL fiber of 0.6 mm diameter)



Figs 3A and B: Postoperative videostroboscopic images of bowing vocal folds after surgery. After surgery, the volume of the true fold was increased, and vibration was improved (arrow). (A) Fully abducted position, (B) fully adducted position

DISCUSSION

Bowing of the vocal fold occurs in 20 to 29% of elderly patients with dysphonia.^{6,7}



Figs 4A and B: MDVP graph of CSL shows improvement in voice quality after surgery (A) Preoperative MDVP graph, (B) postoperative MDVP graph

The mechanism of the disease is not yet fully understood. Numerous different treatment tools including voice therapy, intracordal injection of biodegradable substances, thyroplasty and electrical stimulation on laryngeal muscles are used for vocal fold bowing.¹ However, there is no specific treatment to completely cure the bowed lesion.

Among several treatments modalities, such as type I thyroplasty and intracordal injection,⁸ previous authors have attempted to treat vocal fold bowing with PDL laser.⁹

The energy of 585 nm PDL based on angiolytic laser treatment is selectively absorbed by oxyhemoglobin to selectively destroy specific target tissues without damage to surrounding structures.^{9,10}

PDL has been used to treat a variety of vascular skin malformations in the dermatologic field. This technology has shown good results in several diseases, including laryngeal papilloma, facial verrucae and epistaxis with vascular ectasias.^{9,11}

The use of pulse dye laser in the treatment of vocal fold scarring resulted in improvements in velopharyngeal insufficiency, acoustic measures of Shimmer and Jitter and stroboscopy findings.¹²

Bouzari et al¹³ showed that PDL was effective for the treatment of hypertrophic scarring, generating heat and leading to coagulation necrosis, neocollagenesis and subsequent collagen fiber realignment. According to articles by Karsai et al¹⁴ damaged epidermal collagen fibers and the superficial layer of dermis were recovered through PDL therapy by increasing the production of type III procollagen, decreasing damaged collagen fiber and increasing fibroblast activity.

Table 1: Comparison of preoperative and postoperative voice analysis of the patient with bowing vocal folds treated with PDL

Parameter	Preoperative	Postoperative	Normal range (± STD)
Jitter percent (Jitt, %)	1.168	1.296	0.589 (± 0.535)
Shimmer percent (Shim, %)	7.392	6.291	2.523 (± 0.997)
Average fundamental frequency (F0, Hz)	130.036	124.436	145.223 (± 23.406)
F0-tremor intensity (FTRI, %)	0.518	0.605	0.311 (± 0.139)

According to this mechanism of laser effect, in the present study, PDL therapy was used to treat vocal fold bowing to achieve recovery of mucosal scarring. The study demonstrated improvement in subjective and objective voice measures, such as Jitt, Shim and F0 factors (Table 1) and laryngeal stroboscopy findings in the mucosal wave after treatment.

The patient who underwent PDL surgery had improvement in postoperative voice assessment including aerodynamic and acoustic findings except Fo-tremot intensity (FTRI) (Table 1).

Despite numerous surgical and behavioral therapies for vocal cord bowing, the efficacy of voice therapy suggested that more definitive treatment should be undertaken.¹⁵

Surgical interventions, such as intracordal injection and thyroplasty have been used with temporary effectiveness in reduction of glottal gap; however, long-term results in subjective and objective outcomes were not completely satisfactory.³⁻⁵

PDL therapy which effectively removes the lesion while preserving function may be a new paradigm in the management of vocal fold bowing.

Although postoperative laryngoscopic and voice analyses showed improvement, this study has certain limitations regarding full voice recovery. Additional research is needed, however, to define the therapeutic efficacy of such treatment.

REFERENCES

- Shimokojin T, Takenoshita M, Sakai T, Yoshikawa K. Vocal cordal bowing as a cause of long-lasting hoarseness after a few hours of tracheal intubation. *Anesthesiology* 1998;89(3): 785-87.
- Lagorio LA, Carnaby-Mann GD, Crary MA. Treatment of vocal fold bowing using neuromuscular electrical stimulation. *Arch Otolaryngol Head Neck Surg* 2010;136(4):398-403.
- Behrman A. Evidence-based treatment of paralytic dysphonia: making sense of outcomes and efficacy data. *Otolaryngol Clin North Am* 2004;37(1):75,104.
- Dursun G, Boynukalin S, Ozgursoy OB, Coruh I. Long-term results of different treatment modalities for glottic insufficiency. *Am J Otolaryngol* 2008;29(1):7-12.
- Thomas LB, Harrison AL, Stemple JC. Aging thyroarytenoid and limb skeletal muscle: Lessons in contrast. *J Voice* 2008;22(4):430-50.
- Golub JS, Chen PH, Otto KJ, Hapner E, Johns MM (3rd). Prevalence of perceived dysphonia in a geriatric population. *J Am Geriatr Soc* 2006;54(11):1736-39.
- Roy N, Stemple J, Merrill RM, Thomas L. Epidemiology of voice disorders in the elderly: Preliminary findings. *Laryngoscope* 2007;117(4):628-33.
- Tanner K, Sauder C, Thibeault SL, Dromey C, Smith ME. Vocal fold bowing in elderly male monozygotic twins: A case study. *J Voice* 2010;24(4):470-76.
- Kim JH, Choi HS. The efficiency of treatment for vocal fold disease by pulsed dye laser (PDL). *J Clinical Otolaryngol* 2010;21:164-68.
- Franco RA Jr, Zeitels SM, Farinelli WA, Faquin W, Anderson RR. 585-nm pulsed dye laser treatment of glottal dysplasia. *Ann Otol Rhinol Laryngol* 2003;112(9 Pt 1):751-58.
- Hartnick CJ, Boseley ME, Franco RA Jr, Cunningham MJ, Pransky S. Efficacy of treating children with anterior commissure and true vocal fold respiratory papilloma with the 585-nm pulsed-dye laser. *Arch Otolaryngol Head Neck Surg* 2007; 133(2):127-30.
- Mortensen MM, Woo P, Ivey C, Thompson C, Carroll L, Altman K. The use of the pulse dye laser in the treatment of vocal fold scar: A preliminary study. *Laryngoscope* 2008;118(10): 1884-88.
- Bouzari N, Davis SC, Nouri K. Laser treatment of keloids and hypertrophic scars. *Int J Dermatol* 2007;46(1):80-88.
- Karsai S, Roos S, Hammes S, Raulin C. Pulsed dye laser: What's new in nonvascular lesions? *J Eur Acad Dermatol Venereol* 2007;21(7):877-90.
- Ford CN, Inagi K, Khidr A, Bless DM, Gilchrist KW. Sulcus vocalis: A rational analytical approach to diagnosis and management. *Ann Otol Rhinol Laryngol* 1996;105(3):189-200.

ABOUT THE AUTHORS

Yong Cheol Koo

Department of Otorhinolaryngology, Yonsei University College of Medicine, Seoul, Republic of Korea

Hyo Jin Chung

Department of Otorhinolaryngology, Yonsei University College of Medicine, Seoul, Republic of Korea

Michelle J Suh

Department of Otorhinolaryngology, Yonsei University College of Medicine, Seoul, Republic of Korea

Hong-Shik Choi (Corresponding Author)

Department of Otorhinolaryngology, Institute of Logopedics and Phoniatrics, Yonsei University College of Medicine, 211 EONJU-RO Gangnam-Gu, Seoul 135-720, Republic of Korea, Phone: 82-2-2019-3461 Fax: 82-2-3463-4750, e-mail: hschoi@yuhs.ac