10.5005/jp-journals-10021-1034
CASE REPORT

Bilateral Maxillary Canine-Premolar Transposition

[1]Nishant Kuttapa, [2]US Krishna Nayak, [3]Ashutosh Shetty, [4]PS Murali

ABSTRACT

Tooth transposition is a severe disturbance of tooth order and eruptive position, involving certain teeth that may occur at any of the several sites in the mouth. Maxillary canine-first premolar (MxCP1) transposition is the most frequent tooth transposition. This case report presents the treatment of female patient with bilateral maxillary canine-premolar transposition. The order of transposition was maintained during the treatment.

Keywords: Bilateral canine transposition, Maxillary canine to first premolar, Ectopic eruption, Orthodontic management.

How to cite this article: Kuttapa N, Nayak USK, Shetty A, Murali PS. Bilateral Maxillary Canine-Premolar Transposition. J Ind Orthod Soc 2011;45(4):193-197.

INTRODUCTION

Transposition of maxillary teeth is a disturbance of eruptive position, occurring approximately in one of 300 orthodontic patients.[1] Maxillary canine-first premolar (MxCP1) transposition is the most frequent tooth transposition. Tooth transposition is defined as the positional interchange of two adjacent teeth, especially their roots, or the development or eruption of a tooth in a position occupied normally by a nonadjacent tooth.[2] Treatment planning for this anomaly centers on whether to maintain the transposed tooth order or correct it. There is general agreement[3,4] on keeping the transposed tooth order in most cases, especially in adults. But when detected early enough, transpositions can sometimes be corrected without damaging the canine and the first premolar roots.[3-6]

CASE REPORT

A 21-year-old female patient reported to the department of orthodontics with a complaint of retained milk teeth and forwardly placed adjacent teeth. Her face was proportional and symmetric, with a straight profile (Fig. 1). All permanent teeth (except the third molars in the third quadrant) were erupted, and the deciduous maxillary canines were retained. There was mild dental crowding in both arches. The maxillary right and left canine had erupted buccally between the premolars and the left first premolar was rotated. On radiographic examination, there was no resorption of the root of the deciduous canine and transposition of the crowns and the roots of the maxillary right canine and first premolar, with the roots diverging apically (Fig. 2). The interarch relationship was Angle Class I, with 30% over bite and normal overjet. Cephalometric analysis showed a skeletal Class I relationship (ANB angle = 3°) with an average growth pattern (SNGoGn = 32°).

Etiologic possibilities for the transposition included genetics (although there were no similar cases in the patient's family), retained primary teeth, deviation of the affected tooth during the path of eruption, and abnormality in the sequence of eruption with consequent lack of space for the maxillary canine.

Treatment Objectives

Because facial appearance was satisfactory, correction of crowding while maintaining a pleasing profile was the treatment goal. The treatment objectives were to (1) maintain Class I molar and canine relationship, (2) maintain ideal overjet and over bite, (3) correct the alignment of transposed canines and first premolars, (4) maintain facial balance.

Treatment Alternatives

- Correcting the order of transposed teeth
- Maintaining the order of transposed teeth
- Extraction of one of the transposed teeth.

Treatment Plan

The orthodontic treatment plan of choice involved the correction of transposition (in the order of transposition) without the extraction of the premolars. A 0.022" preadjusted edgewise system (MBT prescription) was used and the right deciduous canine was extracted in the initial stages of the treatment.

[1,3]Professor, [2]Dean Academics, Professor and Head, [4]Postgraduate Student
[1-4]Department of Orthodontics, AB Shetty Memorial Institute of Dental Sciences, Mangalore, Karnataka, India

Corresponding Author: Krishna Nayak, Dean Academics Professor and Head, Department of Orthodontics, AB Shetty Memorial Institute of Dental Sciences, Mangalore, Karnataka India, e-mail: dr_krishnanayak@yahoo.com

Received on: 27/8/11
Accepted after Revision: 11/11/11

Fig. 1: Pretreatment extraoral and intraoral photographs

Fig. 2: Pretreatment lateral cephalogram and OPG

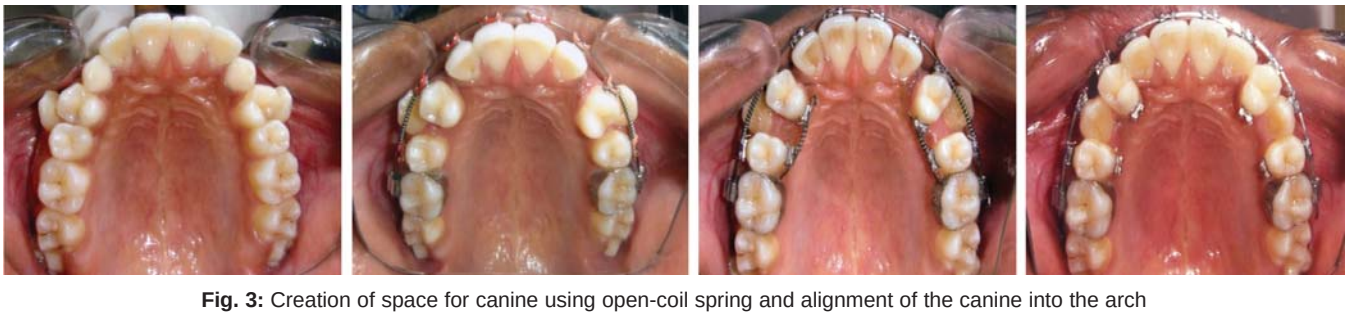

Fig. 3: Creation of space for canine using open-coil spring and alignment of the canine into the arch

Treatment Progress

After extraction of the deciduous canines, the permanent first molars were banded; during the bonding procedure, the canine bracket was bonded onto the first premolar crown to achieve the canine prominence. Alignment was carried out upto 0.016" NiTi progressively and then 0.018" Australian stainless steel archwire was placed with open-coil spring between first and the second premolars to gain space for the buccally transposed canine (Fig. 3). The canine was then bonded with the premolar bracket and aligned into the arch.

During the mesialization, the roots of left first premolar became prominent (Fig. 4A). For effective torque control, the miniscrew (bracket head type) was inserted between the roots of the left lateral and canine (1.3 mm diameter and 8 mm length). A TMA archwire was bent so that one end could be inserted into the bracket slot while the other end is connected to the miniscrew head, creating a lever arm (Fig. 4B). A pullout force was applied onto the implant, which brought about the palatal root movement while the base archwire (Fig. 4C) prevented the buccal flaring or extrusion of the teeth.

RESULTS

The maxillary canines and the first premolars were successfully aligned into the arch maintaining the order of transposition (Fig. 5). Ideal overjet and over bite with Angle's Class I molar relationships were maintained. Good intercuspation and root

Figs 4A to C: (A) Increased prominence of maxillary left first premolar root, (B and C) Miniscrew placed between the roots of left lateral and canine roots and engagement of long lever arm made of 0.017 × 0.025 TMA

Fig. 5: Posttreatment intraoral and extraoral photographs

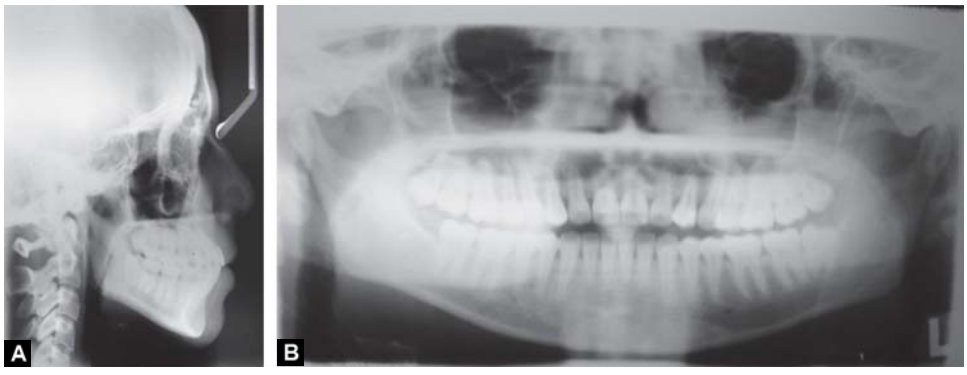

Figs 6A and B: Posttreatment lateral cephalogram and OPG

parallelism were achieved in the area of transposition (Figs 6A and B). Patient's pleasing facial profile was maintained.

DISCUSSION

The best time for intervention in maxillary canine transposition is, when the cusp tip of the maxillary canine tooth germ is positioned superior to the root of the first premolar. In this situation, the first premolar root can be tipped distally, thus correcting the transposition, so that the permanent canine can be guided into its correct position. As the patient age was 21 years, the favorable stage described by Peck for correcting tooth transposition had already passed.[2]

To achieve the treatment objectives, two possibilities were considered: treating the patient with or without premolar extractions. Treatment with extractions of the four first premolars and the deciduous canine would make the elimination of the dental crowding and the correction of position of the transposed canine easier; it would also be a faster treatment with simpler mechanics. However, it would impair the patient's facial profile, which was already straight. Treatment without premolar extractions included two possibilities: aligning the teeth in the transposed order or correcting the transposition. Correcting the transposition would take longer and require patient compliance. Also, it would be difficult to correct the transposition without causing damage to the supporting tissues and avoiding root resorption due to root interference. This approach would provide a dental esthetics with gingival contour, root eminence, crown morphology and functional occlusion with good intercuspation.[7] Aligning the teeth in the transposed order would probably require less treatment time than correcting the transposition but would have still been difficult because space had to be obtained before aligning the canine into its transposed position.

In this case, decidous canines were extracted and created space for the transposed canines by mesialization of the first premolar. Even though it was a simpler method of treatment, was encountered root prominence of upper left first premolar (Fig. 4A). To correct this root prominence using conventional mechanics, a force of as much as 2000 gm per side (about 1250 gm of moment in the slot) is needed,[8,9,11] this force may result in damage to the periodontium. By increasing the length of the lever arm (distance between the forces) by about 10 mm the miniscrew-assisted technique for torque control described, can reduce the required force to about 125 gm. Huja et al reported that the pull-out strength of miniscrews was sufficient to support tooth-moving force,[10] but the associated moment may result in flaring or extrusion of the teeth. To minimize these undesirable side effects, the archwire should be kept in contact with the incisal third of the labial crown surfaces.[12]

The disadvantages of maintaining the order of transposition included possible finishing difficulties and interferences during mandibular movements, which would require occlusal adjustments. The differences in the size, shape, and tooth color between canine and premolar sometimes cause anterior esthetic problems. The gingival contour of the premolar is lower, relative to the canine, and this may require a gingival recontouring procedure. The palatal cusp of the transposed premolar (maintained in the position of the canine) might cause functional interference despite control of its angulations, torques and reshaping. Prosthetic restoration after pulpectomy may be necessary to recontour the premolar, to resemble a canine. Although these procedures were explained to the patient as a necessary part of treatment plan, if the order of transposition is maintained, the patient opted not to have gingival contouring and coronoplasty done. Therefore, occlusal equilibration for the premolar was done to achieve optimum intercuspation.

CONCLUSION

Management of transpositions must be assessed on a case-to-case basis. Dental transposition can be corrected orthodontically, but the mechanics are complex, treatment time is long, and damage is possible to the supporting dental tissues. Patient compliance, the practitioner's skill and experience, esthetics and function should all be considered when deciding whether treatment of the transposition should involve tooth extractions, tooth alignment in the transposed order or complete correction of the transposition orthodontically.

REFERENCES

1. Sandham A, Harvie H. Ectopic eruption of the maxillary canine resulting in transposition with adjacent teeth. Tandlaegebladet 1985;89:9-11.
2. Peck L, Peck S, Attia Y. Maxillary canine-first premolar transposition, associated dental anomalies and genetic basis. Angle Orthod 1993;63:99-109.

3. Peck S, Peck L. Classification of maxillary tooth transpositions. Am J Orthod Dentofacial Ortho 1995;107:505-17.
4. Shapira Y. Transposition of canines. J Am Dent Assoc 1980;100:710-12.
5. Sato K, Yokozeki M, Takagi T, Moriyama K. An orthodontic case of transposition of the upper right canine and first premolar. Angle Orthod 2002;72:275-78.
6. Bocchieri A, Braga G. Correction of a bilateral maxillary canine first premolar transposition in the late mixed dentition. Am J Orthod Dentofacial Orthop 2002;121:120-28.
7. Daniel CS Ngam, Om P Kharpanda, M Ali Darendeliler. Cosideration in management of transposed teeth. Aust Orthod J 2004;20:41-50.
8. Burstone CJ. The mechanics of the segmented arch techniques. Angle Orthod 1966;36:99-120.
9. Kusy RP, Tulloch JF. Analysis of moment/force ratios in the mechanics of tooth movement. Am J Orthod 1986;90:127-31.
10. Haskell BS, Spencer WA, Day M. Auxiliary springs in continuous arch treatment, Part 1: An analytical study employing the finite-element method. Am J Orthod 1990;98:387-97.
11. Meling TR, Odegaard J. The effect of second-order couple on the application of torque. Am J Orthod 1998;113:256-62.
12. Huja SS, Litsky AS, Beck FM, Johnson KA, Larsen PE. Pull-out strength of monocortical screws placed in the maxillae and mandibles of dogs. Am J Orthod 2005;127:307-13.