10.5005/jp-journals-10011-1237

CASE REPORT

Non-Hodgkin's Lymphoma involving Base of Tongue

[1]Divyambika CV, [2]Satish Srinivas K, [3]Shanmugam S

[1]Senior Lecturer, Department of Oral Medicine and Radiology, Faculty of Dental Sciences, Sri Ramachandra University Chennai, Tamil Nadu, India

[2]Former Assistant Professor, Department of Oncology, Sri Venkateswara Institute of Medical Sciences, Tirupati, Andhra Pradesh, India

[3]Profesor and Head, Department of Oral Medicine and Radiology, Ragas Dental College, Chennai, Tamil Nadu, India

Correspondence: Divyambika CV, Senior Lecturer, Department of Oral Medicine and Radiology, Faculty of Dental Sciences, Sri Ramachandra University, Porur, Chennai-600116, Tamil Nadu, India, e-mail: divyambika@rediffmail.com

ABSTRACT

Waldeyer's ring is the primary site of non-Hodgkin's lymphoma (NHL) involvement in approximately 5 to 10% of all lymphoma patients. Lymphomas arising from base of the tongue are less frequent, accounting for 7% of all primary Waldeyer's ring NHLs. We report a case of NHL involving the base of tongue in a 30-year-old man who complained of dysphagia and swelling of neck. Clinical examination, radiographic, histopathological features, current understanding of disease with review of literature is offered.

Keywords: Waldeyer's ring, Lymphoma, Dysphagia.

INTRODUCTION

Non-Hodgkin's lymphoma (NHL) consists of a group of malignancies of the cells of the lymphocyte developmental pathway of the immune system. The different histological subtypes vary widely in their clinical behavior, progress and management, and there is some evidence that the different subgroups of NHL have differing epidemiological features.[1] The exact cause of these cancers is not fully understood but it is believed to be caused by an altered or depressed immune system.

CASE REPORT

A 30-year-old male patient presented with complaints of dysphagia to solids and swelling involving left side of neck for past 3 months. Patient did not give history of fever or night sweats.

On examination of the neck, a 4 × 3 cm firm nontender, single node with restricted mobility was seen in left level II region and another node of size 2 × 2 cm palpated in the right level II area. On intraoral examination, a red, smooth lobulated swelling with some areas of ulceration was seen occupying the posterior third of tongue in the midline extending below (Fig. 1). Video laryngoscopy revealed a lobulated swelling involving posterior 1/3rd of tongue extending onto left vallecula and just extending to epiglottis (Fig. 2). Rest of larynx and hypopharynx were normal.

Patient was subjected to complete hemogram which was normal except for lymphocytosis and raised ESR. Peripheral smear showed no evidence of blasts cells. Renal function and liver function tests were normal and patient was negative for HIV.

CT PNS and neck with contrast revealed, soft tissue density in posterior aspect of tongue of size 4 × 2.8 cm involving anterior surface of epiglottis and vallecula and bilateral cervical adenopathy with the largest node measuring 4.2 × 2.5 cm (Fig. 3). CT chest showed no evidence of mediastinal adenopathy, parenchymal or pleural disease. CT abdomen with contrast showed liver and spleen to appear normal in size and did not reveal any parenchymal lesion and intra-abdominal nodes.

DIAGNOSIS

Biopsy showed a submucosal lesion made up of atypical small blue cells showing increased number of mitosis suggestive of

Fig. 1: Intraoral examination showing lesion in posterior 1/3rd of tongue

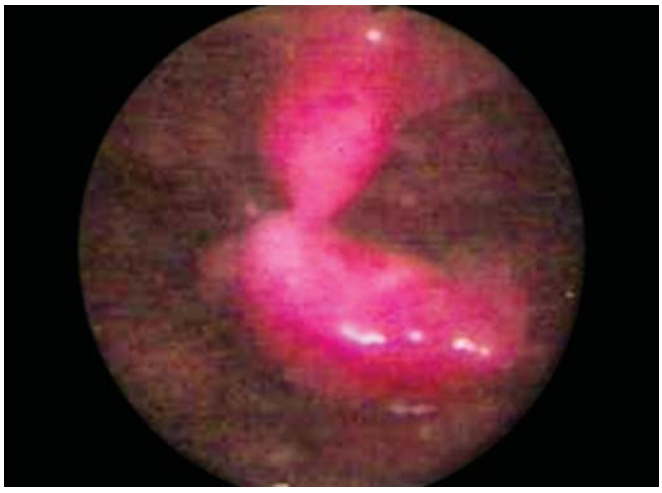

Fig. 2: Video laryngoscope images of the lesion

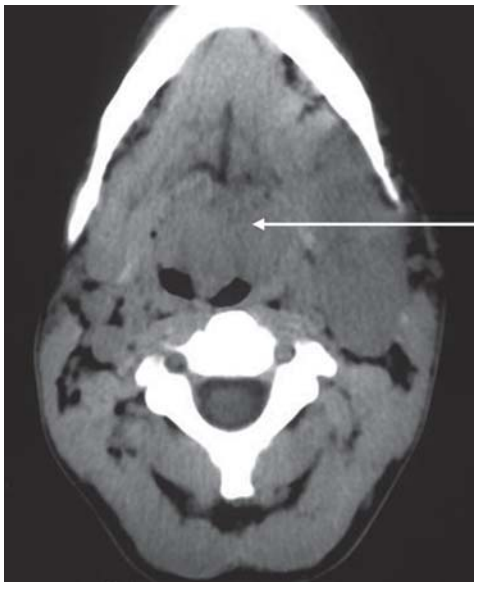

Fig. 3: Axial images showing lesion in posterior aspect of tongue involving epiglottis and vallecula and cervical lymphadenopathy

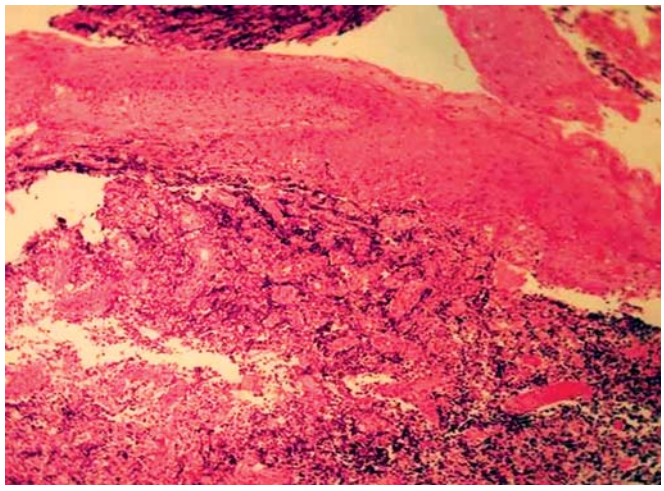

Fig. 4: HPE showing submucosal lesion made up of atypical small blue cells with increased number of mitosis suggestive of diffuse large B-cell lymphoma

diffuse large B-cell lymphoma (DLBCL) (Fig. 4). Patient subsequently underwent bone marrow biopsy which showed infiltration with lymphoma cells. Immunohistochemistry was positive for CD 45 and CD 20 and negative for CD 3 suggestive of B cell NHL. The final diagnosis made was that of diffuse large B cell lymphoma of Waldeyer's ring involving posterior third of tongue with bone marrow involvement (stage IV disease).

Patient received eight cycles of chemotherapy with CHOP regime (cyclophosphamide, doxorubicin, vincristine, prednisolone). Rituximab could not be added due to logistics. The intraoral mass disappeared at the end of the 4th cycle of chemotherapy and patient is currently disease-free of disease at 2 years of follow-up.

DISCUSSION

Malignant lymphoma is the generic term given to tumors of the lymphoid system. These tumors are divided into two major categories: Hodgkin's lymphoma and non-Hodgkin's lymphoma (NHL). Non-Hodgkin's lymphoma is a heterogeneous group of malignancies characterized by an abnormal clonal proliferation of T cells, B cells, or both. The majority of the adult non-Hodgkin's lymphomas are of B cell origin.[2] The exact cause of non-Hodgkin's lymphoma remains unknown. However, research has focused on some factors that may contribute to the development of lymphoma, including genetic factors, impaired immune system and viruses, such as HIV.

NHL may arise in lymph nodes with or without involvement of lymphoid organs, such as spleen, and extralymphatic lymphoid tissues, such as Peyer's patches and Waldeyer's ring. They also have great tendency to affect extralymphatic organs. The head and neck is the second most common region for the extranodal lymphoma, the first being gastrointestinal tract. Extranodal NHLs of the head and neck region occur predominantly in patients between 50 and 60 years of age.[3] The male-to-female ratio is 1.6:1.[4] Among various head and neck sites, Waldeyer's ring is the most often site involved.[5]

Waldeyer's ring consists of lymphoid tissue of the nasopharynx and oropharynx and comprises the adenoids (pharyngeal tonsil), pharyngeal openings of the Eustachian tube (tubal or Gerlach's tonsils), palatine tonsils, as well as the lymphoid tissue of the soft palate and posterior third or the base of tongue (lingual tonsil).[6,7] Together, these form a circular structure guarding the entrance to the upper aerodigestive tract.[8] Waldeyer's ring is the primary site of NHL involvement in approximately 5 to 10% of all lymphoma patients. Of all Waldeyer's ring NHLs, the tonsil is the most frequent site, followed by the nasopharynx. Lymphomas arising from base of the tongue are less frequent, accounting for 7% of all primary Waldeyer's ring NHLs.[4,9,10] The possible differential diagnosis includes squamous cell carcinoma (SCC), which is the most common malignancy of the tongue base,[11] salivary gland malignancy, (adenoid cystic carcinoma or mucoepidermoid carcinoma)[12] and infection processes, such as tuberculosis were also considered.[13]

The DLBCL is the most common histological type of primary oral and oropharyngeal NHL forming 66 to 75% of all lymphomas. Diffuse large B-cell lymphoma is composed of patternless sheets of large, transformed lymphoid cells with variable cytoplasmic content and enlarged, vesicular nuclei containing dispersed (activated) chromatin that allows one to several nucleoli to become visible in each nucleus. This turns out to be the largest group of lymphomas involving the Waldeyer's ring.[8]

Generally, CHOP-based chemotherapy with rituximab is the current standard of treatment.[14] Involved field RT is added in bulky early stage disease as consolidation. According to the international prognostic index (IPI) established for patients aged less than 60 years, the outcome of patients with extranodal DLBCL is similar to that of patients with nodal DLBCL.[14]

CONCLUSION

The vast majority of lymphomas of the oropharyngeal region are of the B-cell rather than the T-cell type. Treatment recommendation for diffuse large B-cell lymphoma is generally identical for nodal and extranodal diseases. The use of chemotherapy is based on the principle that DLBCL of the head and neck must be considered a localized manifestation of systemic disease.[14] The above-mentioned case report highlights a rare presentation of extranodal lymphoma presenting in an advanced stage with good disease control with chemotherapy.

REFERENCES

1. Cartwright R, Brincker H, Carli PM, Clayden D, et al. The rise in incidence of lymphomas in Europe 1985-1992. European Journal of Cancer 1999;35:627-33.
2. Evans LS, Hancock BW. Non-Hodgkin lymphoma. Lancet 2003;362:139-46.
3. Jacobs C, Weiss L, Hoppe RT. The management of extranodal head and neck lymphomas. Arch Otolaryngol 1986;112: 654-58.
4. Ezzat AA, Ibrahim EM, Ei Weshi AN, Khafaga YM, Martin JM, Ajarim DS, et al. Localized non-Hodgkin's lymphoma of Waldeyer's ring: Clinical features, management, and prognosis of 130 adult patients. Head Neck 2001;23: 547-58.
5. Sankaranarayanan S, Chandrasekar T, Rao P Srinivasa, Rooban T, Ranganathan K. Maxillary non-Hodgkins lymphoma. Journal of Oral and Maxillofacial Pathology 2005;9(1):34-36.
6. Mills SE, Fechner RE. Larynx and pharynx. In: Sternberg SS, editor. Histology for pathologists (2nd ed). Philadelphia: Lippincott-Raven 1997:391-404.
7. Isacson PG, Norton AJ. Extranodal lymphomas. Edinburgh: Churchill Livingstone 1994:195-215.
8. Tan LHC. Lymphomas involving Waldeyer's ring: Placement, paradigms, peculiarities, pitfalls, patterns and postulates. Ann Acad Med Singapore 2004;33(Suppl)4:15S-26.
9. Aviles A, Delgado S, Ruiz F, de la Torre A, Guzman R, Talavera. Treatment of non-Hodgkin's lymphoma of Waldeyer's ring: Radiotherapy verus chemotherapy versus combined therapy. Oral Oncol, Eur J Cancer 1996;32B:19-23.
10. Zucca E, Roggero E, Bertoni F, Conconi A, Cavalli F. Primary extranodal non-Hodgkin's lymphoma Part 2: Head and neck, central nervous system and other less common sites. Ann Oncol 1999;10:1023-33.
11. Silverman S. Epidemiology. In: American Cancer Society. Oral cancer, (4th ed). Canada: BC Decker Incorporated 1998:1.
12. Eisele DW, John ME. Salivary gland neoplasms. In Bailey BJ, Johnson JT, Kohut RI, Pillsbury HC III,Tardy ME Jr, editors: Head and neck surgery otolaryngology. Philadelphia: JB Lippincott Company 1993:1124-47.
13. Hao-Chieh Lin, Ting-An Chang, Kun-Lin Lin. Non-Hodgkins lymphoma presented as tongue base tumor. Changhua J Med 2003;8:190-93.
14. Ismail Essadi, Ismaili Nabil, Elmehdi Tazi, Sanaa Elmajjaoui, Ammar Saidi, Mohammed Ichou, Hassan Errihani. Primary lymphoma of the head and neck: Two case reports. Cases Journal 2008,1:426.