

## CASE REPORT

# Plexiform Neurofibroma as an Uncommon Cause of Periorbital Swelling

<sup>1</sup>Mohtasham Tauheed, <sup>2</sup>Yusuf Rizvi, <sup>3</sup>Vaibhav Yadav

## ABSTRACT

**Introduction:** Plexiform neurofibromas are benign tumors originating from subcutaneous or visceral peripheral nerves, which are usually associated with neurofibromatosis type I. Orbital neurofibromas are relatively rare and usually present with high infiltration into the periocular structures making the management extremely difficult.

**Purpose:** To report a case of plexiform neurofibroma with neurofibromatosis type I in a young boy managed satisfactorily with surgical excision.

**Materials and methods:** A 14-year-old boy presenting with a soft, painless, nontender, gradually enlarging swelling of the left upper eyelid and adjacent temporal region and of 6 years duration was managed with complete surgical excision. Histopathological examination of excised mass confirmed the diagnosis of neurofibroma.

**Results:** Satisfactory functional and cosmetic result was achieved following surgical excision of the subcutaneous fibromatous mass. A 1-year follow-up did not reveal any functional deficit or recurrence.

**Conclusion:** Plexiform neurofibroma may present as an uncommon cause of periorbital swelling even in the absence of typical features of neurofibromatosis type I and can be surgically managed to achieve acceptable cosmetic and functional results.

**Keywords:** Plexiform neurofibroma, Proptosis, Surgical excision.

**How to cite this article:** Tauheed M, Rizvi Y, Yadav V. Plexiform Neurofibroma as an Uncommon Cause of Periorbital Swelling. *Int J Adv Integ Med Sci* 2018;3(1):41-43.

**Source of support:** Nil

**Conflict of interest:** None

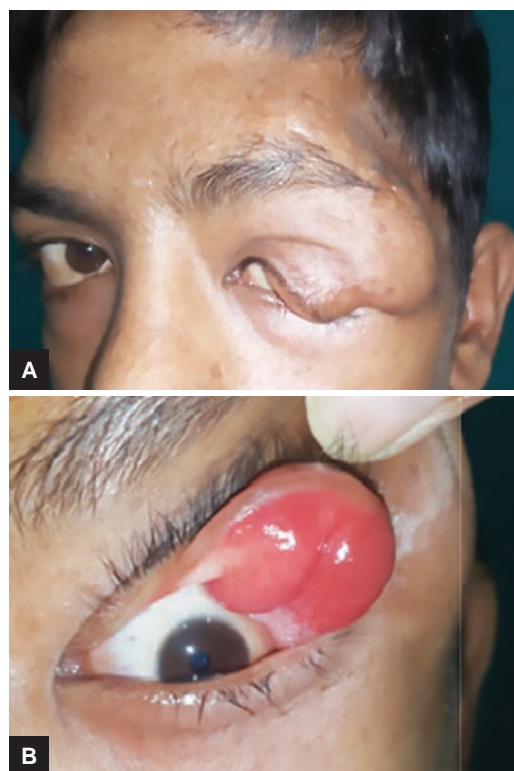
## INTRODUCTION

Neurofibromatosis<sup>1</sup> is a congenital hereditary disorder resulting from neuroectodermal and mesodermal dysplasia characterized by developmental anomalies and tumors of the nervous system, skeleton, viscera, and pigmented lesions of the skin. Incidence is 1 per 3,000 live births. Classical clinical features include café-au-lait

spots, multiple soft cutaneous tumors, and palpable neurofibroma of peripheral nerve. Neurofibromatosis of orbit and eyelid presents as plexiform neuroma with hypertrophied nerves giving the feel of a bag of worms or knotted cords.<sup>2</sup> Extensive involvement causes elephantiasis of eyelids and face (elephantiasis neuromatosa). Extension into temporal fossa is associated with bone defects allowing herniation of intracranial tissue into orbit and pulsatile exophthalmos. Plexiform neurofibromas are frequently locally invasive and may be associated with bone erosion and muscle entrapment. About 5% cases are reported with malignant transformation.<sup>3</sup>

## CASE REPORT

A 14-year-old boy presented with a gradually enlarging soft, painless swelling of the left upper lid of 6 years duration. Size of the swelling was 6 × 8 cm, involving the left upper eyelid and adjacent temporal region with a bag-of-worms feel (Fig. 1). There was no reported history of trauma or any other painful episode. Patient presented for visual obscuration produced due to overhanging eyelid.

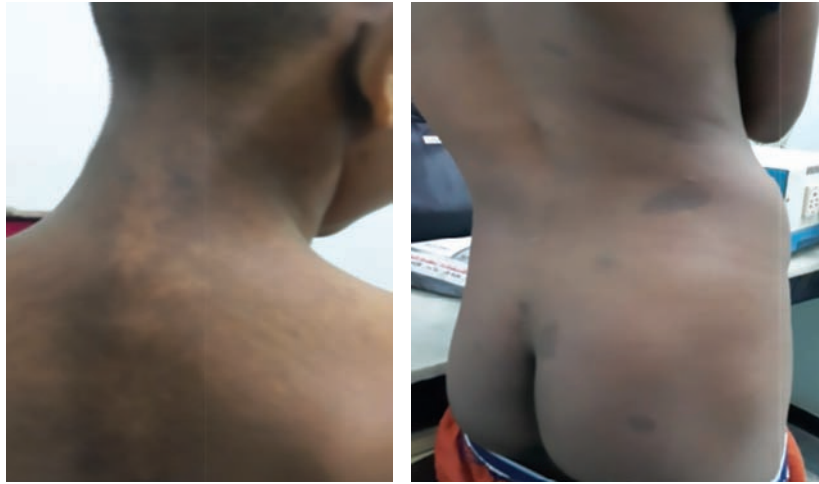

**Figs 1A and B:** Plexiform neurofibromatosis. (A) Anterior view, (B) on lid eversion

<sup>1,3</sup>Junior Resident, <sup>2</sup>Professor

<sup>1-3</sup>Department of Ophthalmology, Rohilkhand Medical College and Hospital, Bareilly, Uttar Pradesh, India

**Corresponding Author** Mohtasham Tauheed, Junior Resident, Department of Ophthalmology, Rohilkhand Medical College and Hospital, Bareilly, Uttar Pradesh, India e-mail: Drabhinavsrivastava7@gmail.com



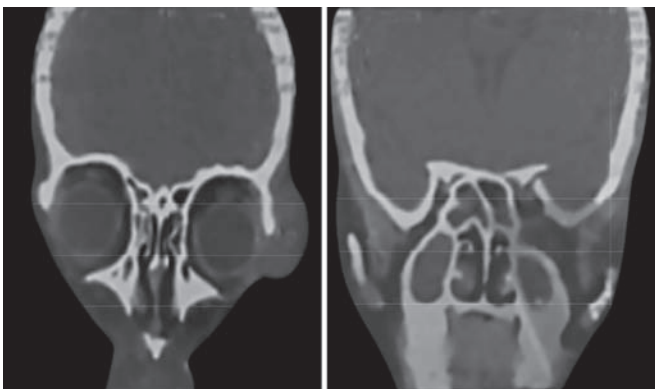
**Figs 2A and B:** Café-au-lait spots. (A) Nape of neck, (B) lumbar torso

There was no noted proptosis of globe or pulsations and no skin discoloration. On retraction of the lids, the patient revealed good vision in both eyes (6/6 in right eye and 6/9 in left eye). There was no restriction of extraocular movements. Anterior and posterior ocular examinations were unremarkable. Intraocular pressure noted by Schiottz tonometer was 14.6 and 15.9 mm Hg in the right and left eyes respectively.

General body examination revealed multiple pigmented spots (café-au-lait) (Fig. 2) over neck, back, lower torso, and upper limbs with a maximum diameter of 2.5 cm. No other coexisting features suggesting neurofibromatosis type I were noted.

Noncontrast computerized tomography (NCCT) (Fig. 3) revealed a cystic lesion in the lateral aspect of the left supraorbital region with no bony erosion.

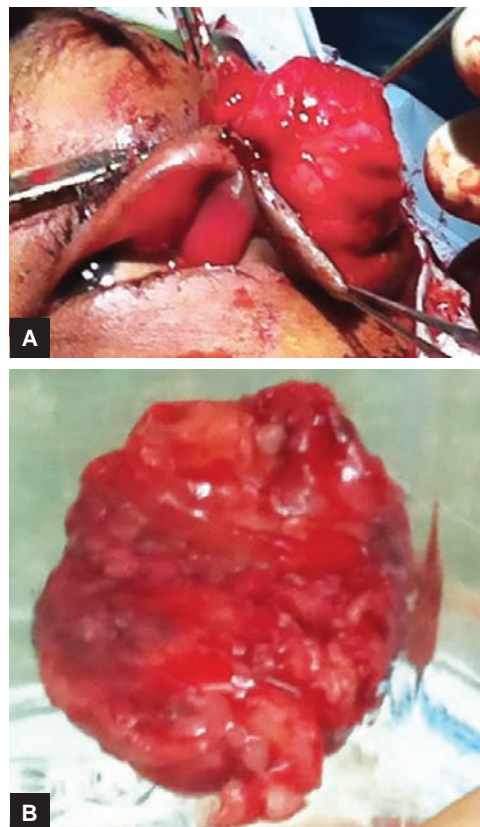
Hematological investigations were unremarkable (hemoglobin 12.5 gm%, total leukocyte count 9000/mm<sup>3</sup>, differential leukocyte count: N<sub>49</sub> L<sub>37</sub> E<sub>13</sub> M<sub>1</sub>, bleeding time 2 minutes, clotting time 4.3 minutes, prothrombin time (PT) 13.8 seconds (PT with international normalized ratio 1.14). The erythrocyte sedimentation rate was marginally raised, 32 mm.



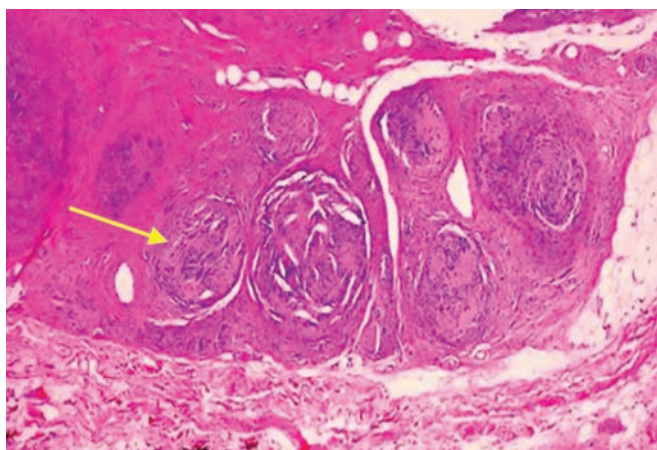
**Fig. 3:** The NCCT (coronal section) shows plexiform neurofibromatosis with no bony erosion

Viral markers, however, revealed an australia antigen-positive status. Routine X-ray chest and ultrasound abdomen did not reveal any lesion. The fine needle aspiration cytology attempted from the most prominent site of swelling revealed a serosanguinous sample with no inflammatory or malignant cells detected microscopically.

Under general anesthesia, a wide surgical excision with a 6-cm left lateral curved slice incision over upper lid extending into temporal zone was done. Meticulous dissection of the tumor was aided with a microscope and electrocautery (Fig. 4). Resected mass was removed *en bulk* and sent for histopathological examination. The



**Figs 4A and B:** (A) Surgical excision. (B) Excised mass



**Fig. 5:** Multiple tortuous enlargements of cutaneous peripheral nerves with distinct proliferative nodules signifying plexiform neurofibroma

section was closed in two layers using 5-0 Vicryl and 5-0 silk for muscle and skin layers respectively.

Excised mass on histopathological examination (Fig. 5) showed multiple tortuous enlargements of cutaneous peripheral nerves with distinct proliferative nodules signifying plexiform neurofibroma.

Postoperative recovery was uneventful with no sensory or motor deficit. A 1-year follow-up did not reveal any recurrence.

## DISCUSSION

Plexiform neurofibromas of orbit are usually associated with a high degree of local infiltration that may involve extraocular muscles and nerves including the optic nerve. Long-standing neurofibromas are usually associated with bony erosions and occasionally infiltration into the cranium. Complete tumor resection is fraught with the risk of extensive hemorrhage, inadvertent intracranial extension, functional deficit of eye, high rate of infection, and recurrence.<sup>4</sup> Surgical techniques employing radiofrequency dissector, gamma knives, and sequential embolization although advantageous may still end with disconcerting results. Microdissection of the tissue employing a surgical microscope and electrocautery may end with comparable results as revealed by our case

management. Judicious patient selection for such surgical intervention is mandatory for attaining satisfactory outcomes. The NCCT of the orbit ruling out intracranial extension and stationary nature of lesion are good indicators for favorable surgical outcomes.<sup>5,6</sup> Growth of such neurofibromas is common during early childhood and puberty. Malignant transformation must be considered when such growth is reported in the later stages of life.<sup>7</sup> Early surgical intervention may go a long way in stalling such fatal malignant transformations and may ensure good cosmesis and functionality.

## CONCLUSION

Plexiform neurofibroma may present as an uncommon cause of periorbital swelling even in the absence of typical features of neurofibromatosis type I and can be surgically managed to achieve acceptable cosmetic and functional results.

## REFERENCES

1. Savar A, Cestari DM. Neurofibromatosis type I: genetics and clinical manifestations. *Semin Ophthalmol* 2008 Jan-Feb; 23(1):45-51.
2. Erb MH, Uzcategui N, See RF, Burnstine MA. Orbitotemporal neurofibromatosis: classification and treatment. *Orbit* 2007 Dec;26(4):223-228.
3. Ducatman BS, Scheithauer BW, Piepgras DG, Reiman HM, Ilstrup DM. Malignant peripheral nerve sheath tumors. A clinicopathologic study of 120 cases. *Cancer* 1986 May;57(10): 2006-2021.
4. Sippel KC. Ocular findings in neurofibromatosis type 1. *Int Ophthalmol Clin* 2001;41(1):25-40.
5. Avery RA, Dombi E, Hutcheson KA, Acosta MT, Baldwin AM, Madigan WP et al. Visual outcomes in children with neurofibromatosis type 1 and orbitotemporal plexiform neurofibromas. *Am J Ophthalmol* 2013 Jun;155(6):1089.e1-1094.e1.
6. Dalla Via P, Opocher E, Pinello ML, Calderone M, Viscardi E, Clementi M, Battistella PA, Laverda AM, Da Dalt L, Perilongo G. Visual outcome of a cohort of children with neurofibromatosis type 1 and optic pathway glioma followed by a paediatric neurooncology program. *Neuro Oncol* 2007 Oct;9(4): 430-437.
7. Hwang JM, Cheon JE, Wang KC. Visual prognosis of optic glioma. *Childs Nerv Syst* 2008 Jun;24(6):693-698.