

CASE REPORT

Fragment Reattachment of Two Teeth in a 12-year-old Child - A Case Report

Deepak Khandelwal¹, Namita Kalra², Rishi Tyagi³, Amit Khatri⁴, Dhiraj Kumar⁵, Sunil Kumar⁶

ABSTRACT

Coronal fractures are the most common form of dental trauma sustained by children and adolescents. Reattachment of a fractured fragment to the remaining tooth can provide esthetically pleasing results, providing that the fragment is available. The reattachment of a dental fragment may be performed for the treatment of traumatized anterior teeth, both in cases of simple coronal fracture or with complicated coronal fracture. The present article intends to present the successful clinical management of tooth fragment reattachment in one tooth with complicated crown fracture and other tooth with uncomplicated crown fracture.

Keywords: Coronal fragment, Dental trauma, Reattachment

How to cite this article: Khandelwal D, Kalra N, Tyagi R, Khatri A, Kumar D, Kumar S: Fragment Reattachment of Two Teeth in a 12-year-old Child - A Case Report. *Int J Oral Care Res* 2018;6(1):S97-99.

Source of support: Nil

Conflicts of interest: None

INTRODUCTION

Coronal (crown) fracture of the anterior teeth is a common form of dental trauma. It has a severe impact on the social and psychological well-being of a patient.^[1] Children of two specific age groups 2–3 years and 8–12 years sustain dental trauma more often, and boys suffer more than girls.^[2] The incidence of complicated coronal fractures ranges from 2% to 13% of all dental injuries, and the most commonly involved tooth is the maxillary central incisors.^[3] This could be due to their anterior position and protrusion caused by eruptive pattern.^[2] One of the options for managing coronal fractures, especially when there is no or minimal violation of the biological width, is the reattachment of the dental fragment when it is available. The case of reattaching a fractured incisor fragment was reported in 1964 by

Chosack was the first who reported case of reattaching a fractured in-cisor fragment in 1964.^[3] Since then, the technique has been subjected to various modifications and enriched with the advent of refined restorative techniques and materials.^[2] Reattachment is a way to restore the natural shape, contour, translucency, surface texture, occlusal alignment, and color of the fragment along with a positive emotional and social response from the patient to the preservation of natural tooth structure.^[4] Coronal fractures can be complicated or uncomplicated based on the extent of involvement of pulp.^[2] The present article intends to present the successful clinical management of tooth fragment reattachment in one tooth with complicated coronal fracture other tooth with uncomplicated coronal fracture.

CASE REPORT

A 12-year-old boy reported to the Department of Pedodontics and Preventive Dentistry, UCMS and GTB Hospital, Delhi, India, with the chief complaint of three broken upper front teeth. The patient revealed a history of fall from stairs 2 h back, where he had fractured the right maxillary central incisor (FDI # 11), right maxillary lateral incisor (FDI # 12), and left maxillary central incisor (FDI # 21). There was no relevant medical history. The father reported that they had brought broken teeth pieces in milk along with them.

On clinical examination, there was no soft tissue injury intra- or extra-orally. Tooth 21 had Ellis class 1 fracture, whereas 11 and 12 had Ellis class 3 fractures [Figure 1]. Fractured crown segment of two teeth (12 and 21) was brought in milk. Tooth fragment of 11 was not recovered by parents.

Various treatment options including reattachment of broken fragment were discussed with father along with their merits and demerits. Reattachment of 12 and 21 coronal fragments was considered as a treatment option after confirming the fit of fractured fragments on the respective teeth. It was planned to give 3M ESPE polycarbonate crown on 11 (since crown fragment was not recovered). Fractured coronal segments were stored in normal saline to prevent dehydration. Periapical radiograph showed complete roots with closed apices. No root/alveolar fractures or any periapical pathology was evident [Figure 2a].

¹Senior Resident, ²Professor and Head, ³Professor, ⁴Associate Professor, ^{5,6}Student

¹⁻⁶Department of Paedodontics and Preventive Dentistry, UCMS and GTB Hospital, New Delhi, Delhi, India

Corresponding Author: Deepak Khandelwal, Department of Paedodontics and Preventive Dentistry, UCMS and GTB Hospital, New Delhi, Delhi, India. e-mail: datsdeepak@yahoo.co.in

On the 1st day, fractured segment of 21 was reattached and root canal treatment of 11 and 22 was completed in a single sitting using AH plus sealer and gutta-percha cones. In the next visit, post-space preparation was completed in both teeth leaving behind 4 mm of gutta-percha in the apical region. The post space was etched for 12 and 21; bonding agent was applied and cured. A pre-fabricated fiber post (ParaPost Fiber Lux, Coltene Whaledent) was then cemented using flowable dual-cure resin cement (Rely-X, 3M) in both 12 and 21 [Figure 2b]. A retentive groove was prepared in the fractured coronal fragment of 12 to act as a retentive area and to receive the post. The alignment of the coronal fragment was assessed with the post in position. The inner surface of the coronal fragment was similarly etched and bonded to the tooth with dual cure resin cement. 11 was restored by polycarbonate crown [Figure 3]. The occlusion was carefully checked and adjusted. Instructions were given as to avoid heavy forces on these teeth to both patients and to follow regular oral hygiene practices. The patient has been under follow-ups.

DISCUSSION

Whenever the fractured fragment is available intact, the reattachment of the fragment should be considered as the most desired treatment as the reattachment procedure does not preclude any future treatment.^[3,5] In the pre-adhesive era, fractured teeth needed to be restored either with pin retained inlays or cast restorations that sacrificed the healthy tooth structure and were a challenge for clinicians.^[3] Clinical trials and long-term follow-up have reported that reattachment using modern dentin bonding agents or adhesive luting systems may achieve functional and esthetic success.^[6] In simple coronal fracture, the fragment may be reattached immediately. On the other hand, in complicated coronal fractures, the main concern should be the protection of the pulp and not necessarily the fragment.^[7] The factors to be considered while choosing an appropriate treatment protocol in complicated coronal fracture are time lag between injury and initiation of treatment, level of tooth fracture line, stage of root development, extent of pulp involvement, condition and availability of tooth fragments, and associated alveolar bone injury. Based on these factors, one can decide and deduce the feasibility of reattachment.^[2] Cavalleri reported that the long-term prognosis for reattached coronal fragments appears to be better than for composite resin restorations.^[8] In the present case, the fragments were brought in milk within 2 h of trauma and were never dehydrated. Disadvantages of reattachment can be that it may be less than ideal esthetics if the tooth fragment is allowed to

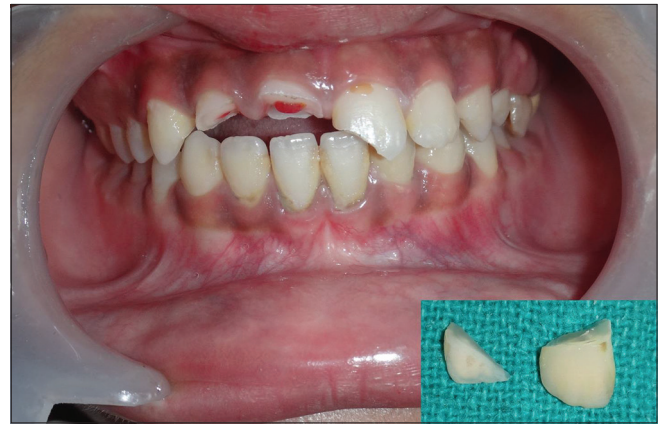

Figure 1: Pre-operative photograph and fractured coronal segments of 12 and 21

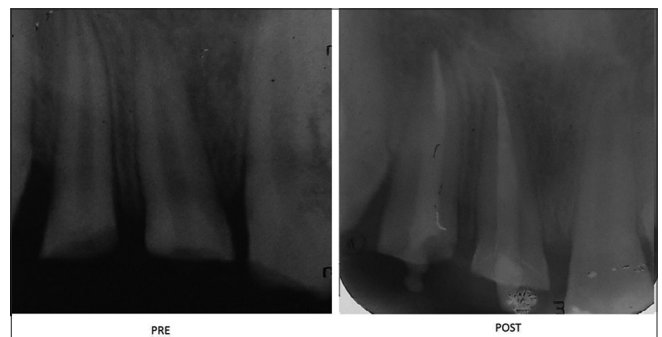


Figure 2: IOPA (a) pre (b) post

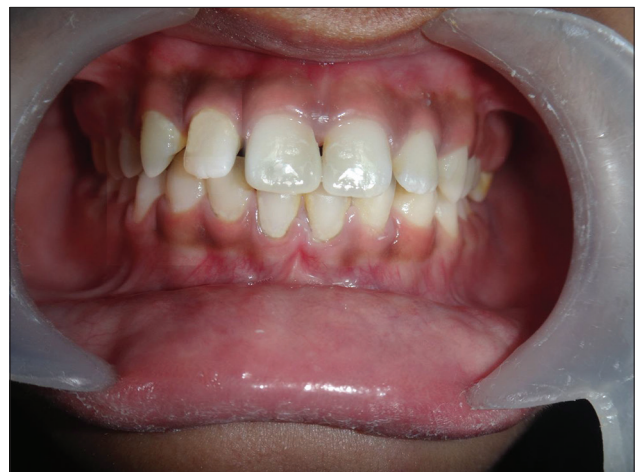

Figure 3: Post-operative photograph (polycarbonate crown on 11 and fractured coronal segments of 12 and 21 reattached)

dehydrate, color changes of the bonded fragment, and necessity for continuous monitoring.^[1]

With the materials available today, in conjunction with an appropriate technique, esthetic results can be achieved with predictable outcomes.^[9]

CONCLUSION

With the advancement in dental bonding technology, it is now possible to achieve excellent results with reattachment of fractured tooth fragments. However, these

techniques can be used only when the tooth fragment is available and the fracture line is supragingival or accessible after periodontal treatment.

REFERENCES

1. Maitin N, Maitin S, Rastogi K, Bhushan R. Allogeneous tooth fragment reattachment. *BMJ Case Rep* 2013. DOI: 10.1136/bcr-2013-010298.
2. Bharath KP, Patil RU, Kambalimath HV, Alexander A. Autologous reattachment of complicated crown fractures using intra canal anchorage: Report of two cases. *J Indian Soc Pedod Prev Dent* 2015;33:147-51.
3. Jagannath-Torvi S, Kala M. Restore the natural - A review and case series report on reattachment. *J Clin Exp Dent* 2014;6:595-8.
4. Vishwanath B, Faizudin U, Jayadev M, Shravani S. Reattachment of coronal tooth fragment: Regaining back to normal. *Case Rep Dent* 2013;2013:286186.
5. Chaugule V, Bhat C, Patil V, Mithiborwala SH. Reattachment of a vertical complicated subgingival crown root fracture in a 10-year old child: A case report. *Int J Clin Pediatr Dent* 2009;2:53-9.
6. Oz IA, Haytaç MC, Toroglu MS. Multidisciplinary approach to the rehabilitation of a crown-root fracture with original fragment for immediate esthetics: A case report with 4-year follow-up. *Dent Traumatol* 2006;22:48-52.
7. Fornaini C, Rocca JP. Reattachment of a fractured anterior tooth segment with pulp exposure via Er: YAG and Nd: YAG lasers. *Trauma Mon* 2015;20:e21470.
8. Cavalleri G, Zerman N. Traumatic crown fractures in permanent incisors with immature roots: A follow-up study. *Endod Dent Traumatol* 1995;11:294-6.
9. Macedo GV, Diaz PI, De O Fernandes CA, Ritter AV. Reattachment of anterior teeth fragments: A conservative approach. *J Esthet Restor Dent* 2008;20:5-18.