

CASE REPORT

A False Cord Mass: Can It be a Schwannoma?

¹Salman Amiruddin, ²Marina M Baki, ³Atiqah F Zakaria

ABSTRACT

A false cord mass is very rare, and the condition is associated with airway morbidity if it is not recognized and addressed at an early stage. The mass could be an extension from a glottic and subglottic area, and the tissue diagnosis is mandatory to rule out carcinoma. We are presenting an elderly woman who came to us due to worsening hoarseness with an endoscopic finding of false cord mass that turned out to be schwannoma as a histological diagnosis.

Keywords: False cord mass, Schwannoma, Supraglottic area.

How to cite this article: Amiruddin S, Baki MM, Zakaria AF. A False Cord Mass: Can It be a Schwannoma? *Int J Otorhinolaryngol Clin* 2018;10(2):64-65.

Source of support: Nil

Conflict of interest: None

CASE REPORT

A 71-year-old woman was referred for further management and treatment of a mass viewed endoscopically beneath the mucosa of her left false vocal cord. She was complaining of hoarseness for the past 6 months associated with mild dyspnea on exertion without any difficulty in swallowing. Further medical history was unremarkable, and physical examination was normal.

Flexible nasolaryngoscopy revealed a large smooth mass arising from the left false vocal cord, obscuring the view of the true vocal cord (Fig. 1) with intact mobility of the contralateral side. The case proceeded with computed tomography (CT) scan which showed a 22 × 23 × 28 mm well-defined submucosal mass in the left supraglottic area. It was hypodense, and heterogeneously confined within a capsule with no sign of infiltration or destruction of surrounding structures (Fig. 2). A direct laryngoscopic

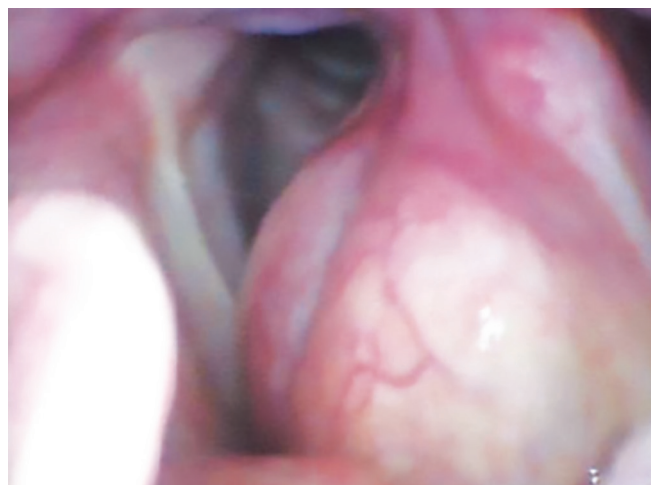

Fig. 1: A large submucosal mass within the left false vocal cord

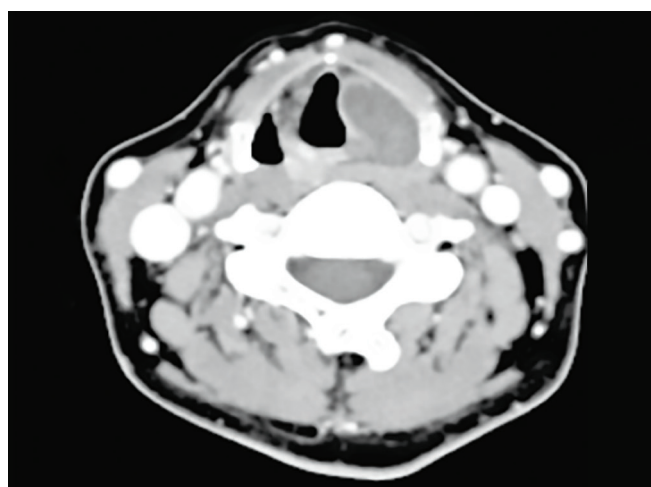


Fig. 2: Computed tomography scan showing a 22 × 23 × 28 mm well-defined submucosal mass in the left supraglottic area

examination was performed under general anesthesia, followed by transoral excision biopsy of the mass. Other structures of glottis and subglottis appeared normal. The extubation process was smooth and recovered well.

The histopathological examination confirmed the diagnosis of laryngeal schwannoma with low proliferative activity. Upon follow-up within 6 months postoperation revealed no sign of tumor recurrence.

DISCUSSION

Schwannomas are benign tumors that originate from the Schwann cells of a nerve either peripheral, cranial, or autonomic. Within the head and neck area, parapharyngeal space is commonly influenced because it houses a

^{1,3}ORL Specialist, ²Associate Professor

¹Department of Otorhinolaryngology, Faculty of Medicine Universiti Sultan Zainal Abidin, Kuala Terengganu, Malaysia

²Department of Otorhinolaryngology, Hospital Canselor Tuanku Muhriz, Universiti Kebangsaan Malaysia Medical Center, Kuala Lumpur, Malaysia

³Department of Otorhinolaryngology, Universiti Putra Malaysia Serdang, Selangor, Malaysia

Corresponding Author: Salman Amiruddin, ORL Specialist Department of Otorhinolaryngology, Faculty of Medicine Universiti Sultan Zainal Abidin, Kuala Terengganu, Malaysia Phone: +60193654969, e-mail: drnamlas@gmail.com

few nerves, such as vagal, glossopharyngeal, hypoglossal, accessory nerve, and sympathetic chains. Neurogenic tumors of the larynx are uncommon and speak to less than 1.5% of all generous tumors. It could be a slow-growing encapsulated tumor showing by the 4th and 5th decades of life with female dominance. Be that as it may, it still can display at any age. Over 130 cases have been detailed in the literature, and the first case was depicted in the year 1925.¹

The superior laryngeal nerve internal branch is assumed to be the root of the pathology. Regularly, in any case, it is typically not recognized intraoperatively and likely to start from the smaller distal nerve strands within the submucosa of the larynx. The aryepiglottic fold was reported to be the commonest site to be involved.² Even a malignant change of laryngeal schwannoma is rare; it is important to differentiate a schwannoma from a neurofibroma because the latter has greater malignant potential and locally aggressive.

On laryngoscopic examination, the lesions would appear as a smooth submucosal lesion, which occupied the false vocal cord or aryepiglottic fold. The mass can obscure the view of the laryngeal inlet and cause a reduction in mobility of the vocal cord. All neurogenic tumors of the larynx are reported to involve the supraglottis area.² The CT scan and magnetic resonance imaging are crucial to determine the nature and extension of the mass. In most of the cases, the mass is well encapsulated, round or oval in shape, having similar attenuation with muscle, and often enhanced heterogeneously.³ Calcification due to degenerative change was reported in ancient schwannomas even when the occurrence was rare. However, the radiological examination cannot differentiate between schwannoma and neurofibromas due to similar findings.

Another differential diagnosis of the same presentation includes internal laryngocele and laryngeal cyst. The definitive diagnosis is obtained by histopathological examination. Three histological criteria for the diagnosis of schwannoma were described by Enger and Weiss: encapsulation, a presence of Antoni A and/or Antoni B stroma, and S-100 protein positivity. Antoni A presents a parallel arrangement of fibrocyte-like cell and Verocay bodies. Antoni B describes loosely arranged spindle Schwann cells with the presence of inflammation, microvacuolation, or intercellular substance with degeneration. However, neurofibromas are not capsulated and composed of a variety of cell types: elongated spindle Schwann cells intermingle with axons and collagen fibers.³

Surgery is the mainstay treatment for laryngeal schwannoma. In some cases, a tracheostomy may be

needed to secure the airway preoperatively. The approach for the surgery depends on the location and the size of the lesion. Endoscopic approach is the best approach in small lesion using a laser or microlaryngeal instrument. Larger tumors may require an external approach as mentioned in several literature using lateral thyrotomy, lateral pharyngotomy, or laryngofissure technique.⁴ Wide excision is necessary to prevent recurrence.

Wang et al⁵ reported a case of laryngeal schwannoma where transoral microlaryngoscopic excision without tracheostomy was used to excise the tumor from the aryepiglottic fold. Lo and Ho⁶ and Meriç et al⁷ reported cases of laryngeal schwannoma in which excision was done via lateral thyrotomy. Wang et al⁵ reported a case of schwannoma in arytenoids which were excised microscopically. Incomplete resection will lead to recurrence in several cases. Complete resolution of the vocal cord mobility was documented despite different surgical approaches.⁸

CONCLUSION

Neurogenic tumors of the larynx still have to be one of the differential determinations in case of laryngeal mass. Securing the airway is the most priority in any case of laryngeal mass. Histopathological examination is crucial to differentiate between schwannoma and neurofibromas. To prevent tumor recurrence, complete excision is the main objective of the surgery.

REFERENCES

1. Jones SR, Myers EN, Barnes L. Benign neoplasms of the larynx. *Otolaryngol Clin North Am* 1984 Feb;17(1):151-178.
2. Thomas RL. Non-epithelial tumors of the larynx. *J Laryngol Otol* 1979;93(11):1131-1141.
3. Lin J, Martel W. Cross-sectional imaging of peripheral nerve sheath tumors: characteristic signs on CT, MR imaging, and sonography. *Am J Roentgenol* 2001 Jan;176(1):75-82.
4. Woodruff JM, Kourea HP, Louis DN, Schethauer BW. Schwannoma. In: Kleihues P, Cavenee WK, editors. *WHO classification of tumours: pathology and genetics of tumours of nervous system*. 2nd ed. Lyon, France: IARC Press; 2000. pp. 164-166.
5. Wang B, Dong P, Shen B, Xu H, Zheng J. Laryngeal schwannoma excised under a microlaryngoscope without tracheostomy—a case report. *Exp Ther Med* 2014 Apr;7(4):1020-1022.
6. Lo S, Ho WK. Schwannoma of the larynx—an uncommon cause of vocal cord immobility. *Hong Kong Med J* 2004 Apr;10(2):131-133.
7. Meriç F, Arslan A, Cüreoğlu S, Nazaroğlu H. Schwannoma of the larynx: case report. *Eur Arch Otorhinolaryngol* 2000 Dec;257(10):555-557.
8. DeLozier HL. Intrinsic malignant schwannoma of the larynx. A case report. *Ann Otol Rhinol Laryngol* 1982 May-Jun;91 (3 Part 1):336-338.