

CASE REPORT

Non-communicating Rudimentary Horn Pregnancy— A Rare Clinical Scenario

¹Darpan Bansal, ²Parminder Kaur, ³Surat Kaur

ABSTRACT

Background: Unicornuate uterus with pregnancy in a rudimentary horn is a rare clinical entity with an incidence of 1 in 76000. Its diagnosis requires a high index of suspicion as it can be very easily missed during a routine ultrasound scan. Management involves laparoscopically or open resection of the rudimentary horn and ipsilateral fallopian tube.

Case report: We present a case of a 28-year old female with pain abdomen and history of intake of abortion pills twice and previous history of normal vaginal delivery. Initial ultrasound scans from remote centers were normal. After a thorough clinical examination, patient was again subjected to a final scan which revealed ectopic pregnancy. A definitive diagnosis of left rudimentary horn pregnancy was made during laparotomy and resection of a rudimentary horn with ipsilateral salpingo-oophorectomy was done.

Conclusion: Diagnosis of the rudimentary horn is a challenge. Early diagnosis is necessary to decrease maternal morbidity and mortality.

Keywords: Ectopic pregnancy, Laparotomy, Rudimentary horn, Suspicion index, Unicornuate uterus

How to cite this article: Bansal D, Kaur P, Kaur S. Non-communicating Rudimentary Horn Pregnancy—A Rare Clinical Scenario. *Curr Trends Diagn Treat* 2018;2(1):41-43.

Source of support: Nil

Conflict of interest: None

INTRODUCTION

The incidence of mullerian duct anomalies is around 0.5 to 3.2%.¹ non-development or rudimentary development of a single mullerian duct results in a unicornuate uterus, prevalence accounting for 2.4 to 1.37% of mullerian duct anomalies.² The prevalence of unicornuate uterus with rudimentary horn infertile

women is 1 in 100,000.³ The incidence of rudimentary horn pregnancy is 1 in 76000 pregnancies.⁴ Conception in a non communicating rudimentary horn is postulated to occur from the transperitoneal migration of the spermatozoa from the contralateral fallopian tube or the fertilized ovum from the ipsilateral or contralateral fallopian tube. One needs a high index of suspicion to diagnose rudimentary horn pregnancy as it can be easily missed during the routine ultrasound scan in antenatal followup. Though sporadic cases of alive infant delivery are reported, most rudimentary horn pregnancies experience uterine rupture commonly around 10 to 15 weeks of gestation, which is a life-threatening condition.⁵ Here, we report a case of 15 weeks unruptured non communicating rudimentary horn pregnancy which was initially missed during ultrasound scans and misdiagnosed as routine pain abdomen patient and was referred to a general surgeon.

CASE REPORT

A 28-year-old woman came to the surgery out patient department (OPD) with a history of pain abdomen since one month. She also gave a history of 3 months amenorrhea and oral intake of hormonal pills twice but failed to have menses, for which she consulted various gynecologists. She had a previous normal delivery. All her ultrasound scans were normal. As her pain was not subsiding and scans were normal, she was referred to a surgeon. On per abdomen examination, a lump was palpable in left iliac fossa. She was again subjected to ultrasound examination which finally revealed 15 weeks live ectopic pregnancy in a left rudimentary horn. Gynecologist opinion was sorted out. The patient was counseled regarding the probability of rupture uterus, mortality and informed consent for abdominal exploration was obtained. The abdomen was opened through a midline incision under spinal anesthesia, and pregnancy in the non communicating left rudimentary horn of unicornuate uterus was confirmed (Fig. 1). The surgical technique included excision of the left rudimentary horn with ipsilateral salpingo-oophorectomy. A fetus of approx 7 cm was found inside the sac (Fig. 2). The patient remained asymptomatic in the postoperative period and was discharged on day five.

¹Associate Professor ^{2,3}Consultant

¹Department of General Surgery, Sri Guru Ram Das Institute of Medical Sciences and Research, Amritsar, Punjab, India

^{2,3}Department of Gynaecologist, Bhatia Nursing Home, Amritsar, Punjab, India

Corresponding Author: Darpan Bansal, Associate Professor, Department of General Surgery, Sri Guru Ram Das Institute of Medical Sciences and Research, Amritsar, Punjab, India, e-mail: bhatiadarpan27@gmail.com

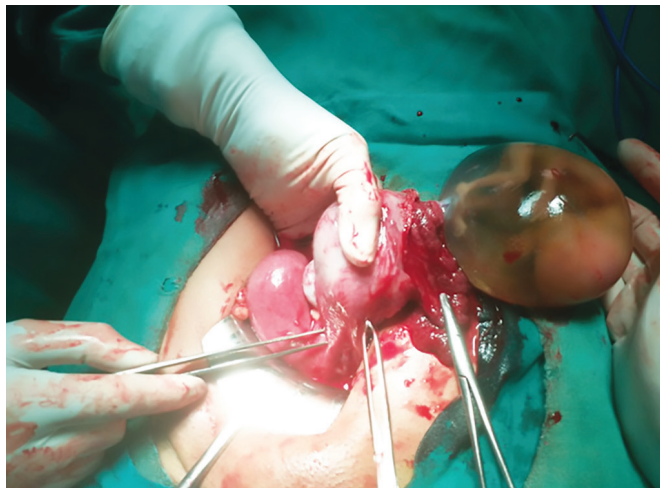


Fig. 1: Intraoperative finding showing rudimentary horn with a live fetus

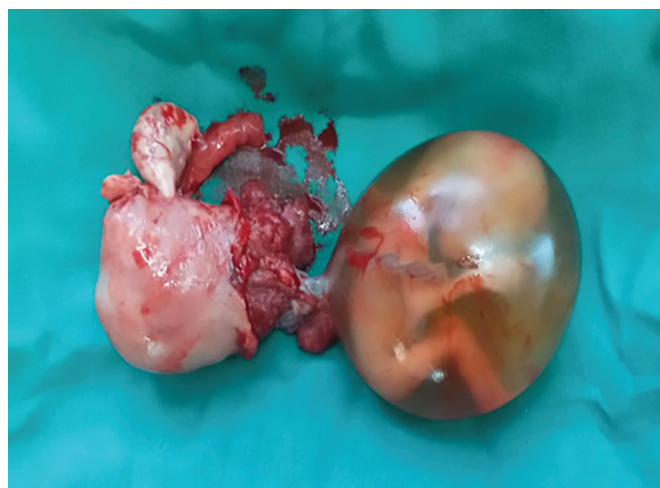

Fig. 2: Resected specimen showing rudimentary horn with sac with the fetus and ipsilateral tube and ovary

DISCUSSION

The prevalence of unicornuate uterus is 0.1% in general population.⁶ As per American Fertility Society, it is a Type 2 mullerian anomaly. A unicornuate uterus alone is Type 2A while with rudimentary horn it is Type 2B.⁷ More than 90% rudimentary horns are noncommunicating. The urinary tract anomalies are associated with a unicornuate uterus to the tune of 36% and should always be searched for.⁸

Mauriceau⁹ described the first case of the rudimentary horn during pregnancy in 1669. Since then, many cases were described in the literature with variable timing of rupture ranging from 5 to 35 weeks, depending on the ability of rudimentary uterine horn musculature to hypertrophy and dilate to accommodate the fetus. Diagnosis of the asymptomatic unicornuate uterus with a rudimentary horn is a challenge, due to low prevalence and lack of awareness and suspicion among clinicians and radiologists. Precious time may be lost due to misdiagnosis or delay in diagnosis, and general

condition of the patient may worsen. The misdiagnosis was evident in the present case because of unfamiliarity, but to the patient's luck, it was managed timely without any morbidity.

Tsafir et al.¹⁰ suggest ultrasound criteria for early diagnosis of rudimentary horn pregnancy: (a) pseudo pattern of an asymmetrical bicornuate uterus, (b) absent visual continuity between the cervical canal and the lumen of the pregnant horn, (c) presence of myometrial tissue surrounding the gestation sac. MRI is the most useful complementary investigation. However, the definitive diagnosis is made either by laparoscopy or laparotomy.

It is important to emphasize that though the pregnancy lasts longer than tubal pregnancy because of the variable musculature of the horn, the risk of rupture of a pregnant rudimentary uterine horn and placenta accreta in 2nd trimester is very high. In general, 50% cases rupture in 2nd trimester while 30% go to term with a 0 to 13% salvage rate.⁵ If an early diagnosis is made, excision of the rudimentary horn with ipsilateral salpingectomy, with or without previous medical treatment is recommended.¹¹ If the diagnosis is delayed and the patient is asymptomatic, the risk and a meager possibility of term pregnancy with live birth should be fully explained.⁵ When uterine rupture occurs, urgent intervention with excision of rudimentary horn and ipsilateral salpingectomy is mandatory.

In conclusion, our case report is to familiarise surgeons with this rare but potentially lethal presentation of rudimentary horn pregnancy that may be misdiagnosed prior to surgery.

REFERENCES

1. Nahum GG. Uterine anomalies. How common are they, and what is their distribution among subtypes? *The Journal of Reproductive Medicine*. 1998;43:877-887.
2. Engmann L, Schmidt D, Nulsen J, Maier D, Benadiva C. An unusual anatomic variation of a unicornuate uterus with normal external uterine morphology. *Fertil Steril* 2004;82:950-953.
3. Handa Y, Hoshi N, Wada S, Kudo M, Tsuda et al. Tubal pregnancy in a unicornuate uterus with rudimentary horn: a case report. *Fertil Steril* 1999;72:354-356.
4. Johansen K. Pregnancy in a rudimentary horn. *Obstet Gynecol* 1983;61:565-567.
5. Nahum GG. Rudimentary uterine horn pregnancy: the 20th century worldwide experience of 588 cases. *J Reprod Med* 2002;47:151-163.
6. Caserta D, Mallozi M, Melodelsi C, Bianchi P, Moscarini M. Pregnancy in a unicornuate uterus: a case report. *J Med Case Rep* 2014;8:130.
7. American Fertility Society. Classification of mullerian anomalies. *Fertil Steril* 1988;49:952.
8. Jayasinghe Y, Rane A, Stalewski H, Grover S. The presentation and early diagnosis of the rudimentary uterine horn. *Obstet Gynecol* 2005;105:1456-1467.

9. Mauriceau F. Traite des malades des femmes grosses. In: Mauriceau F, ed. A Book. 1st ed. Paris, France:Compaigne des libraries; 1721.
10. Tsafir A, Rojansky N, Sela HY et al. Rudimentary horn pregnancy: first trimester pre rupture sonographic diagnosis and confirmation by magnetic resonance imaging. *J Ultrasound Med* 2005;24:219-223.
11. Shin JW, Kim HJ. Case of live birth in a non communicating rudimentary horn pregnancy. *Journal of Obstetrics and Gynecology Research*. 2005;31:329-331.